

1707

QUESTIONS



FOR A
CHANCE
TO LIVE
IN **LONDON!**

1700 files explained by Dr. Khalid Saifullah (Question 1 to question 1707)

Older Corrections: [1. Q. 332; 2. Q. 568; 3. Q. 650; 4. Q. 704; 5. Q. 735; 6. Q. 899; 7. Q. 1016; 8. Q. 1170; 9. Q. 1174; 10. Q. 1175; 11. Q. 1306; 12. Q. 1476; 13. Q. 1517; 14. Q. 1525; 15. Q. 1570; 16. Q. 1635;]

New corrections: [1. Q. 214; 2. Q. 291; 3. Q. 650; 4. Q. 911; 5. Q. 1016; 6. Q. 1083 7. 1293; 8. Q. 1481;

1. A 65yo man presents with painless hematuria, IVU is normal, prostate is mildly enlarged with mild frequency. What is the most appropriate next step?

- a. US Abdomen
- b. Flexible cystoscopy
- c. MRI
- d. Nuclear imaging
- e. PSA

Ans. The key is B. Flexible cystoscopy. [Painless hematuria in an elderly (here 65 years old man) indicates carcinoma bladder for which flexible cystoscopy is done.

Here BEP is not advanced to cause hemorrhage. There is mild enlargement of prostate and mild symptoms of prostration and hemorrhage is unlikely at this initial stage of BEP which makes Bladder cancer as the likely cause of painless hematuria.

It is also less likely to be prostate cancer as symptoms of prostration are mild (indicates disease is not advanced). Moreover bleeding in cancer prostate is less common].

2. A 74yo smoker presented to his GP with cough and SOB. Exam revealed pigmentation of the oral mucosa and also over the palms and soles. Tests show that he is diabetic and hypokalemic. What is the most probable dx?

- a. Pseudocushing syndrome
- b. Conns disease
- c. Ectopic ACTH
- d. Cushing's disease
- e. Hypothyroidism

Ans. The key is C. Ectopic ACTH. [The patient is smoker and probably developed squamous cell lung cancer which is working as a tumour producing ectopic ACTH causing pigmentation. Resulting raised cortisol is leading to diabetes and hypokalemia (though small cell carcinoma is usual cause but squamous cell carcinoma can produce ectopic ACTH as paraneoplastic syndrome also)].

3. A 44yo woman has lost weight over 12 months. She has also noticed episodes where her heart beats rapidly and strongly. She has a regular pulse rate of 90bpm. Her ECG shows sinus rhythm. What is the most appropriate inv to be done?

- a. Thyroid antibodies
- b. TFT
- c. ECG
- d. Echocardiogram
- e. Plasma glucose

Ans. The key is B. TFT. [The patient has paroxysmal atrial fibrillation That is why there is no arrhythmia in between attacks. From the given option TFT is the appropriate test as thyrotoxicosis is a leading cause of paroxysmal atrial fibrillation and this ladies weight loss also makes thyrotoxicosis as the probable cause here].

4. A 79yo anorexic male complains of thirst and fatigue. He has symptoms of frequency, urgency and terminal dribbling. His urea and creatinine levels are high. His serum calcium is 1.9 and he is anemic. His BP is 165/95 mmHg. What is the most probable dx?

- a. BPH
- b. Prostate carcinoma
- c. Chronic pyelonephritis
- d. Benign nephrosclerosis

Ans. The key is B. Prostate Carcinoma.

Explanation for Question no. 4:

First to say in this case (almost all features goes in favour of prostatic carcinoma like- frequency, urgency and terminal dribbling are features of prostatism; Age, anorexia and anaemia are constitutional features of carcinoma prostate and it would be accurate presentation if it was hypercalcaemia. But given calcium level is of hypocalcaemic level and it is the main cause of discrepancy to this question). Renal failure from ureteral obstruction in carcinoma prostate is a common presentation. Thirst is a feature of hypercalcaemia (here may be erroneously calcium level is given in hypocalcaemic level ; probably a bad recall). Prostate biopsy is the confirmatory diagnosis and others like PSA is suggestive.

***There are some suggestion that Renal Failure may be the cause of hypocalcemia.

5. A 64yo man has recently suffered from an MI and is on aspirin, atorvastatin and ramipril. He has been having trouble sleeping and has been losing weight for the past 4 months. He doesn't feel like doing anything he used to enjoy and has stopped socializing. He says he gets tired easily and can't concentrate on anything. What is the most appropriate tx?

- a. Lofepramine
- b. Dosulepin
- c. Citalopram
- d. Fluoxetine
- e. Phenelzine

Ans. The key is C. Citalopram. [Among SSRIs Sertraline is the drug of choice for ischemic heart disease. Next choice is citalopram (as it is often related to torsades de pointes it is not 1st choice). If SSRI cannot be used Mirtazapine is recommended as next antidepressant].

6. A 67yo man after a stroke, presents with left sided ptosis and constricted pupil. He also has loss of pain and temp on the right side of his body and left side of his face. Which part of the brain is most likely affected?

- a. Frontal cortex
- b. Cerebellum
- c. Pons
- d. Medulla
- e. Parietal cortex

Ans. The key is D. Medulla. [The name of the condition is "Lateral medullary syndrome" [ipsilateral Horner syndrome and contralateral loss of pain and temperature sense].

7. A 60yo man presents with dysphagia and pain on swallowing both solids and liquids. A barium meal shows gross dilatation of the esophagus with a smooth narrowing at the lower end of the esophagus. What is the SINGLE most likely cause of dysphagia?

- a. Achalasia
- b. Myasthenia gravis
- c. Esophageal carcinoma
- d. Esophageal web
- e. Systemic sclerosis

Ans. The key is A. Achalasia. [Dysphagia for both solid and liquid or prominently liquid suggest achalasia where dysphagia to solid suggest stricture. Also gross dilatation of oesophagus with smooth narrowing at lower end is seen in achalasia. In achalasia dysphagia is usually described as progressive].

8. A man undergoes a pneumonectomy. After surgery, invs show hyponatremia. What could be the cause of the biochemical change?

- a. Removal of hormonally active tumor
- b. Excess dextrose
- c. Excess colloid
- d. Excessive K⁺
- e. Hemodilution

Ans. The key is A. Removal of harmonically active tumour. [Ectopic ACTH secreting tumour causes hyponatremia and body's homeostatic mechanism try to lower the level of high sodium and do a lesser degree though sodium remains in hyponatremic level or even it may be normal (this question does not mention any preoperative hyponatremia). Removal of that tumour results in negative sodium balance for time being which results hyponatremia while gradually it tends to rise again to normal level].

9. A pregnant lady came with pain in her calf muscle with local rise in temp to the antenatal clinic. What tx should be started?

- a. Aspirin
- b. LMWH
- c. Paracetamol
- d. Cocodamol
- e. Aspirin and heparin

Ans. The key is B. LMWH. [Injections with low molecular weight heparin (LMWH) are usually used to treat pregnant women with DVT. LMWH is an anticoagulant, which means it prevents the blood clot getting bigger. It does not affect the developing baby (Ref: nhs.uk)].

10. A 53yo female presents with an acute painful hot knee joint. She is a known case of RA. On examination, the knee is red, tender and swollen. The hamstring muscles are in spasm. Her temp is 38.5C and BP is 120/80mmHg. What is the SINGLE best next inv?

- a. Joint aspiration for cytology and culture and sensitivity
- b. Joint aspiration for positive birefringent crystals
- c. Joint aspiration for negative birefringent crystals
- d. Blood culture
- e. Serum uric acid

Ans. The likely key is A. Joint aspiration for cytology and culture and sensitivity. [Case of septic arthritis. Any chronically arthritic joint is predisposed to infection. Moreover chronic use of steroid in RA, arthritis is one of the important predisposing factor. In this age group likely organism is Staphylococcus. In younger age group Neisseria gonorrhea is more common].

11. An 80yo man presented with pain in his lower back and hip. He also complains of waking up in the night to go to the washroom and has urgency as well as dribbling. What is the most likely dx?

- a. BPH
- b. Prostatitis
- c. UTI
- d. Prostate carcinoma
- e. Bladder carcinoma

Ans. The key is D. Prostate carcinoma. [Age, nocturia, urgency and dribbling points towards prostate pathology. Pain of lower back and hip points towards bony metastases from prostate cancer. Blood test for PSA; Prostate biopsy; MRI (if initial biopsy is negative, to decide repeat biopsy).

Treatment options: 1. Active treatment [i) radical prostatectomy ii) radical radiotherapy iii) hormone therapy iv) brachytherapy v) pelvic radiotherapy vi) orchidectomy

- 2. Active surveillance
- 3. Watchful waiting
- t4. Palliative care (Source: NICE)].

12. An 18yo female has peri-orbital blisters. Some of them are crust-ed, others secreting pinkish fluid. What is the most likely dx?

- a. Shingles
- b. Chicken pox
- c. Varicella
- d. Rubella
- e. Measles

Ans. The key is A. Shingles. [Here ophthalmic division of trigeminal nerve is involved. Typically shingles are unilateral].

13. A 29yo lady who is a bank manager is referred by the GP to the medical OPC due to a long hx of tiredness and pain in the joints. An autoimmune screen result showed smooth muscle antibodies positive. What is the most appropriate next inv?

- a. ECG
- b. TFT
- c. LFT
- d. Serum glucose
- e. Jejunal biopsy

Ans. The key is C. LFT. [A case of autoimmune hepatitis. Autoimmune hepatitis is an uncommon cause of chronic hepatitis which if un-

treated can lead to cirrhosis. However with treatment outlook is very good. Smooth muscle antibody is positive in autoimmune hepatitis. Definitive investigation is liver biopsy. Treated with steroid [start with high dose prednisolone]. Azathioprine is commonly added with steroid to reduce its dose as steroid has more side effects than azathioprine].

14. A 5yo with recurrent chest pain, finger clubbing with offensive stool. Choose the single most likely inv?

- a. Endomysial/Alpha gladin antibody
- b. Sweat test
- c. Barium meal
- d. ECG
- e. Glucose tolerance test

Ans. The key is B. Sweat test. [Recurrent chest pain from frequent lung infections including pneumonia or bronchitis. "Clubbing" of the fingers is a classic feature of Cystic Fibrosis, although not present in many patients. The digestive enzymes are not being produced, food is not adequately digested (malabsorption) and excess fat and protein is lost in the stools, making them bulky, oily, smelly and difficult to flush away].

15. A clinical picture of breast cancer originated from the mammary duct. Biopsy was done and there were neoplastic cells found. Choose the histological picture of the cancer.

- a. Neoplastic cells are arranged in small clusters occupying a space between collagen bundles (Scirrhous carcinoma)
- b. Spindle cell neoplasms with margins, which infiltrate adjacent structure, fat invaded (Breast sarcoma)
- c. Small cells with round nucleus and scant indistinct cytoplasm (Lobular carcinoma)

Ans. The key is C. Small cells with round nucleus and scant indistinct cytoplasm (Lobular carcinoma)

16. A 22yo man has a reduced conscious level and a fixed dilated pupil after being involved in a MVC. Choose the single most appropriate option?

- a. Facial nerve
- b. Oculomotor nerve
- c. Olfactory nerve
- d. Optic nerve
- e. Trigeminal nerve

Ans. The key is B. Oculomotor nerve. [3rd nerve damage can cause fixed dilated pupil].

17. A man with suspected active TB wants to be treated at home. What should be done to prevent the spread of disease?

- a. Immediate start of the tx with Anti-TB drugs
- b. All family members should be immediately vaccinated with BCG vaccine
- c. Patient should be isolated in a negative pressure chamber in his house
- d. Universal prevention application protocol

Ans. The key is D. Universal prevention application protocol.

18. A 7yo child is brought to the ED with a 1 day hx of being listless. On examination, the child is drowsy with an extensive non-blanching rash. What advice would you give the parents?

- a. All family members need antibiotic therapy
- b. Only the mother should be given rifampicin prophylaxis
- c. All family members need isolation
- d. All family members should be given rifampicin prophylaxis

Ans. The key is D. All family members should be given rifampicin prophylaxis. [Meningococcal disease. Diagnosis is done with blood or CSF PCR. Initial prehospital management: Benzyl penicillin or cefotaxime].

19. A 47yo man has a temp of 39C and is delirious. He has developed blisters mainly on his trunk, which appeared a few hours ago. He is well and not on any medications. He last travelled 5 months ago to Italy. Which of the following is the most likely dx?

- a. Shingles
- b. Chicken pox
- c. Pemphigoid
- d. Bullous pemphigus

Ans. The key is B. Chicken pox. [Centripetal distribution of blisters favours chickenpox. Adults more commonly develop a more generalized brain inflammation ("encephalitis") whose symptoms may include delirium and seizures. Incubation period of chicken-pox is 10-21 days. So this travel history is not significant].

20. A 64yo pt has been having freq episodes of secretory diarrhea, which is extremely watery, with large amounts of mucus. A dx of villous adenoma was made after endoscopy. What electrolyte abnormality is most likely in this pt?

- a. Hyperkalemia
- b. Hypernatremia
- c. Hyponatremia
- d. Hypokalemia

Ans. Key not given. Correct key is both C and D! [Villous adenoma can cause both hyponatremia and hypokalemia].

21. A pt with an acute gout attack came to the ED. What drug should be given to relieve symptoms?

- a. NSAIDs
- b. Allopurinol
- c. Ibuprofen

Ans. The key is A. NSAIDs. [Oral NSAIDs commenced immediately and continue for 1 – 2 weeks; Colchicine can be effective alternative but is slower to work than NSAIDs. Intra articular corticosteroids are highly effective in acute gouty monoarthritis.

22. A pt was lying down on the operating table in a position with his arms hanging down for 3 hours. Soon after he woke up, he complains of numbness and weakness in that hand and has limited wrist movement/wrist drop and sensory loss over dorsum of that hand, weakness of extension of the fingers and loss of sensation at the web of the thumb. What structure is likely to be damaged?

- a. Radial nerve
- b. Median nerve
- c. Ulnar nerve
- d. Axillary nerve
- e. Suprascapular nerve

Ans. The key is A. Radial nerve. [Here arm hanging down compressing the radial nerve at the spiral groove is the cause of given scenario].

23. A pt who was previously on 120mg slow release oral morphine has had his dose increased to 200mg. He is still in significant pain. He complains of drowsiness and constipation. What is the next step in the management?

- a. Increase slow release morphine dose
- b. Fentanyl patch
- c. Replace morphine with oral hydromorphone
- d. Replace morphine with oxycodone
- e. Subcutaneous morphine

Ans. The key is D. Replace morphine with oxycodone.

24. A 40yo woman notices increasing lower abdominal distention with little/no pain. On examination, a lobulated cystic mass is felt and it seems to be arising from the pelvis. What is the most appropriate inv?

- a. CA 125
- b. CA 153
- c. CA 199
- d. CEA
- e. AFP

Ans. The key is A. CA 125. [Ovarian ca is the likely diagnosis for which tumour marker is CA 125].

25. A resident of a nursing home presented with rashes in his finger webs and also on his abdomen, with complaints of itching which is severe at night. He was dx with scabies. What the best tx for his condition?

- a. 0.5% permethrin
- b. Doxycycline
- c. 5% permethrin
- d. Reassure
- e. Acyclovir

Ans. The key is C. 5% permethrin. [Scabies outbreaks in nursing homes and cases of crusted scabies may require combination therapy consisting of topical application of permethrin and 2 oral doses of ivermectin at 200 mcg/kg (administered 1 wk apart)].

26. A 34yo alcoholic is found passed out in front of a local pub. The ambulance crew informs you that he was sweating when they found him and there were cans of cider lying empty around him. What is the initial stage of inv?

- a. Capillary blood sugar
- b. CT head
- c. MRI head
- d. ABG
- e. MCV

Ans. The key is A. Capillary blood sugar. [Alcohol induced hypoglycemia can present as this case].

27. A young boy fell on his outstretched hand and has presented with pain around the elbow. He has absent radial pulse on the affected hand. What is the most likely dx?

- a. Dislocated elbow
- b. Angulated supracondylar fx
- c. Undisplaced fx of radial head
- d. Posterior dislocation of shoulder

Ans. The key is B. Angulated supracondylar fx. [Damage or occlusion of the brachial artery is the cause of absent radial pulse. Often closed reduction results in restoration of normal anatomy and correction of occlusion of brachial artery and establishes circulation again but in few instances open reduction is required to fix the occluded artery].

28. A 65yo woman presented with transient arm and leg weakness as well as a sudden loss of vision in the left eye. Her symptoms resolved within the next couple of hours. What is the most appropriate next inv?

- a. CT brain
- b. Echo
- c. Doppler USG
- d. Arteriography
- e. 24h ECG

Ans. The key is c. [A case of TIA. Probable cause carotid artery atherosclerosis].

29. A man complains of loss of sensation in his little and ring finger. Which nerve is most likely to be involved?

- a. Median nerve
- b. Ulnar nerve
- c. Radial nerve
- d. Long thoracic nerve
- e. Axillary nerve

Ans. The key is B. Ulnar nerve. [Compression of ulnar nerve at the elbow, **30. known as cubital tunnel syndrome, causes numbness in the 5th (pinkie) finger, along the half (lengthwise) of the 4th (ring) finger closest to the 5th finger, and the back half of the hand over the 5th finger**]. **30. A young man complains of double vision on seeing to the right. Which nerve is most likely to be involved?**

- a. Left abducens
- b. Right abducens
- c. Left trochlear
- d. Right trochlear
- e. Right oculomotor

Ans. The key is B. Right abducens. [Diplopia on seeing to right

indicates right lateral rectus palsy which is supplied by right abducent nerve].

31. A 45yo man keeps having intrusive thoughts about having dirt under the bed. He can't keep himself from thinking about these thoughts. If he tries to resist, he starts having palpitations. What is the most likely dx?

- a. OC personality
- b. OCD
- c. Schizophrenia
- d. Panic disorder
- e. Phobia

Ans. The key is B. OCD. [Here patient's thoughts are obsession and though no compulsive act is described (like repeated cleansing of dirt) but his nature of thought like inability to resist the thinking or getting palpitation on trying to avoid thinking can be regarded as compulsion of thought. CBT 1st line. SSRIs].

32. A 33yo man presents with an itchy scaly annular rash on his thigh after a walk in the park. Which of the following drugs will treat his condition?

- a. Erythromycin
- b. Doxycycline
- c. Penicillin
- d. Amoxicillin

Ans. The key is B. Doxycycline. [Itchy scaly annular rash after a walk in the park indicates erythema migrans caused by the spirochete *Borrelia burgdorferi* transmitted by bite of pinhead-sized ixodes ticks leading to Lyme disease].

33. A pt with cerebral mets has polyuria and polydipsia. What part of the brain would be affected?

- a. Cerebral cortex
- b. Cerebellum
- c. Diencephalon
- d. Pons
- e. Medulla

Ans. The key is C. Diencephalon. [Diencephalon is the caudal (posterior) part of the forebrain, containing the epithalamus, thalamus, hypothalamus, and ventral thalamus and the third ventricle. Hypothalamus produces ADH and lesion of diencephalon (hypothalamus) may produce cranial diabetes insipidus.

34. A 32yo man presented with painless hematuria. He is hypertensive but the rest of the exam is unremarkable. What is the most likely dx?

- a. Polycystic kidneys
- b. Ca bladder
- c. Ca prostate
- d. TTP
- e. HUS

Ans. The key is A. Polycystic kidneys. [Painless haematuria at a younger age with hypertension is suggestive of polycystic kidney disease. Renal ultrasound is used to diagnose the condition].

35. A 45yo female complains of pain in the inner side of her right thigh. She was dx with benign ovarian mass on the right. Which nerve is responsible for this pain?

- a. Femoral nerve
- b. Obturator nerve
- c. Iliohypogastric nerve
- d. Ovarian branch of splanchnic nerve
- e. Pudendal nerve

Ans. The key is B. Obturator nerve. [The Obturator nerve is responsible for the sensory innervation of the skin of the medial aspect of the thigh].

36. A 37yo lady strongly believes that a famous politician has been sending her flowers every day and is in love with her. However, this is not the case. What is the most likely dx?

- a. Erotomania
- b. Pyromania
- c. Kleptomania
- d. Trichotillomania
- e. Grandiosity

Ans. 1. The key is A. Erotomania. [Erotomania is a type of delusion in which the affected person believes that another person, usually a stranger, high-status or famous person, is in love with them].

Pyromania is an impulse control disorder in which individuals repeatedly fail to resist impulses to deliberately start fires, in order to relieve tension or for instant gratification.

Kleptomania is the inability to refrain from the urge to steal items.

Trichotillomania is an impulse disorder characterized by the compulsive urge to pull out one's hair, leading to noticeable hair loss and balding.

Grandiosity refers to an unrealistic sense of superiority.

37. A 3yo child has been brought with facial lacerations. On examination he has some cuts over his right cheek and under the eye. The GCS on initial evaluation is 15. What is the appropriate next inv?

- a. Skull XR
- b. Facial XR
- c. CT scan
- d. MRI
- e. Observation

Ans. The key is B. Facial X-ray. [Normal GCS makes intracranial lesion less likely. As there is facial injury to exclude any facial bone fracture we can do facial X-ray].

38. A 73yo woman has lymphadenopathy and splenomegaly. She feels well but has had recurrent chest infections recently. Choose the single most likely blood film findings?

- a. Atypical lymphocytes
- b. Excess of mature lymphocytes
- c. Plasma cells
- d. Multiple immature granulocytes with blast cells
- e. Numerous blast cells

Ans. The key is B. Excess of mature lymphocytes. [Dx is CLL. Age of patient (usually above 50 yrs), lymphadenopathy and splenomegaly, appearance of lymphocytes (mature lymphocytes – but functionally not normal). Repeated chest infection points towards abnormal function of lymphocytes against infection].

39. A lady presents with itching around the breast and greenish foul smelling discharge from the nipple. She had a similar episode before. What is the most likely dx?

- a. Duct papilloma
- b. Duct ectasia
- c. Breast abscess
- d. Periductal mastitis
- e. Mammary duct fistula

Ans. The key is B. Duct ectasia. [Duct ectasia of the breast or mammary duct ectasia or plasma cell mastitis is a condition in which the lactiferous duct becomes blocked or clogged. This is the most common cause of greenish discharge. Mammary duct ectasia can mimic breast cancer. It is a disorder of peri- or post-menopausal age].

40. A young male whose sclera was noted to be yellow by his colleagues has a hx of taking OTC drugs for some pain. Tests showed raised bilirubin, ALT and AST normal. The provocation test with IV nicotinic acid is positive and produces further rise in the serum bilirubin levels. What is the most likely dx?

- a. Acute hepatitis
- b. Drug hypersensitivity
- c. Gilberts syndrome
- d. Acute pancreatitis

Ans. The key is C. Gilbert's syndrome. [Only bilirubin is increased but not the liver enzymes. Also positive nicotinic acid provocation test is in its favour].

41. A 24yo biker has been rescued after being trapped under rocks for almost 12h. He complains of reddish brown urine. His creatinine is 350umol/L and his urea is 15mmol/L. What is the most imp step in the management of this patient?

- a. Dialysis
- b. IV NS
- c. IV dextrose
- d. IV KCl
- e. Pain relief

Ans. Key is B. IV NS. [It is a case of rhabdomyolysis which is initially treated with IV NS].

42. A 74yo man who has been a smoker since he was 20 has recently been dx with SCLC. What serum electrolyte picture will confirm the presence of SIADH?

- a. High serum Na, low serum osmolarity, high urine osmolarity
- b. Low serum Na, low serum osmolarity, high urine osmolarity
- c. Low serum Na, high serum osmolarity, high urine osmolarity
- d. High serum Na, low serum osmolarity, low urine osmolarity
- e. High serum Na, high serum osmolarity, low urine osmolarity

Ans. The key is B. Low serum Na, low serum osmolarity, high urine osmolarity.

43. A man brought into the ED after being stabbed in the chest. Chest is bilaterally clear with muffled heart sounds. BP is 60/nil. Pulse is 120bpm. JVP raised. What is the most likely dx?

- a. Pulmonary embolism
- b. Cardiac tamponade
- c. Pericardial effusion
- d. Hemothorax
- e. Pneumothorax

Ans. The key is B. Cardiac tamponade. [Chest is clear, so there is no pneumothorax or pleural effusion. Muffled heart sound is due to fluid in pericardial space, low BP from reduced chamber expansion due to pericardial fluid's pressure and restricted right heart expansion causes raised JVP].

44. A 50yo pt is admitted for elective herniorrhaphy. Which of the following options will lead to a postponement of the operation?

- a. SBP 110mmHg
- b. MI 2 months ago
- c. Hgb 12g/dl
- d. Pain around hernia
- e. Abdominal distention

Ans. The key is B. MI 2 months ago. [After MI elective surgery should not be done before 6 months post MI, as operation in earlier than this time has significant increase in mortality].

45. A 32yo woman of 39wks gestation attends the antenatal day unit feeling very unwell with sudden onset of epigastric pain associated with nausea and vomiting. Her temp is 36.7C. Exam: she is found to have RUQ tenderness. Her blood results show mild anemia, low platelets, elevated liver enzymes and hemolysis. What is the most likely dx?

- a. Acute fatty liver of pregnancy
- b. Acute pyelonephritis
- c. Cholecystitis
- d. HELLP syndrome
- e. Acute hepatitis

Ans. The key is D. HELLP syndrome. [HELLP syndrome is a life-threatening liver disorder thought to be a type of severe pre-eclampsia. It is characterized by Hemolysis (destruction of red blood cells), Elevated Liver enzymes (which indicate liver damage), and Low Platelet count. HELLP is usually related to preeclampsia. The main treatment is to deliver the baby as soon as possible [as early as after 34 weeks if multisystem disease is present].

46. A woman comes with an ulcerated lesion 3 cm in the labia majorum. What is the lymphatic drainage of this area?

- a. External iliac
- b. Superficial inguinal LN
- c. Para-aortic
- d. Iliac
- e. Aortic

Ans. Key is B. Superficial inguinal LN.

47. A man post-cholecystectomy presented with jaundice, fever and dark urine. What is the most diagnostic inv?

- a. ERCP
- b. USG Abdomen
- c. CT Scan
- d. MRCP
- e. MRI

Ans. The key is A. ERCP [Post operative US will not give good results. We shall not go for ercp first as it has complications like injury and pancreatitis. Acceptable options are CT, MRI and MRCP among which most appropriate is MRCP! But as the Question wants most diagnostic it is ERCP (though not practical)!!! The diagnosis here is choledolithiasis with cholangitis].

48. A 79yo stumbled and sustained a minor head injury 2 weeks ago. He has become increasingly confused, drowsy and unsteady. He has a GCS of 13. He takes warfarin for Afib. What is the most likely dx?

- a. Extradural hemorrhage
- b. Cerebellar hemorrhage
- c. Epidural hemorrhage
- d. Subdural hemorrhage
- e. Subarachnoid hemorrhage

Ans. 1. The key is D. Subdural hematoma. [In elderly head injury usually leads to subdural hematoma even if head injury is minor or trivial and extradural hematoma in elderly is extremely uncommon even in more severe head injury. Management: 1st line: Evacuation by burr hole craniotomy. 2nd line: Craniotomy if the clot is organized. Up to 3 weeks burrhole may be possible but longer than this clot is mostly organized and Flap craniotomy is usually required].

49. A 25yo female complains of intermittent pain in her fingers. She describes episodes of numbness and burning of the fingers. She wears gloves whenever she leaves the house. What is the most probable dx?

- a. Kawasaki disease
- b. Takayasu arteritis
- c. Buerger's disease
- d. Embolism
- e. Raynaud's phenomenon

Ans. The key is E. Raynaud's phenomenon. [Intermittent nature points towards some triggers and wearing of gloves during going out indicates cold weather. Also female sex makes the diagnosis of Raynaud's phenomenon more likely].

50. A 22yo lady has been unwell for some time. She came to the hospital with complaints of fever and painful vesicles in her left ear. What is the most probable dx?

- a. Acne
- b. Herpes zoster
- c. Chicken pox
- d. Insect bite
- e. Cellulitis

Ans. The key is B. Herpes Zoster. [This is a case of Herpes zoster oticus and if facial nerve is also involved then it is called Ramsay Hunt syndrome].

51. A 5yo girl had earache and some yellowish foul smelling discharge, perforation at the attic and conductive hearing loss. She has no past hx of any ear infections. What is the most appropriate dx?

- a. Acute OM
- b. OM with effusion
- c. Acquired cholesteatoma
- d. Congenital cholesteatoma
- e. Otitis externa

Ans. The key is c. Acquired cholesteatoma. [Acquired cholesteatomas develop as a result of chronic middle ear infection and are usually associated with perforation of the tympanic membrane at the attic (mass is seen in attic with perforation at pars flaccida- in contrast to medial to tympanic membrane which is in congenital). Clinical presentation usually consists of conductive hearing loss, often with purulent discharge from the ear].

In congenital:

- mass medial to the tympanic membrane

- normal tympanic membrane
- no previous history of ear discharge, perforation or ear surgery.

[discrepancy like no previous infection is the only point in favour of congenital here and may be due to a bad recall!!!]

52. A female with T1DM would like to know about a deficiency of vitamins in pregnancy that can be harmful. A deficiency of which vitamin can lead to teratogenic effects in the child?

- a. Folic acid
- b. Vit B12
- c. Thiamine
- d. Riboflavine.
- e. Pyridoxine

Ans. The key is A. Folic acid. [Frequently associated with neural tube defect].

53. A 23yo woman has been having pain at the base of her thumb, the pain is reproduced when lifting her 3 month old baby or changing diapers and also with forceful abduction of the thumb against resistance. What is the likely cause?

- a. Avascular necrosis of scaphoid
- b. Trigger finger.
- c. De Quervain's tenosynovitis

Ans. The key is c. De Quervain's tenosynovitis. [Can be diagnosed by Finkelstein's test:

The physician grasps the thumb and the hand is ulnar deviated sharply. If sharp pain occurs along the distal radius (top of forearm, about an inch below the wrist), de Quervain's syndrome is likely].

54. A 6m child presents with fever and cough. His mother has rushed him to the ED asking for help. Exam: temp=39C and the child is feeding poorly. Dx?

- a. Bronchiolitis
- b. Asthma
- c. Bronchitis

Ans. The key is A. Bronchiolitis. [Management: 1. Oxygen inhalation 2. Nasogastric feeding. **DON'T USE:** i) bronchodilator ii) steroid iii) antibiotics routinely. [OHCS, 9th edition, page-160]

55. A 75yo man collapsed while walking in his garden. He recovered fully within 30 mins with BP 110/80 mmHg and regular pulse of 70bpm. He has a systolic murmur on examination. His activities have been reduced lately which he attributes to old age. What is the definitive diagnostic inv that will assist you with his condition?

- a. ECG
- b. Echo
- c. 24h ECG monitoring
- d. 24h BP monitoring
- e. Prv CIN

Ans. B. Echo. [2 main D/D. Aortic stenosis and hypertrophic cardiomyopathy. Aortic stenosis – more likely in elderly. And hypertrophic cardiomyopathy – less likely in this age].

56. A 35yo man with a hx of schizophrenia is brought to the ER by his friends due to drowsiness. On examination he is generally rigid. A dx of neuroleptic malignant syndrome except:

- a. Renal failure
- b. Pyrexia
- c. Elevated creatinine kinase
- d. Usually occurs after prolonged tx
- e. Tachycardia

Ans. The key is D. Usually occurs after prolonged tx. [Malignant neuroleptic syndrome usually occurs SOON after start or in increasing dose of antipsychotic drugs! All others mentioned are seen in this syndrome like renal failure, pyrexia, elevated creatinine kinase, tachycardia etc].

57. A 33yo drug addict wants to quit. She says she is ready to stop the drug abuse. She is supported by her friends and family. What drug tx would you give her?

- a. Benzodiazepines
- b. Diazepam
- c. Lithium
- d. Methadone
- e. Disulfiram

Q.1. What is the key.

Q.2. What drugs should you use in i) tobacco abuse and in ii) alcohol abuse?

Ans. 1. Key is **d. Methadone.** (used in opiate abuse)

Ans. 2. i) tobacco abuse: a) bupropion ii) alcohol: a) acamprosate b) disulfiram

58. A 16m child presents with drooling, sore throat and loss of voice. He has fever with a temp of 38.2C. What is your next step towards management?

- a. Direct pharyngoscopy
- b. Call ENT surgeon
- c. Call anesthesiologist
- d. IV fluids
- e. Start antibiotics

Q. 1. What is the key?

Q. 2. What is the diagnosis?

Q. 3. What is the urgent management?

Ans. 1. The key is C. Call anesthesiologist. [As an expert to intubate].

Ans. 2. Diagnosis is Acute epiglottitis.

Ans. 3. In given case urgent intubation is needed to secure airway to prevent closure of airway.

59. A 62yo woman complains of unsteadiness when walking. On examination she has pyramidal weakness of her left lower limb and reduced pain and temp sensation on right leg and right side of trunk up to the umbilicus. Joint position sense is impaired at her left great toe but is normal elsewhere. She has a definite left extensor plantar response and the right plantar response is equivocal. Where is the lesion?

- a. Left cervical cord
- b. Midline mid-thoracic cord
- c. Right mid-thoracic cord
- d. Left mid-thoracic cord
- e. Left lumbo-sacral plexus

Q. 1. What is the key?

Q. 2. What is the name of this condition?

Ans. 1. The key is **d. Left mid-thoracic cord.**

Ans. 2. Brown-segward syndrome. [In brown-segward syndrome paralysis and loss of proprioception on the same (or ipsilateral) side as the injury or lesion, and loss of pain and temperature sensation on the opposite (or contralateral) side as the lesion].

60. A 26yo man presents to ED with increasing SOB on left side and chest pain. He has been a heavy smoker for the past 4 years. He doesn't have any past med hx. What is the likely dx?

- a. Pulmonary embolism
- b. MI
- c. Asthma
- d. Pleural effusion
- e. Pneumothorax

Ans. The key is **e. Pneumothorax.** [Increased shortness of breath and chest pain with no past medical history favours the dx of pneumothorax. Heavy smoking or tobacco is a risk factor for spontaneous pneumothorax].

61. A pt with hepatocellular ca has raised levels of ferritin. What is the most probable cause?

- a. Hemochromatosis
- b. A1 antitrypsin def
- c. Cystic fibrosis

Ans. The key is A. Haemochromatosis. [Hemochromatosis itself is a cause of hepatocellular carcinoma and associated with raised level of ferritin. Serum ferritin levels elevated higher than 200 mcg/L in premenopausal women and 300 mcg/L in men and postmenopausal women indicate primary iron overload due to hemochromatosis, especially when associated with high transferrin saturation and evidence of liver disease. Ferritin concentration higher than 1000 mcg/L suggests liver damage with fibrosis or cirrhosis].

62. A woman has electric pains in her face that start with the jaw and move upwards. Her corneal reflexes are normal. What is the most likely dx?

- a. Atypical face pain
- b. Trigeminal neuralgia
- c. Temporomandibular joint dysfunction
- d. GCA
- e. Herpes zoster

Ans. 1. Key is **b. Trigeminal neuralgia.** [Electric pains in her face that starts with the jaw and moves upwards [this description indicates neurological pain of trigeminal nerve. In trigeminal neuralgia transient loss of corneal reflexes are seen just after attacks but in between attacks corneal reflexes are quite normal].

63. A 32yo man presented with slow progressive dysphagia. There is past hx of retro-sternal discomfort and he has been treated with prokinetics and H2 blockers. What is the probably dx?

- a. Foreign body
- b. Plummer vinson syndrome
- c. Pharyngeal pouch
- d. Peptic stricture
- e. Esophageal Ca

Ans. 1. The key is D. Peptic stricture. [Progressive dysphagia to mostly solid is suggestive of peptic stricture which is supported here by the use of prokinetic drugs and H2 blockers which are used for reflux oesophagitis].

64. A 56yo man comes with hx of right sided weakness & left sided visual loss. Where is the occlusion?

- a. Ant meningeal artery
- b. Mid meningeal artery
- c. Mid cerebral artery
- d. Carotid artery
- e. Ant cerebral artery
- f. Ant communicating artery

Q. 1. What is the key?

Q. 2. How will you differentiate between middle cerebral artery occlusion from anterior cerebral artery occlusion?

Ans. 1. The key is **d.** Carotid artery. [Carotid artery divides to internal and external carotid of which internal continues as middle cerebral ultimately. But just before it becomes middle cerebral internal carotid gives rise to ophthalmic branch. So middle cerebral occlusion may give partial visual loss but not complete mono-ocular blindness. For complete mono-ocular blindness occlusion should be proximal to ophthalmic artery i.e. either in internal carotid or more proximally to carotid artery].

Ans. 2. Middle cerebral artery occlusion: paralysis or weakness of contralateral face and arm (faciobrachial). Sensory loss of the contralateral face and arm.

Anterior cerebral artery occlusion: paralysis or weakness of the contralateral foot and leg. Sensory loss at the contralateral foot and leg.

65. A young college student is found in his dorm unconscious. He has tachyarrhythmia and high fever. He also seems to be bleeding from his nose, which on examination shows a perforated nasal septum. What is the most likely dx?

- a. Marijuana OD
- b. Cocaine OD
- c. Heroin OD
- d. Alcohol OD
- e. CO poisoning

Q. 1. What is the key?

Q. 2. What are the points that favours the diagnosis in given question?

Q. 3. What are other important findings?

Ans. 1. Key is B. Cocaine overdose.

Ans. 2. Points in favour: i) Tachyarrhythmia ii) High fever iii) perforated nasal septum iv) unconsciousness

Ans. 3. Other findings of cocaine toxicity: i) Psychiatric: anxiety, paranoia ii) Tachypnoea iii) Increased energy and talking rapidly iv) Dilated pupils. Also: [rhabdomyolysis, metabolic acidosis, convulsion].

66. A 56yo pt whose pain was relieved by oral Morphine, now presents with progressively worsening pain relieved by increasing the dose of oral morphine. However, the pt complains that the increased morphine makes him drowsy and his is unable to carry out his daily activities. What is the next step in his management?

- a. Oral oxycodone
- b. Oral tramadol
- c. PCA
- d. IV Fentanyl
- e. Diamorphine

Ans. The key is oral oxycodone.

67. A 30yo man presents with a 5cm neck mass anterior to the sternocleidomastoid muscle on the left side in its upper third. He states that the swelling has been treated with antibiotics for infection in the past. What's the most likely cause?

- a. Branchial cyst
- b. Parotitis
- c. Pharyngeal pouch
- d. Thyroglossal cyst
- e. Thyroid swelling

Q. 1. What is the key?

Q. 2. Justify your answer.

Ans. 1. The key is A. Branchial cyst.

Ans. 2. i) Branchial cyst is anterior triangular lump. [parotid is also anterior triangular lump but parotitis regresses with appropriate treatment i.e. becomes normal in size]. ii) pharyngeal pouch is posterior triangular lump. iii) Thyroglossal is midline lump. iv) thyroid swelling moves with swallowing].

68. An 18yo man is rushed into the ER by his friends who left him immediately before they could be interviewed by staff. He is semi-conscious, RR=8/min, BP=120/70mmHg, pulse=60bpm. He is noted to have needle track marks on his arms and his pupils are small. What is the single best initial tx?

- a. Insulin
- b. Naloxone
- c. Methadone
- d. Gastric lavage

Q. 1. What is the key?

Q. 2. What is the diagnosis?

Q. 3. What are the points in favour of the diagnosis?

Ans. 1. The key is B. Naloxone.

Ans. 2. The diagnosis is opiate overdose.

Ans. 3. Points in favour are: i) reduced consciousness ii) RR 8/min (12<) iii) hypotension (here lower normal) iv) miosis v) needle track marks on his arms.

69. A 30yo man and wife present to the reproductive endocrine clinic because of infertility. The man is tall, has bilateral gynecomastia. Examination of the testes reveals bilateral small, firm testes. Which of the following inv is most helpful in dx?

- a. CT of pituitary
- b. Chromosomal analysis
- c. Measure of serum gonadotropins
- d. Measure of serum testosterone

Q. 1. What is the key?

Q. 2. What is the diagnosis?

Q. 3. What are the points in favour of your diagnosis?

Ans. 1. The key is B. Chromosomal analysis.

Ans. 2. The diagnosis is Klinefelter's syndrome. (xxy)

Ans. 3. The points in favour are: i) Infertility ii) Tall stature iii) Bilateral gynecomastia iv) Bilateral small firm testes.

70. An 18yo female just received her A-Level results and she didn't get into the university of her choice. She was brought into the ED after ingestion of 24 paracetamol tablets. Exam: confused and tired. Initial management has been done. Inv after 24h: normal CBC, ABG = pH7.1, PT=17s, Bilirubin=4umol/L, creatinine=83umol/L. What is the next step in management?

- a. Observation for another 24h
- b. Refer to psychologist
- c. Give N-Acetylcysteine
- d. Discharge with psychiatry referral
- e. Liver transplantation

Q. 1. What is the key?

Q. 2. What are the indications of this management?

Ans. 1. The key is E. Liver transplantation.

Ans. 2. King's College Hospital criteria for liver transplantation in paracetamol-induced acute liver failure.

arterial pH <7.3 or arterial lactate >3.0 mmol/L after adequate fluid resuscitation, OR if all three of the following occur in a 24-hour period: Creatinine >300 µmol/L. PT >100 seconds (INR >6.5). Grade III/IV encephalopathy.

71. A 75yo alcoholic presents with a mass up to umbilicus, urinary dribbling, incontinence, and clothes smelling of ammonia. What is the next step in management?

- a. Urethral catheter
- b. Suprapubic catheter
- c. Antibiotics
- d. Condom catheter
- e. Nephrostomy

Q. 1. What is the key?

Q. 2. What is the cause of this retention?

Ans. 1. The key is A. Urethral catheter.

Ans. 2. Alcohol consumption [Alcoholism can cause urinary retention but it is a less common cause of retention].

72. In CRF, main cause of Vit D deficiency is the failure of:

- a. Vit D absorption in intestines
- b. 25 alpha hydroxylation of Vit D
- c. Excess Vit D loss in urine
- d. 1 alpha hydroxylation of Vit D
- e. Availability of Vit D precursors

Ans. The key is D. 1 alpha hydroxylation of Vit D. [There are 3 steps in the synthesis of vitamin D. i) Cholecalciferol in the skin from 7-dehydrocholesterol under the action of ultraviolet light. ii) Hydroxylation in the liver of cholecalciferol to 25-hydroxycholecalciferol. iii) Hydroxylation in the kidneys (1 alpha hydroxylation by enzyme 1-alpha-hydroxylase) of 25-hydroxycholecalciferol to calcitriol (1,25-dihydroxyvitamin D3)].

73. Pt with puffiness of face and rash showing cotton wool spots on fundoscopy. What's the dx?

- a. Macular degeneration
- b. Hypertensive retinopathy
- c. Diabetic background
- d. Proliferative diabetic retinopathy
- e. SLE

Q. 1. What is the key?

Q. 2. Why there is puffiness of face?

Q. 3. Why there is cotton wool spots on fundoscopy? What is the most common ocular manifestation of SLE?

Ans. 1. The key is SLE.

Ans. 2. Puffiness is due to lupus nephritis.

Ans. 3. SLE, can involve the retina. The classic lesion of SLE is a white fluffy appearing lesion within the retina known as a cotton wool spot. The most common ocular manifestation in SLE is Keratoconjunctivitis sicca.

74. A 35yo man presents with progressive breathlessness. He gave a hx of polyarthralgia with painful lesions on the shin. CXR: bilateral hilar lymphadenopathy. What's the most likely dx?

- a. Bronchial asthma
- b. Cystic fibrosis
- c. Sarcoidosis
- d. Bronchiectasis
- e. Pneumonia

Q. 1. What is the key?

Q. 2. What is the specific name of this condition? What is the triad?

Ans. 1. The key is C. Sarcoidosis.

Ans. 2. Lofgren syndrome. The triad is i) Erythema nodosum ii) Bilateral hilar lymphadenopathy iii) Arthralgia.

75. A child presents with clean wound, but he has never been immunized as his parents were worried about it. There is no contraindication to immunization, what is the best management?

- a. Full course of DTP
- b. 1 single injection DT
- c. 1 single injection DTP
- d. Only Ig
- e. Antibiotic

Ans. The key is A. Full course of DTP.

76. A 65yo HTN man presents with lower abdominal pain and back pain. An expansive abdominal mass is palpated lateral and superior to the umbilicus. What is the single most discriminating inv?

- a. Laparoscopy
- b. KUB XR
- c. Pelvic US
- d. Rectal exam
- e. Abdominal US

Q. 1. What is the key?

Q. 2. What is the diagnosis?

Q. 3. What are the points given here in favour of your diagnosis?

Ans. 1. The key is E. Abdominal US.

Ans. 2. The diagnosis is Abdominal aortic aneurism.

Ans. 3. Points in favour of AAA are i) hypertension ii) abdominal pain iii) back pain iv) expansile abdominal mass lateral and superior to the umbilicus.

77. A 55yo man has had severe pain in the right hypochondrium for 24h. The pain comes in waves and is accompanied by nausea. Nothing seems to relieve the pain. He feels hot and sweaty but has normal temp. What is the most appropriate next inv?

- a. US Abdomen
- b. ERCP
- c. MRCP
- d. Serum amylase
- e. UGI endoscopy

Q. 1. What is the key?

Q. 2. What is the diagnosis?

Q. 3. What are the points in favour of your diagnosis?

Ans. 1. The key is A. US abdomen.

Ans. 2. The diagnosis is biliary colic.

Ans. 3. Points in favour- i) severe right hypochondrial pain. ii) colicky nature of the pain (comes in waves) iii) nausea iv) absence of fever v) absence of jaundice. [OHCM, 9th edition, page-637].

78. A 67yo man has deteriorating vision in his left eye. He has longstanding COPD and is on multiple drug therapy. What single medication is likely to cause this visual deterioration?

- a. B2 agonist
- b. Corticosteroid
- c. Diuretic
- d. Theophylline

Q. 1. What is the key?

Q. 2. What is the cause of deteriorating vision?

Ans. 1. The key is B. Corticosteroid.

Ans. 2. Prolonged corticosteroids [also topical i.e. eye drop] can cause cataract.

79. A woman who returned from abroad after 3 weeks of holiday complains of severe diarrhea of 3 weeks. She also developed IDA and folic acid def. What condition best describes her situation?

- a. Jejunal villous atrophy
- b. Chronic diarrhea secretions
- c. Malabsorption
- d. Increased catabolism
- e. Increased secretions of acid

Q. What is the key?

Ans. The key is C. Malabsorption.

80. A 35yo male is bitterly annoyed with people around him. He thinks that people are putting ideas into his head. What is the single most likely dx?

- a. Thought block
- b. Thought insertion
- c. Thought broadcasting
- d. Thought withdrawal
- e. Reference

Q. 1. What is the key?

Q. 2. In which disease you will find this feature?

Ans. 1. The key is B. Thought insertion.

Ans. 2. It is seen in schizophrenia.

81. A 10yo girl presents with hoarseness of the voice. She is a known case of bronchial asthma and has been on oral steroids for a while. What is the most likely cause of hoarseness?

- a. Laryngeal candidiasis
- b. Infective tonsillitis
- c. Laryngeal edema
- d. Allergic drug reaction
- e. Ludwigs angina

Q. 1. What is the key?

Q. 2. What is the reason for this condition?

Ans. 1. The key is A. Laryngeal candidiasis.

Ans. 2. Steroids predisposes to fungal infection.

82. A lady with breast cancer has undergone axillary LN clearance. She develops arm swelling after being stung by a bee. What is the most likely mechanism responsible for the swelling?

- a. Lymphedema
- b. Cellulitis
- c. Hypersensitivity reaction
- d. DVT
- e. Fluid retention

Q. 1. What is the key?

Q. 2. What is the reason for this condition?

Ans. 1. The key is A. Lymphoedema.

Ans. 2. Reason is compromised lymphatic drainage of arm due to axillary LN clearance. So if there is any inflammation or swelling, lymph drainage is compromised further giving rise to swelling of limb of that

operated side.

83. A 34yo pt presents with 50% partial thickness burns. What should be the most appropriate management?

- a. IV fluids calculated from the time of hospital arrival
- b. IV fluids calculated from the time of burn
- c. No IVF
- d. IV dextrose stat
- e. Burns ointment

Q. 1. What is the key?

Q. 2. How the calculation of fluid is made?

Ans. 1. The key is B. IV fluids calculated from the time of burn.

Ans. 2. Resuscitation fluids required in the first 24 hours from the time of injury. For adults: 3 ml (in partial thickness burn) of Hartmann's solution/kg body weight/% total body surface area. Half of this calculated volume is given in the first 8 hours and the other half is given over the following 16 hours.

84. A 54yo man has recently been dx with moderate depression. He has hx of MI and is suffering from insomnia. What is the drug of choice for him?

- a. Citalopram
- b. Lofepramine
- c. ECT
- d. Haloperidol
- e. Diazepam

Ans. Key is A. Citalopram. [Sertraline is the drug of choice in post MI as citalopram may be a risk factor for precipitating torsades-de-pointes. But if sertraline is not in option second choice is citalopram and where SSRIs are not suitable next choice is mirtazapine].

85. A man presented with cellulitis and swelling. He was started on flucloxacillin. What other medication do you want to add?

- a. Vancomycin
- b. Penicillin
- c. Metronidazole
- d. Ceftriaxone
- e. Amoxicillin

Q. 1. What is the key?

Q. 2. Please mention why?

Ans. 1. The key is B. Penicillin.

Ans. 2. cellulitis is usually caused by staphylococcus and streptococcus. To cover both Flucloxacillin (for staphylococcus) and

Penicillin (to cover streptococci) should be prescribed.

86. A 24yo college student presents with nausea, vomiting, headache, neck stiffness and a fever of 38.4C. What is the most appropriate empirical antibiotic to be started?

- a. Ceftriaxone
- b. Penicillin
- c. Gentamicin
- d. Tazobactam
- e. Meropenem

Ans. The key is A. Ceftriaxone. [Ceftriaxone is the drug of choice in hospital management. Probable dx is meningitis. [In OHCM- Cefotaxime <55yrs and Cefotaxime + Ampicillin if age >55yrs (pre-hospital)].

87. A man with prosthetic heart valve underwent hemicolectomy and after some days complains of left hypochondriac pain, fever and has a systolic murmur. What is the next inv to ascertain the cause of HF?

- a. CT
- b. Blood culture
- c. ECG
- d. MRI
- e. Radioactive thyroid scan

Q. 1. What is the key?

Q. 2. What is the diagnosis?

Q. 3. Why have you made this diagnosis?

Q. 4. What are the important risk factors for this condition?

Ans. 1. The key is B. Blood culture.

Ans. 2. The diagnosis is infective endocarditis.

Ans. 3. Fever + new murmur = endocarditis until proven otherwise.

Ans. 4. Important risk factors: dermatitis, IV injections, renal failure, organ transplantation, DM, post operative wound. Risk factors for abnormal valves: aortic or mitral valve disease, tricuspid valve in IV drug users, prosthetic valves.

88. A 45yo man with posterior gastric ulcer presented with severe excruciating pain which subsided after conservative treatment. 10 days later he developed swinging pyrexia. US shows a collection in the peritoneum. What will be the most likely location of the collection?

- a. Hepatorenal pouch
- b. Left paracolic gutter
- c. Subphrenic
- d. Pelvic cavity
- e. Lesser sac

Ans. The key is E. Lesser sac.

89. A 23yo lady was prescribed with azithromycin 1gm for her chlamydial pelvic infection. She has got a new boyfriend for the last 2 months. She has recently started contraception to avoid conception. Which of the following contraception method will be affected by azithromycin?

- a. Barrier
- b. IUCD
- c. POP
- d. COCP

Ans. None of them! Before it was thought that hepatic enzyme inhibitor drugs may affect COCP but later it was established that actually there is no such significant effect. Only drugs like rifampicin, rifabutin etc. can cause this. [For exam purpose if you have to choose one please choose D. COCP].

90. An 11yo boy is being checked by the diabetic specialist nurse. His HbA1c was high and he has been skipping meals recently. He has been unhappy at school. Which single member of the clinical team would you refer him to next?

- a. GP
- b. Pediatrician
- c. Dietician
- d. Clinical psychologist

Ans. The key is D. Clinical psychologist. [Skipping meals, unhappy at school these are psychological issues. So he should be referred to clinical psychologist].

91. A 35yo man who has served in the army presents with lack of interest in enjoyable activities and feeling low. He doesn't feel like reading the news or watching movies as he believes there is violence everywhere. What is the most appropriate first line therapy?

- a. Citalopram
- b. Lofepamine
- c. CBT
- d. Chlordiazepoxide
- e. Desensitization

Q. 1. What is the key?
Q. 2. What is the diagnosis?
Q. 3. What is the first line treatment?

Ans. 1. The key is C. CBT
Ans. 2. The diagnosis is mild depressive illness.
Ans. 3. In mild depressive illness CBT is preferred option.

92. A man has reducible bulge below the pubic tubercle, and on occlusion of the deep inguinal ring, cough impulse is present. What is the most likely dx?

- a. Direct inguinal
- b. Indirect inguinal
- c. Femoral
- d. Spigelian
- e. Lumbar

Q. 1. What is the key?
Q. 2. What are the points in favour of your answer?

Ans. 1. The key is C. Femoral hernia.

Ans. 2. It is just below the pubic tubercle that is just below the inguinal ligament. On occlusion of deep ring cough impulse is present (means visible) as femoral hernia doesn't come through deep ring but indirect inguinal hernia.

93. A 48yo woman is admitted to ED with a productive cough and moderate fever. She has often central chest pain and regurgitation of undigested food most times but doesn't suffer from acid reflux. These symptoms have been present for the last 3.5 months which affects both food and drink. A CXR shows an air-fluid level behind a normal sized heart. What is the most likely dx?

- a. Pharyngeal pouch
- b. Hiatus hernia
- c. Bulbar palsy
- d. Achalasia
- e. TB

Q. 1. What is the key?
Q. 2. What are the points in favour?

Ans. 1. The key is D. Achalasia.

Ans. 2. Points in favour: Aspiration pneumonia due to retained food and fluid in oesophagus. In achalasia usually there is no acid reflux. Dysphagia for both food and drink. Air-fluid level behind heart.

Why it is not hiatus hernia?

Ans. Differentiating point:- i) In hiatus hernia usually you will get associated GORD ii) Also in hiatus hernia there may be nausea or vomiting.

Why it is not pharyngeal pouch?

Ans. In pharyngeal pouch there will be halitosis.

94. A 64yo man has been waking up in the middle of the night to go to the bathroom. He also had difficulty in initiating micturition and complains of the pt was prepared for a TURP. What electrolyte abnormality is highly likely due to this surgery?

- a. Hypokalemia
- b. Hypocalcemia
- c. Hyperkalemia
- d. Hyponatremia
- e. Hypernatremia

Q. 1. What is the key?
Q. 2. Why this happens?

Ans. 1. The key is D. Hyponatremia.

Ans. 2. Absorption of fluid used for bladder irrigation to flush out blood clots and IV fluids all may lead to hypervolaemia and dilutional hyponatremia.

95. A 56yo lady has developed severe right sided headache which worsens whenever she comes to bright light since the last 4 days. She feels nauseated, but doesn't vomit. What is the most likely dx?

- a. SAH
- b. Brain tumor
- c. Migraine
- d. Cluster headache
- e. Subdural headache

Q. 1. What is the key?
Q. 2. What is the type of the given case?
Q. 3. What are the points in favour of mentioned type?

Ans. 1. The key is C. Migraine.

Ans. 2. It is migraine without aura.

Ans. 3. Criteria of migraine without aura: ≥ 5 headaches lasting 4-72 hours + nausea/vomiting (or photo/phono-phobia) + any 2 of: i) unilateral ii) pulsating iii) worsen by routine activity [OHCM, 9th edition, page-462].

96. A 35yo man presented with hematuria, abdominal swelling and has a BP of 190/140. What is the most diagnostic inv?

- a. Cystoscopy
- b. USG
- c. CT
- d. Renal biopsy
- e. Urine analysis

Q. 1. What is the key?
Q. 2. What is the diagnosis?
Q. 3. What will be the USG findings to establish diagnosis in given case?

Ans. 1. The key is B. USG.

Ans. 2. The diagnosis is ADPKD.

Ans. 3. In given case patients age is 35. So the USG diagnostic criteria is: Age 18 – 39 yrs >3 unilateral or, bilateral cysts, 40 – 59 yrs >2 cysts in each kidney, >60 yrs >4 cysts in each kidney. [OHCM, 9th edition, page- 312].

97. A young man is brought to the ED after an RTA. His GCS on initial evaluation is 6. What is the most appropriate next step?

- a. CT
- b. MRI
- c. IV fluids
- d. Skull XR
- e. Secure airway

Ans. The key is E. Secure airway.

98. A 65yo man presented with frank hematuria. He has no other urinary symptoms. What is the most appropriate next step that will lead to the dx?

- a. IVU
- b. US Abdomen
- c. Cystoscopy
- d. Mid-stream urine for culture
- e. Transrectal US

Q. 1. What is the key?

Q. 2. What is the diagnosis?

Q. 3. What are the reasons for this diagnosis?

Q. 4. If there is painless haematuria in young (say 25-30yrs) what diagnosis will come first?

Ans. 1. Key is C. Cystoscopy.

Ans. 2. Bladder cancer.

Ans. 3. Age 65, asymptomatic haematuria.

Ans. 4. ADPKD [at the beginning there is very few or no symptoms].

99. A 30yo woman had a gradual decrease of visual acuity since the last 3 years. Now she has a disability due to very low vision. What's the dx?

- a. Glaucoma
- b. Cataract
- c. Macular degeneration
- d. Retinitis pigmentosa
- e. Keratitis

Q. 1. What is the key?

Q. 2. Why it is not the other given D/D s?

Ans. 1. The key is D. Retinitis pigmentosa.

Ans. 2. i) It is not angle closure glaucoma as angle closure glaucoma occurs usually after the age of 50; In open angle glaucoma visual loss is not evenly gradual rather occurs a bit suddenly at its later part. It is not cataract as cataract occurs usually in elderly. In macular degeneration near blindness does not occur rather causes inability to identify face or cannot read small prints; otherwise peripheral vision is not that depressed. In keratitis will be pain, redness, photophobia and vision is ok.

100. A 27yo lady has had an uncomplicated pregnancy so far. She came to the hospital 2h ago after her water broke. The midwife is looking at her now. She has regular contractions. P.V exam revealed 2cm dilated cervix. Vital signs are normal. What stage of labour is she in?

- a. Second stage
- b. First stage
- c. Latent stage
- d. Third stage
- e. Active phase

Ans. The key is B. First stage. First stage starts with softening of cervix with start of opening of cervix and ends when cervix is fully dilated (i.e. 10 cm dilated).

101. A 2yo boy fell off his tricycle and hurt his arm. He got up to start crying, but before there was any sound, he went pale, unconscious and rigid. He recovered after 1-2 mins but remained pale. After an hour he was back to normal. His mother says she was afraid he was going to die, and that he had a similar episode 3 months prior after falling down some steps. What single inv is indicated?

- a. CT head
- b. EEG
- c. CBC
- d. None
- e. Skeletal survey

Q. 1. What is the key?

Q. 2. What is the diagnosis?

Ans. 1. The key is D. None.

Ans. 2. Diagnosis is breath holding spell.

102. A 29yo woman had just delivered a still born vaginally, following a major placental abruption. Choose the single most likely predisposing factor for developing PPH in this lady?

- a. Retained product
- b. DIC
- c. Fibroid uterus
- d. Uterine infection
- e. Large placental site

Q. 1. What is the key?

Q. 2. What are the causes of this condition here?

Ans. 1. The key is B. DIC.

Ans. 2. Pregnancy itself is a risk factor for DIC. Placental abruption is a more common cause of DIC. Other causes of pregnancy related DIC are: eclampsia, retention of a dead fetus, amniotic fluid embolism, retained placenta or bacterial sepsis.

103. A 28yo woman has delivered with rotational forceps after an 8h labor and 3h second stage. Choose the single most likely predisposing factor for PPH for this pt?

- a. Atonic uterus
- b. Cervical/vaginal trauma
- c. Retained product
- d. Preterm labor
- e. Uterine infection

Ans. The key is B. Cervical/vaginal trauma. [complication of forceps delivery].

104. A 50yo man has had anterior resection of the rectum for carcinoma. He expressed concerns about control of post-op pain in discussions with the anaesthetist before surgery. What is the best management strategy?

- a. Oral diclofenac
- b. Oral codeine
- c. IM morphine
- d. IM dihydrocodeine
- e. Ondansetron oral

Ans. The key is C. IM morphine. [Some post operative pain is severe pain which needs strong opioid analgesics].

105. A 73yo male presents with enlarged cervical nodes. He has had recurrent infections over the last year. His conjunctiva is pale. Choose the single cell type you will find on the blood film.

- a. Granulocyte without blast cells
- b. Myelofibroblasts
- c. Plasma cells
- d. Mature lymphocytes

Q. 1. What is the key?
Q. 2. What is the diagnosis?
Q. 3. What are the points in favour of your diagnosis?

Ans. 1. The key is D. Mature lymphocytes.

Ans. 2. The diagnosis is CLL.

Ans. 3. It is CLL because of his age (73 yrs), cervical lymphadenopathy, recurrent infections (mature but functionally defective lymphocytes), and pale conjunctiva (anaemia).

106. A 45yo lady has 10m hx of SOB. She is found to have irregularly irregular pulse and loud P2 with fixed splitting and ejection systolic murmur in left 2nd ICS. What is the probable dx?

- a. TOF
- b. ASD
- c. VSD
- d. PDA
- e. CoA

Q. 1. What is the key?
Q. 2. What is the diagnosis?

Ans. 1. The key is B. Atrial septal defect.

Ans. 2. Diagnosis is ASD with atrial fibrillation. [i) atrial fibrillation = irregularly irregular pulse. ii) ASD = SOB, fixed splitting with loud P2, ESM in pulmonary area]. This picture is typical. One should not misdiagnose SOB, ESM in pulmonary area and loud P2 as pulmonary hypertension (though in elderly this can develop with ASD).

107. A 5m baby present with recurrent vomiting. Mother noticed some of the vomitus is blood stained. Choose the single most likely inv?

- a. Upper GI endoscopy
- b. Barium meal
- c. US
- d. Colonoscopy
- e. CT abdomen

Ans. The key is A. upper GI endoscopy.

108. A 76yo is treated with HTN. He suffers from pain and redness at the MTP joint of his right big toe. Which of the following anti-HTN cause this symptoms?

- a. Losartan
- b. Bendroflumethiazide
- c. Ramipril
- d. Bisoprolol
- e. Verapamil

Q. 1. What is the key?
Q. 2. What is the diagnosis?
Q. 3. What is the cause of the disease?

Ans. 1. The key is B. Bendroflumethiazide

Ans. 2. Diagnosis is acute gout.

Ans. 3. Thiazide diuretics may cause hyperuricemia and thus cause or precipitate gout.

109. A 33yo male involved in a street fight presents with bruises and deformity in the upper part of his leg. XR shows fx of the neck of fibula. What is the single most associated nerve injury?

- a. Sciatic nerve
- b. Gluteal nerve
- c. Musculocutaneous nerve
- d. Lateral peroneal nerve
- e. Tibial nerve
- f. Femoral nerve

Ans. The key is D. Lateral peroneal nerve. [Lateral peroneal nerve is other name of superficial peroneal nerve].

110. A 35yo man presents with hx of dyspepsia. H.Pylori antibodies are negative. No improvement is seen after 1m of tx. What is the next step?

- a. Urea breath test
- b. Gastroscopy
- c. CT
- d. MRI

Q. 1. What is the key?
Q. 2. What may be the D/D here?
Q. 3. At this age what are the indications of this procedure?

Ans. 1. Gastroscopy.

Ans. 2. Not responding to treatment D/D is: i) Zollinger Ellison syndrome ii) Ca stomach

Ans. 3. Indications of gastroscopy in a 35 yo man (for man of age <50): i) Acute symptoms with H/O previous episode (PUD) ii) Alarm features [weight loss, anaemia, vomiting, hematemesis and melaena, dysphagia, palpable abdominal mass], fear of cancer, evidence of organic disease.

111. A 15yo male has bilateral ankle edema. His BP=110/70mmHg and urinalysis shows protein++++. What is the most likely dx?

- a. HUS
- b. IgA nephropathy
- c. Membranous GN
- d. Minimal change GN
- e. Nephrotic syndrome

Q. 1. What is the key?
Q. 2. What are the points in favour of your diagnosis?

Q. What is the treatment?

Ans. 1. The key is D. Minimal change disease.

Ans. 2. Points in favour: i) Age 15 ii) Ankle oedema iii) Normotension iv) Heavy proteinuria.

Ans. 3. Treatment of choice is steroid (prednisolone). Failure of steroid or frequent relapse (>3) cyclophosphamide.

112. A 28yo man has developed a red, raised rash on trunk after playing football. His PMH shows he had childhood asthma. The rash is becoming increasingly itchy. What is the most appropriate tx?

- a. Oral chlorpheniramine
- b. Oral amoxicillin
- c. IM adrenaline
- d. Nebulized salbutamol
- e. Histamine

Q. What is the key?
Q. 2. What is the diagnosis?

Ans. 1. The key is A. Oral chlorpheniramine.

Ans. 2. Diagnosis is Atopy (allergy).

113. A 72yo man has been advised to have antibiotic prophylaxis for some years now before dental tx. He has never experienced chest pain. Three weeks ago, he noticed breathlessness on exertion and for one week he had orthopnea. His pulse is normal. What is the most probable dx?

- a. Aortic regurgitation
- b. Ischemic mitral regurgitation
- c. Mitral valve prolapse
- d. Pulmonary stenosis
- e. Mitral valve stenosis

Ans. The key is E. Mitral valve stenosis. [Mitral stenosis is the most common valvular complication of rheumatic fever].

114. A 37yo woman presents with fatigue. Exam: angular stomatitis, no koilonychea. Choose the single cell type you will find on the blood film.

- a. Macrocytes
- b. Microcytes
- c. Granulocytes without blast cells
- d. Blast cells

Q. 1. What is the key?

Q. 2. What is the cause here?

Q. 3. What are the points in favour of mentioned cause?

Ans. 1. The given key is A. Macrocytes.

Ans. 2. The cause here is Vit. B12 or folate deficiency.

Ans. 3. Points in favour of Vit. B12 or folate deficiency: i) fatigue (anaemia) ii) angular stomatitis (can be seen in Vit. B12 or folate deficiency) iii) absence of koilonychea is against IDA (Iron Deficiency Anaemia).

115. A 4yo boy with a febrile convulsion lasting eight minutes has been given IV lorazepam to control them. What is the single most likely serious side effect?

- a. Amnesia
- b. Anaphylactic shock
- c. Apnea
- d. Bronchospasm
- e. Cardiac arrhythmia

Ans. The key is C. Apnoea. [Respiratory depression may occur following lorazepam administration].

116. A 4wk girl has been dx of having breast milk jaundice. She is otherwise well. What is the single most appropriate management?

- a. Continue breastfeeding
- b. Exchange transfusion
- c. Increase fluid intake
- d. Phototherapy
- e. Stop breastfeeding

Q. 1. What is the key?

Q. 2. What is breast milk jaundice?

Q. 3. What type of hyperbilirubinemia occurs in breast milk jaundice?

Q. 4. What is the cause of this jaundice?

Ans. 1. The key is A. Continue breast feeding.

Ans. 2. If jaundice lasts past the first week of life in a breastfed baby who is otherwise healthy, the condition may be called "breast milk jaundice."

Ans. 3. Unconjugated hyperbilirubinaemia.

Ans. 4. Cause of breast milk jaundice: factors in a mother's milk that help a baby absorb bilirubin from the intestine.

117. A 12yo girl when playing in the garden accidentally stepped on a hive and was bitten several times. She has numerous wheals on her body and complains of severe itching. What is the single most appropriate management?

- a. Oral antihistamine
- b. IV antihistamine
- c. IM adrenaline
- d. Oral ciprofloxacin
- e. Reassurance

Ans. The given key is C. IM adrenaline which is a wrong key. The correct answer is A. Oral antihistamine. [Intravenous antihistamines are used as an adjunct to epinephrine in the emergency treatment of anaphylaxis and angioedema. Parenteral antihistamine is not recommended in less severe allergic reaction (other than anaphylaxis)].

Followings are the indications of adrenaline in anaphylaxis:

Horseness of voice
Wheeze
Shortness of breath
Shock
Stridor
Swelling of the tongue and cheek
Facial swelling

118. A term baby born to a 30yo woman of blood group A-ve develops severe jaundice within the first 24h of birth. What is the most likely dx?

- a. Hereditary spherocytosis
- b. G6PD
- c. ABO incompatibility
- d. Rh incompatibility
- e. Physiological jaundice

Ans. The key is D. Rh incompatibility.

119. A 4yo girl is found to have bounding pulse and continuous machinery murmur. What is the most probable dx?

- a. TOF
- b. ASD
- c. VSD
- d. PDA
- e. CoA

Ans. The key is D. PDA. [Continuous machinery murmur is well known feature of PDA].

120. A 12yo child with episodes of sudden bluish discoloration and brief loss of consciousness. Exam: clubbing, central cyanosis, systolic thrill with systolic ejection murmur in 2nd left ICS. What is the most probable dx?

- a. TOF
- b. ASD
- c. VSD
- d. PDA
- e. CoA

Ans. The key A. TOF. [TOF usually does not become symptomatic at birth or early infancy and given features (central cyanosis and clubbing with murmur of right ventricular outflow obstruction i.e. ejection systolic murmur in 2nd left ICS) are well known features of TOF]. [Tetralogy of fallot = 1. VSD + 2. Overriding of the aorta + Right ventricular outflow tract obstruction + Right ventricular hypertrophy].

121. An 8yo child who is tall for his age and has a refractory error for which he wears glasses has presented with severe crushing chest pain. What is the most likely dx?

- a. Fragile X syndrome
- b. Prader-willi syndrome
- c. DiGeorge syndrome
- d. Marfans syndrome

Q. 1. What is the key?

Q. 2. What is the cause of this severe crushing chest pain?

Q. 3. What are the most common cardiac abnormalities found in this disease?

Ans. 1. The key is D. Marfans syndrome.

Ans. 2. Cause of severe crushing chest pain may be aortic dissection.

Ans. 3. Most common cardiac abnormalities in Marfans syndrome are: dilatation of the aorta and mitral regurgitation.

122. A 4yo child presents with pain of spontaneous onset in his knee of 2 days duration. He has developed mild fever in the 2nd day. He can walk but has a limp. Exam: painful restriction in the right hip. What is the most probable dx?

- a. Osteosarcoma
- b. Septic arthritis
- c. TB arthritis
- d. Exostosis
- e. Osteomyelitis

Q. 1. What is the key?

Q. 2. What are the points in favour of your diagnosis?

Ans. Given key is E. Osteomyelitis which is a wrong key. The correct answer is B. Septic arthritis.

Ans. Points in favour of diagnosis: i) Pain in joints (knee and hip). In osteomyelitis there is no joint pain but pain in other parts of bone like shaft. ii) Fever iii) Painful restricted movement of joint.

NB This controversial question was debated and ultimately settled as septic arthritis by old plabbers.

123. A man with anterior resection and end to end anastomosis done complains of severe pain in the chest and abdominal distension. What is the most appropriate inv likely to review the cause this deterioration?

- a. XR abdomen
- b. Exploratory laparoscopy
- c. CT
- d. US
- e. Laparotomy

Ans. The key is E. Laparotomy. This is wrong key! Correct key is C. CT. [As many anastomotic leak is self limiting so Laparotomy can not be the answer! Definitive diagnosis is made by CT scan. Here is one link attached. <http://teachmesurgery.com/perioperative/gastrointestinal/anastomotic-leak/>

Investigations

The most appropriate initial investigation for a suspected anastomotic leak is a range of **blood tests** – FBC and CRP (raised WCC and CRP), U&Es, LFTs (low albumin), and a clotting screen.

A **venous blood gas** (raised lactate) will assess degree of tissue perfusion. A repeat Group and Save will be needed for possible surgery or radiological drainage.

The definitive diagnosis of anastomotic leak is made by a **CT scan** (Abdomen Pelvis) with contrast.

124. Pt with hx of alcoholism, ataxic gait, hallucinations and loss of memory. He is given acamprosate. What other drug can you give with this?

- a. Chlordiazepoxide
- b. Thiamine
- c. Diazepam
- d. Disulfiram
- e. Haloperidol

Ans. The key is B. Thiamine. [These are features of Wernicke's encephalopathy].

125. A 35yo male builder presented with sudden onset of severe abdominal pain. He was previously fit and well other than taking ibuprofen for a long term knee injury. On examination he is in severe pain, pulse=110bpm, BP=110/70mmHg and has a rigid abdomen. What is the most likely dx?

- a. Biliary peritonitis
- b. Ischemic colon
- c. Pancreatic necrosis
- d. Perforated diverticulum
- e. Perforated peptic ulcer

Ans. The key is E. Perforated peptic ulcer. [NSAIDs induced perforation. Points in favour- 1. Prolonged use of NSAIDs, 2. Sudden onset of severe abdominal pain, 3. Rigid abdomen].

126. A woman 5 days post-op for bilateral salphingo-oophorectomy and abdominal hysterectomy has developed abdominal pain and vomiting a/w abdominal distension and can't pass gas. No bowel sounds heard, although well hydrated. What is the most appropriate next step?

- a. XR abdomen
- b. Exploratory laparoscopy
- c. CT
- d. USG
- e. Barium enema

Q. 1. What is the key?

Q. 2. What is the diagnosis?

Q. 3. What are the causes of it?

Q. 4. What is the management?

Ans. 1. The key is A. X-ray abdomen.

Ans. 2. The diagnosis is paralytic ileus.

Ans. 3. Causes of paralytic ileus: i) electrolyte imbalance ii) gastro-enteritis iii) appendicitis iv) pancreatitis v) surgical complications and vi) certain drugs.

Ans. 4. Management of paralytic ileus: i) nil by mouth ii) nasogastric suction to alleviate the distension and remove the obstruction.

127. A 30yo man complains of hoarseness of voice. Exam: unilateral immobile vocal cord. What is the most probable dx?

- a. Graves disease
- b. Hematoma
- c. Unilateral recurrent laryngeal nerve injury
- d. External laryngeal nerve injury
- e. Tracheomalacia

Ans. The key is C. unilateral recurrent laryngeal nerve injury.

128. A 38yo woman has delivered after an induced labor which lasted 26h. choose the single most likely predisposing factor for postpartum hemorrhage?

- a. Atonic uterus
- b. Cervical/vaginal trauma
- c. Rupture uterus
- d. Fibroid uterus
- e. Age of mother

Ans. The key is A. Atonic uterus. [Prolonged labour is a risk factor for PPH secondary to atonic uterus].

129. A 32yo woman in tears describing constant irritability with her 2 small children and inability to relax. She describes herself as easily startled with poor sleep and disturbed nightmares following a house fire a year ago, while the family slept. What is the single best tx?

- a. Reassurance
- b. Relaxation therapy
- c. Quetiapine
- d. Lofepramine
- e. Fluoxetine

Q. 1. What is the key

Q. 2. What is the diagnosis?

Q. 3. What are the points in favour of your diagnosis?

Ans. 1 The key is E. Fluoxetine. [NICE guidelines suggest that trauma-focussed psychological therapies (CBT or EMDR) should be offered before medication, wherever possible. As these are not in option the best answer here is Fluoxetine (SSRI). At present, there is evidence that EMDR, psychotherapy, behaviour therapy and antidepressants are all effective. There is not enough information for us to say that one of these treatments is better than another].

Ans. 2. The diagnosis is post traumatic stress disorder.

Ans. 3. Points in favour of PTSD: i) H/O stressor (house fire a year ago) ii) Nightmares of the stressor iii) Hyper arousal (very anxious and inability to relax (leading to irritability) iv) associated depression (poor sleep, tearful).

Note: Fluoxetin and peroxetin are the drugs of choice in PTSD. CBT is the non-pharmacological treatment.

130. A 22yo woman with longstanding constipation has severe ano-rectal pain on defecation. Rectal exam: impossible due to pain and spasm. What is the most probable dx?

- a. Anal hematoma
- b. Anal fissure
- c. Anal abscess
- d. Proctalgia fugax
- e. Hemorrhoids

Ans. The key is B. Anal fissure.

131. A 20yo student attends the OPD with complaint of breathlessness on and off, cough and sputum. His sleep is disturbed and skin is very dry in flexural areas of the body. Exam: tachypnea, hyperresonant percussion and wheezing on auscultation. What is the most likely dx?

- a. Extrinsic allergic alveolitis
- b. Asthma
- c. Wegener's granulomatosis
- d. COPD
- e. Cystic fibrosis

Q. 1. What is the key?

Q. 2. What are the diagnostic criteria?

Ans. The key is B. Asthma.

Ans. 2. Diagnostic criteria of asthma: i) Airway hyper-responsiveness to certain stimuli ii) Recurrent variable airflow limitation usually reversible iii) presents as wheezing, breathlessness, chest tightness and cough.

132. A pt with thought disorder washes hands 6x each time he uses the toilet. What is the best management?

- a. Psychodynamic therapy
- b. CBT
- c. Antipsychotics
- d. Refer to dermatology
- e. Reassure

Q. 1. What is the key?

Q. 2. What is the diagnosis?

Ans. 1. The key is B. CBT. [For OCD CBT is the 1st treatment of choice and if fails comes drugs].

Ans. 2. The diagnosis is obsessive compulsive disorder.

133. A 25yo woman presented to her GP on a routine check up. Upon vaginal exam, she was fine except for finding of cervical ectropion which was painless but mild contact bleeding on touch. What is the next management?

- a. Endometrial ablation
- b. Cervical smear (2nd line)
- c. Colposcopy
- d. Antibiotics (1st line)
- e. Vaginal US
- f. Pack with gauze and leave to dry

Q. 1. What is the key?

Q. 2. Points in favour correct of key.

Ans. The key is D. Antibiotics. This is a wrong key. The correct key is B. Cervical smear. In UK 25 yr is the age when 1st smear is offered. [Before antibiotics we have to take swab. As there is no option of swab and age is 25 yrs we shall go for smear].

Ans. 2. Cervical smear is a screening service which follows its own schedule and can not be done unless it is due or overdue. As the Lady is of 25 years and has ectropion and contact bleeding smear is the best option here as in UK 1st smear is offered at 25 yrs.

134. A 32yo had a normal vaginal delivery 10 days ago. Her uterus has involuted normally. Choose the single most likely predisposing factor for PPH?

- a. Retained product
- b. DIC
- c. Uterine infection
- d. Von Willebrand disease
- e. Primary PPH

Q. 1. What is the key?

Q. 2. What type of PPH it would be?

Ans. 1. The key is C. uterine infection.

Ans. 2. Secondary PPH

135. A 37yo man slipped while he was walking home and fell on his out stretched hand. He complains of pain in the right arm. XR showed fx of the head of radius. What is the single most associated nerve injury?

- a. Radial nerve
- b. Musculocutaneous nerve
- c. Median nerve
- d. Ulnar nerve

Q. 1. What is the key?

Q. 2. What is the root value?

Ans. 1. The key is A. Radial nerve. [At wrist, radial nerve injury cause

finger drop].

Ans. 2. Root value of radial nerve: C5,6,7,8 and T1.

136. A butcher stabbed accidentally his groin. He bled so much that the towel was soaked in blood and BP=80/50mmHg, pulse=130bpm. What % of circulatory blood did he lose?

- a. <15%
- b. 15-30%
- c. 30-40%
- d. 40-50%
- e. >50%

Q. 1. What is the key?

Q. 2. What is the classification of blood loss according to vita sign?

Ans. 1. The key is C. 30-40%

Ans. 2. Classification:

Class 1 up to 15% of blood volume lost: pulse <100; systolic BP normal; pulse pressure normal; Respiratory rate 14-20; urine output greater than 30 ml/hour.

Class 2 15%-30% blood volume lost: pulse 100-120; systolic blood pressure normal; pulse pressure decreased; respiratory rate 20-30; urine output 20-30 ml/hour.

Class 3 30%-40% blood volume lost: pulse 120-140; systolic BP decreased; pulse pressure decreased, respiratory rate 30-40; urine output 5-15 ml/hr

Class 4, blood loss of greater than 40%: pulse rate >140; systolic BP decreased; pulse pressure decreased' respiratory rate >35; urine output negligible.

137. A 67yo man presents with palpitations. ECG shows an irregular rhythm and HR=140bpm. He is otherwise stable, BP=124/80mmHg. What is the most appropriate management?

- a. Bisoprolol
- b. ACEi
- c. Ramipril
- d. Digoxin

Ans. The key is A. Bisoprolol. [In acute AF (<48h) if stable rate control by verapamil 40-120mg/8hourly po or bisoprolol 2.5-5mg/d po. In chronic AF (>48h) rate control with beta-blocker or rate limiting CCB; OHCM, 9th edition, page-124].

138. A 78yo man is depressed after his wife's death. He has been neglecting himself. His son found him in a miserable state when he went to visit. The son can't deal with his father. What is the appropriate management?

- a. Voluntary admission to psychiatry ward
- b. Hand over to social worker
- c. Request son to move in with father
- d. Send pt to care home

Ans. The key is A. Voluntary admission to psychiatry ward.

139. An old alcoholic presents with cough, fever, bilateral cavitating consolidation. What is the most probable cause?

- a. Gram +ve diplococcus
- b. Coagulase +ve cocci
- c. Gram -ve cocci
- d. AFB
- e. Coagulase -ve cocci

Q. 1. What is the key?

Q. 2. What is the organism?

Ans. 1. The key is B. Coagulase +ve cocci. [The picture is of pneumonia and bilateral cavitating consolidation favours staphylococcus as the causative agent].

Ans. 2. Name of organism is Staphylococcus aureus. [Staphylococci can be both coagulase positive and coagulase negative. Gram positive diplococcus is pneumococcus and gram negative neisseria, moraxella catarrhalis and hemophilus influenza. For AFB there should be low grade evening fever with night sweats, weight loss, anorexia etc].

140. A 67yo man had successful thrombolysis for an inf MI 1 month ago and was discharged after 5 days. He is now readmitted with pulmonary edema. What is the most probable dx?

- a. Aortic regurgitation
- b. Ischemic mitral regurgitation
- c. Mitral valve prolapse
- d. Pulmonary stenosis
- e. Rheumatic mitral valve stenosis

Ans. The key is B. Ischaemic mitral regurgitation. [ischaemic mitral regurgitation > raised pulmonary capillary pressure > pulmonary oedema]. [Inferior myocardial infarction causes left ventricular remodeling, which displaces posterior papillary muscle away from its normal position, leading to ischemic mitral regurgitation].

141. A 60yo lady who had stroke 3 years ago now reports having increased dyspnea on exertion and atrial fibrillation. CXR: straight left border on the cardiac silhouette. What is the most probable dx?

- a. Aortic regurgitation
- b. Ischemic mitral regurgitation
- c. Mitral valve prolapse
- d. Pulmonary stenosis
- e. Rheumatic mitral valve stenosis

Q. 1. What is the key?

Q. 2. What are the points in favour of your answer?

Ans. 1. The key is E. Rheumatic mitral valve stenosis.

Ans. 2. Points in favour: i) Dyspnoea on exertion ii) Straight left border of the cardiac silhouette. To straighten the left heart border it requires underfilling of the left ventricle and aorta which occurs in mitral stenosis. Iii) Atrial fibrillation is a common association.

142. A 60yo diabetic complains of pain in thigh and gluteal region on walking up the stairs for the last 6 months. She is a heavy smoker and has ischemic heart disease. What is the most appropriate dx?

- a. Thromboangitis Obliterans
- b. Sciatica
- c. DVT
- d. Atherosclerosis
- e. Embolus

Q. 1. What is the key?

Q. 2. What are the points in favour?

Ans. 1. The key is D. Atherosclerosis.

Ans. 2. i) It is not sciatica as sciatica pain is worse when sitting. There may be weakness, numbness, difficulty moving the leg or foot. A constant pain on one side of the rear. A shooting pain that makes it difficult to stand up. ii) It is not DVT as no swelling, warmth or redness of skin are there iii) It is not thromboangitis obliterans as pulses are ok, no colour change or reduced hair growth, no ulceration or gangrene iv) not embolism as no pain (rest pain), no numbness, no redness or itching or rash, no ulceration of skin.

143. A 3yo child who looks wasted on examination has a hx of diarrhea on and off. The mother describes the stool as bulky, frothy and difficult to flush. What is the single inv most likely to lead to dx?

- a. Sweat chloride test
- b. Anti-endomysial antibodies
- c. LFT
- d. US abdomen
- e. TFT

Q. 1. What is the key?

Q. 2. What is the diagnosis?

Ans. 1. The key is B. Anti-endomysial antibody

Ans. 2. The diagnosis is celiac disease. [It is not cystic fibrosis as lung problem is most commonly seen in cystic fibrosis along with GI problem like indigestion].

144. A 45yo woman has had severe epigastric and right hypochondrial pain for a few hours. She has a normal CBC, serum ALP is raised, normal transaminase. 3 months ago she had a cholecystectomy done. What is the most appropriate inv?

- a. US abdomen
- b. ERCP
- c. MRCP
- d. CT abdomen
- e. Upper GI endoscopy

Q. 1. What is the key?

Q. 2. What is the diagnosis?

Ans. 1. The key is B. ERCP. It is probably a wrong key and correct key should be C. MRCP. [Post operative US of abdomen does not give good result for hepatobiliary system. ERCP is invasive procedure and it has its considerable complications like cholangitis, injury, pancreatitis etc. Among given options MRCP is most appropriate. We shall go for ERCP after making the dx confirm. For this MRCP is preferred. If the question asks which is the "DEFINITIVE" or the "MOST DIAGNOSTIC" then the option will be ERCP].

Ans. 2. Diagnosis is choledocolithiasis.

145. A 53yo woman presented with pain in the eye, blurry vision and clumsiness for 3 months. She has a hx of difficulty in swallowing and weakness in her right upper limb 2y ago. What is the inv of choice?

- a. CSF analysis
- b. EEG
- c. EMG
- d. MRI brain
- e. Visual evoked response test

Q. What is the key?

Q. What is the diagnosis?

Ans. 1. The key is D. MRI brain.

Ans. 2. Diagnosis is multiple sclerosis.

146. A 55yo male presents with malaise and tiredness. Exam: spleen approaching RIF, no lymphadenopathy. Choose the single cell type?

- a. Helmet shaped cell
- b. Sick cell
- c. Granulocyte without blast cells
- d. Blast cells

Q. 1. What is the key?

Q. 2. What is the diagnosis?

Q. 3. What are the diagnostic features?

Ans. 1. The key is C. Granulocyte without blast cells.

Ans. 2. The diagnosis is CML.

Ans. 3. Diagnostic features are i) increased number of mature granulocytes ii) huge splenomegaly.

[* Helmet shaped cells (or shistocytes) = hemolytic or Microangiopathic hemolytic anemia

* Sick cell = sickle cell anemia

* Blast cells (immature cells) = in acute leukemia].

147. A 6yo pt comes with easy bruising in different places when she falls. CBC: WBC=25, Hgb=10.9, Plt=45. Her Paul Bunnell test +ve. What is the most likely dx?

- a. Glandular fever
- b. ITP
- c. Trauma
- d. NAI
- e. Septicemia

Q. 1. What is the key?

Q. 2. What are the lab. Values that suggests the diagnosis here?

Ans. 1. The key is A. Glandular fever.

Ans. 2. Suggestive lab. Values: WBC=25 (leucocytosis), Hgb=10.9 (usually patient is not anaemic), Plt=45 (thrombocytopenia-leading to easy bruising), Positive Paul Bunnell test.

148. A 41yo woman who has completed her family, has suffered from extremely heavy periods for many years. No medical tx has worked. She admits that she would rather avoid open surgery. After discussion, you collectively decide on a procedure that wouldn't require open surgery or GA. Select the most appropriate management for this case.

- a. Endometrial ablation
- b. Hysterectomy
- c. Fibroid resection
- d. Myomectomy
- e. Uterine artery embolization

Ans. The key is E. Uterine artery embolization. [Done by interventional radiologist expert in arterial embolization technique. Particles are placed in uterine artery to block circulation to uterine body. No operation or GA is required].

149. A girl with hx of allergies visited a friend's farm. She got stridor, wheeze and erythematous rash. What is the most appropriate tx?

- a. 0.25ml IM adrenaline
- b. 0.25ml PO adrenaline
- c. 0.25ml IV adrenaline
- d. IV chlorpheniramine

Ans. The key is A. 0.25 ml IM adrenaline [Presence of stridor and wheeze are suggestive of anaphylaxis and treatment option is IM adrenaline].

150. A 5yo boy is referred to the hospital and seen with his father who is worried that he has been listless. He is not sure why his GP suggested he should come to the ED and is keen to get some tablets and go home. Exam: tired and irritable, swelling around eyes. Renal biopsy: remarkable for podocyte fusion on EM. What is the most probable dx?

- a. NAI
- b. Myelodysplastic disease
- c. HSP
- d. Membranous GN
- e. Minimal change GN

Ans. The key is E. Minimal change glomerulonephritis. [Podocyte fusion on electron microscopy].

151. A 6yo boy is brought to the hospital for a 3rd episode of sore throat in 1 month. He is found bleeding from gums and nose and has pale conjunctiva. What's the single cell type?

- a. Clumped platelets
- b. Microcytes
- c. Granulocyte without blast cells
- d. Blast cells
- e. Mature lymphocytes

Q. 1. What is the key?

Q. 2. What is the diagnosis?

Q. 3. What are the points that favour diagnosis?

Ans. 1. The key is D. Blast cells.

Ans. 2. The diagnosis is ALL

Ans. 3. Points in favour: i) Age-6yrs ii) recurrent infection (sore throat) due to neutropenia and abnormal lymphoblasts which cannot protect from infection iii) thrombocytopenia causing gum and nose bleeding. Iii) anaemia (pale conjunctiva) due to reduced red cell production from marrow occupation by blast cells. [Here debate came why it is not aplastic anaemia? There is no risk factor mentioned for this patient for aplastic anaemia. There may be congenital aplastic anaemia but again it would present earlier in life. So it goes more with leukaemia but it cannot be confirmed unless we do bone marrow aspiration.]

152. A 23yo man has been stabbed in the back and has SOB. The trachea is not deviated, he has engorged neck veins and absent breath sounds on the right. What is the most appropriate dx?

- a. Tension pneumothorax
- b. Cardiac tamponade
- c. Simple pneumothorax
- d. Hemothorax
- e. Pleural effusion

Q. 1. What is the key?

Q. 2. What are the point in favour of your answer?

Ans. 1. The key is A. Tension pneumothorax.

Ans. 2. Points in favour: i) Stab wound in the back ii) SOB iii) Engorged neck vein iv) Absent breath sound.

These features are common for both hemothorax and tension pneumothorax and tracheal deviation is common to both! This is probability of bad recall!!

153. A 44yo pt comes with right hemiparesis. Exam: left sided ptosis and left dilated pupil. Where is the lesion?

- a. Cerebral infarct
- b. Cerebellar infarct
- c. Medulla oblongata
- d. Pons
- e. Midbrain

Q. 1. What is the key?

Q. 2. What is the name of this condition?

Ans. 1. The key is E. Midbrain.

Ans. 2. Weber syndrome [presence of ipsilateral oculomotor nerve palsy and contralateral hemiparesis or hemiplegia].

154. A 50yo man has a stab wound to his left anterior chest at the level of the 4th ICS. He has a BP 80mmHg, pulse=130bpm. His neck veins are dilated and his heart sounds are faint. His trachea is central. What is the most appropriate dx?

- a. Cardiac tamponade
- b. Diaphragmatic rupture
- c. Fractured ribs
- d. Tension pneumothorax
- e. Traumatic rupture of aorta

Q. 1. What is the Key?

Q. What are the points in favour of your answer?

Ans. 1. The key is Cardiac tamponade.

Ans. 2. Points in favour: i) Systolic BP 80 mmHg ii) Pulse 130 bpm iii) Engorged neck vein iv) Faint heart sounds v) Trachea is central.

155. A 15yo boy has a soft painless swelling in the left scrotum, blue in color and can be compressed. What is the most appropriate next step?

- a. Analgesia
- b. Antibiotic
- c. Biopsy
- d. Immediate surgery
- e. Reassurance

Q. 1. What is the key?

Q. 2. What is the name of this condition?

Ans. 1. The key is E. Reassurance.

Ans. 2. Name of the condition is Varicocele.

156. A 12yo pt presents with copious diarrhea. Exam: urine output=low, mucous membrane=dry, skin turgor=low. What is the most appropriate initial management?

- a. Antibiotic
- b. Antimotility
- c. Anti-emetic
- d. Fluid replacement
- e. Reassurance

Q. 1. What is the key?

Q. 2. What is the diagnosis and why?

Ans. 1. The key is D. Fluid replacement.

Ans. 2. Diagnosis is severe dehydration. Points in favour: i) low urine output ii) dry mucous membrane and iii) low skin turgor.

157. A 60yo smoker presents with cramp-like pain in the calves relieved by rest and non-healing ulcers. Exam: cold extremities with lack of hair around the ankles, absent distal pulses. What is the most probable dx?

- a. Intermittent claudication
- b. Chronic ischemia of the limbs
- c. Buerger's disease
- d. DVT
- e. DM

Q. 1. What is the key?

Q. 2. Points that support your diagnosis.

Ans. 1. The key is B. Chronic ischaemia of the limb.

Ans. 2. Intermittent claudication is a symptom not diagnosis. It is not Buerger's disease as Buerger occurs in more younger heavy smokers (before the age of 50yrs). It is not DVT as DVT pain or tenderness is not of an intermittent claudication pattern. Again in DM there is no intermittent claudication.

158. An otherwise healthy 13yo boy presents with recurrent episodes of facial and tongue swelling and abdominal pain. His father has had similar episodes. What is the most likely dx?

- a. C1 esterase deficiency
- b. HIV
- c. Mumps
- d. Sarcoidosis
- e. Sjogren's syndrome

Q. 1. What is the key?

Q. 2. What is the name of this condition?

Q. 3. Why is it not acquired?

Ans. 1. The key is A. C1 esterase inhibitor deficiency.

Ans. 2. Hereditary angioedema.

Ans. 3. Acquired angioedema usually manifests after the age of 40 yrs.

159. A 25yo had an LSCS 24h ago for fetal distress. She now complains of intermittent vaginal bleeding. Observations: O2 sat=98% in air, BP=124/82mmHg, pulse=84bpm, temp=37.8C. The midwife tells you that she had a retained placenta, which required manual removal in the OT. Choose the most appropriate C-Section complication in this case?

- a. Retained POC
- b. Aspiration pneumonia
- c. Endometritis
- d. Uterine rupture
- e. DIC

Q. 1. What is the key?

Q. 2. What are the points in favour?

Ans. 1. The key is C. Endometritis.

Ans. 2. More handling of tissue like manual removal of placenta, intermittent vaginal bleeding and raised temperature point toward infective process like endometritis.

160. A 30yo woman has brief episodes of severe shooting pain in the rectum. Rectal examination and flexible sigmoidoscopy are normal. What is the most probable dx?

- a. Anal hematoma
- b. Anal fissure
- c. Rectal carcinoma
- d. Proctalgia fugax
- e. Piles

Ans. is D. Proctalgia fugax [normal rectal examination and flexible sigmoidoscopy excludes other options].

161. A 78yo male, DM and HTN, had a fall and since then is unable to walk. He presents with deformity and tenderness over the right hip area. XR=fx of femur neck. What is the single most associated nerve injury?

- a. Sciatic nerve
- b. Gluteal nerve
- c. Lateral peroneal nerve
- d. Tibial nerve
- e. Femoral nerve

Ans. The key is A. Sciatic nerve. [Sciatic nerve injury though may occur but may not be very common!]

162. A 20yo man has a head on collision in a car. On presentation he is breathless, has chest pain and fx of 5-7th rib. CXR confirms this. What is the most appropriate initial action in this pt?

- a. Antibiotics
- b. Analgesia
- c. O2 by mask
- d. Physiotherapy
- e. Refer to surgeon

Ans. The key is C. O2 by mask. [There was debate in this forum that pain relief should be given first which will automatically relieve breathing problem. But others told O2 first]. O2 first is the correct answer!

Treating Flail Chest

Treatment of flail chest has changed over the years. Doctors today have a good understanding of the secondary influence of flail chest on respiratory failure and survival, compared to the more significant influence of actual injuries to the lungs (such as pulmonary contusions) on those critical outcomes. Management of chest wall injuries is now directed more toward protecting the underlying lungs. Doctors also want to prevent the onset of pneumonia, which is the most common complication of flail chest.

All patients are immediately placed on 100% oxygen using a facemask. Doctors might intubate or insert a chest tube as part of critical care. Stabilization treatment options include:

[<http://www.urmc.rochester.edu/encyclopedia/content.aspx?contenttypeid=22&contentid=flailchest>]

163. A 28yo man with complains of headache and nose bleeds also has pain in the lower limbs on exertion. Exam: radio-femoral delay, cold legs with weak pulse and mild systolic murmur with normal S1S2. What is the most probable dx?

- a. TOF
- b. ASD
- c. VSD
- d. PDA
- e. CoA

Ans. The key is coarctation of aorta. [headache and nosebleeds - >hypertension, pain in lower limb on exertion -> as reduced blood supply to leg due to coarctation, radio-femoral delay, cold legs with weak pulse, mid-systolic murmur are all features of coarctation of aorta].

164. A 23yo male has a tonic clonic seizure whilst at college. His GCS is 12, BP=120/77mmHg, HR=99bpm. What is the most appropriate inv for his condition?

- a. CT
- b. MRI
- c. Serum blood glucose
- d. Serum drug levels

Ans. The key is C. Serum blood glucose [it is also possible that he may have taken drug, even though first we have to do serum glucose as low blood glucose can be very easily managed and it needs urgent management to save life. If it is excluded then we can look for other

causes which may be not fatal in short time as hypoglycaemia].

165. A 20yo man complains of recent onset of itching which followed a viral infection. There are numerous wheals of all sizes on his skin particularly after he has scratched it. These can last up to an hour. What is the most probable dx?

- a. Uremia
- b. Urticaria
- c. Psychogenic itching
- d. Atopic eczema
- e. Primary biliary cirrhosis

Ans. The key is B. Urticaria.

166. A 75yo lady who had mitral valve replacement 13 yrs ago has developed recurrent breathlessness. Her husband has noticed prominent pulsation in her neck. She complains of abdominal pain and ankle swelling. What is the most probable dx?

- a. Aortic regurgitation
- b. Mitral regurgitation
- c. Mitral stenosis
- d. Tricuspid regurgitation
- e. Pulmonary stenosis

Ans. The key is D. Tricuspid regurgitation. [Points in favour: i) recurrent breathlessness - if the cause is LV dysfunction, ii) prominent pulsation in the neck - giant v waves, iii) abdominal pain - pain in liver on exertion, ankle swelling; These are features of tricuspid regurgitation. Reference:- OHCM, 9th edition, page- 142].

167. A 45yo T1DM had an annual check up. Ophthalmoscopy showed dot and blot hemorrhage + hard exudate and multiple cotton wool spots. What is the next step in management?

- a. Reassurance and annual screening only
- b. Urgent referral to ophthalmologist
- c. Laser therapy
- d. Non-urgent referral to ophthalmologist
- e. Nothing can be done

Ans. The key is D. Non-urgent referral to ophthalmologist. [It is pre-proliferative retinopathy so non-urgent referral; If proliferative (with neovascularization) urgent referral].

168. A 2m baby who has ambiguous genitalia presents to the ED with vomiting. Labs: Na+=125mmol/L, K+=6mmol/L. What is the most likely dx?

- a. Fragile X syndrome
- b. Turners syndrome
- c. Noonan syndrome
- d. Congenital adrenal hyperplasia

Q. 1. What is the key?

Q. 2. What are the points in favour?

Ans. 1. The key is D. Congenital adrenal hyperplasia

Ans. 2. Points in favour: i) ambiguous genitalia ii) salt wasting manifested as hyponatremia and hyperkalemia (In mild forms of salt-wasting adrenal hyperplasia, salt wasting may not become apparent until an illness stresses the child). [here hyperkalaemia inspite of vomiting is indicating the disease].

169. A 40yo man collapsed at home and died. The GPs report says he suffered from T2DM and BMI=35. What is the most likely cause of death?

- a. MI
- b. DM
- c. HF
- d. PE
- e. Renal failure

Q. 1. What is the key?

Q. 2. Why the patient's death was unnoticed?

Ans. 1. The key is A. MI.

Ans. 2. In diabetics MI become painless when the patient develop autonomic neuropathy (till there is no autonomic neuropathy diabetic patients will feel MI pain). In this case the disease was unnoticed as it was a painless attack.

170. A 38yo pt presented with tingling, numbness, paraesthesia, resp stridor and involuntary spasm of the upper extremities. She has undergone surgery for thyroid carcinoma a week ago. What is the most likely dx?

- a. Thyroid storm
- b. Hyperparathyroidism
- c. Unilateral recurrent laryngeal nerve injury
- d. External laryngeal nerve injury
- e. Hypocalcemia

Q. 1. What is the key?

Q. 2. What is the cause of this condition?

Q. 3. Why there is respiratory stridor?

Ans. 1. The key is E. Hypocalcaemia.

Ans. 2. Hypocalcaemia may be due to accidental parathyroid gland removal during thyroidectomy.

Ans. 3. Laryngospasm is a feature in hypocalcaemia which may cause stridor.

171. A 50yo chronic smoker came to OPD with complaint of chronic productive cough, SOB and wheeze. Labs: CBC=increase in PCV. CXR >6 ribs seen above the diaphragm in midclavicular line. ABG=pO₂ decreased. What is the most likely dx?

- a. Interstitial lung disease
- b. Wegener's granulomatosis
- c. Ca bronchi
- d. COPD
- e. Amyloidosis

Q. 1. What is the key?

Q. 2. What are the points in favour?

Ans. 1. The key is D. COPD.

Ans. 2. Points in favour: i) Age 50 yrs ii) Chronic smoker iii) Chronic productive cough, SOB and Wheeze iv) Raised PCV secondary to chronic hypoxaemia v) Low set diaphragm and widened horizontal ribs vi) Hypoxaemia on ABC.

172. A 44yo pt has sudden onset of breathlessness and stridor few minutes after extubation for thyroidectomy. The pat had longstanding goiter for which he had the surgery. What is the most likely dx?

- a. Thyroid storm
- b. Hematoma
- c. Unilateral recurrent laryngeal nerve injury
- d. External laryngeal nerve injury
- e. Tracheomalacia

Ans. The key is tracheomalacia. [Prolonged pressure over trachea by goiter is a cause of tracheomalacia following thyroidectomy].

173. A 15yo boy presents with generalized edema. His urinalysis reveals protein +++, eGFR =110. What is the most likely dx?

- a. IgA nephropathy
- b. Membranous nephropathy
- c. Minimal change disease
- d. PSGN
- e. Lupus nephritis

Ans. The key is C. Minimal change disease. [Points in favour: i) Age 15 yrs ii) Generalized oedema iii) Protein in urine +++ vi) Normal eGFR of 110 (Normal range- 90 to 120 mL/min)].

174. A 72yo man is receiving chemotherapy for SCLC. He has his 4th tx 8 days ago. He has a cough with some green sputum but feels well. Temp=37.6C. Chest exam = few coarse crepitations in the right base. HR=92bpm. CBC: Hgb=12.5g/dL, WBC=1.1, Neutrophils=0.6, Plt=89. Sputum, urine and blood culture sent to microbiology. What is the most appropriate management?

- a. Broad spectrum antibiotics IV
- b. Broad spectrum antibiotics PO
- c. GCSF
- d. Postpone tx until bacteriology results available
- e. Reassure and send home

Q. 1. What is the key?

Q. 2. What is the Diagnosis?

Q. 3. What is the treatment of low WBC count?

Ans. 1. The key is A. Broad spectrum antibiotics IV

Ans. 2. The diagnosis is lower respiratory tract infection.

Ans. 3. GCSF subcutaneously. [it is the treatment of chemotherapy induced leucopenia].

175. A 25yo woman with T1DM has delivered a baby weighing 4.5kg. Her uterus is well contracted. Choose the single most likely predisposing factor for PPH from the options.

- a. Atonic uterus
- b. Cervical/vaginal trauma
- c. Retained POC
- d. Large placental site
- e. Rupture uterus

Q. 1. What is the key?

Q. 2. Reason for your answer.

Ans. 1. The key is B. Cervical/vaginal trauma

Ans. 2. The baby is a big baby. If patient's uterus was not well contracted we would fear of atonic uterus! But as uterus is well contracted it is not atonic uterus. Rather most likely cause is trauma during delivery of this big baby.

176. A 23yo lady presents with headache. Exam: photophobia and generalized rash that doesn't blanch on pressure. What must be done immediately?

- a. IV benzylpenicillin
- b. Isolate pt
- c. Gown and mask
- d. Blood culture

Ans. The key is A. IV benzylpenicillin.

177. A 4yo baby has generalized tonic-clonic seizure and fever of 39C. his mother informs you that this has happened 3-4x before. What is the most likely dx?

- a. Febrile convulsion
- b. Absence seizures
- c. Epilepsy
- d. Partial complex seizure

Ans: The key is C. Epilepsy. It is wrong key. Correct key should be A. Febrile convulsion. [Points in favour: seizures in presence of high fever. Same previous illness indicate seizures during fever which goes against epilepsy. Though usually febrile convulsion doesn't tend to recur but it can recur as well. Epilepsy has no relation to fever but is due to pathology in brain].

178. A middle aged Asian presents with episodes of fever with rigors and chills for last 1y. Blood film: ring form plasmodium with schuffner's dots in RBCs. What is the drug to eradicate this infection?

- a. Doxycycline
- b. Mefloquine
- c. Proguanil
- d. Quinine
- e. Artesonate

Q. 1. What is the key?

Q. 2. What does Shuffner's dot in RBC indicate?

Ans. 1. The key is B. Mefloquine. Probably wrong key as mefloquine can not eradicate hepatic cycle! Primaquine is the drug that can eradicate hepatic cycle. None of the given option can eradicate liver cycle!!

Ans. 2. Shuffner's dot indicates, it is plasmodium ovale or plasmodium vivax infestation.

179. A 35yo woman had an uneventful lap chole 18h ago. She has a pulse=108bpm, temp 37.8C. There are signs of reduced air entry at the right base but the CXR doesn't show an obvious abnormality. What is the most appropriate management strategy?

- a. Cefuroxime PO
- b. Ceftriaxone IV
- c. Chlorpheniramine PO
- d. Chest physiotherapy
- e. Reassure

Q. 1. What is the key?

Q. 2. What is the diagnosis?

Ans. 1. The key is D. Chest physiotherapy.

Ans. 2. Atelectasis. [Atelectasis can be seen in chest x-ray but sometimes it becomes undetectable in chest x-ray as we are suspecting in this case].

180. A 20yo pop star singer complains of inability to raise the pitch of her voice. She attributes this to the thyroid surgery she underwent a few months back. What is the most likely dx?

- a. Thyroid storm
- b. Bilateral recurrent laryngeal nerve injury
- c. Unilateral recurrent laryngeal nerve injury
- d. External laryngeal nerve injury
- e. Thyroid cyst

Ans. The key is D. External laryngeal nerve injury. [External laryngeal nerve functions to tense the vocal cords by activating the cricothyroid muscle, increasing pitch].

181. A 28yo woman at 39wk gestation is in labor. She develops abdominal pain and HR=125bpm, BP=100/42mmHg, temp=37.2C and saturation=99%. Exam: lower abdomen is exquisitely tender. CTG=prv normal, now showing reduced variability and late deceleration develops with slow recovery. She has had 1 prv LSCS for a breech baby. Choose the most appropriate CS complication for this lady?

- a. Endometritis
- b. UTI
- c. Urinary tract injury
- d. Pleurisy
- e. Uterine rupture

Ans. The key is E. Uterine rupture. [Features of shock, exquisitely tender lower abdomen with abdominal pain, previously normal CTG now becoming non-reassuring and previous history of LSCS makes the diagnosis of uterine rupture].

182. An 8m infant presented with FTT and constipation. Exam: large tongue and fam hx of prolonged neonatal jaundice. What is the most likely dx?

- a. Downs syndrome
- b. Fragile X syndrome
- c. Praderwilli syndrome
- d. DiGeorge syndrome
- e. Congenital hypothyroidism

Q. 1. What is the key?
Q. 2. What are the points in favour?

Ans. 1. The key is E. Congenital hypothyroidism.
Ans. 2. Points in favour: i) FTT (failure to thrive) ii) constipation iii) macroglossia iv) prolonged neonatal jaundice.

183. A 3m infant has presented with recurrent infections. He has abnormal facies and CXR shows absent thymic shadow. What is the most likely dx?

- a. Downs syndrome
- b. Fragile X syndrome
- c. DiGeorge syndrome
- d. Marfans syndrome

Q. 1. What is the key?
Q. 2. What are the points in favour?

Ans. 1. The key is C. DiGeorge syndrome.
Ans. 2. Points in favour: i) Early age of onset ii) abnormal facies iii) absent thymic shadow on Chest X-ray iii) history of recurrent infection [Infections are common in children due to problems with the immune system's T-cell-mediated response that in some patients is due to an absent or hypoplastic thymus]. [in newborn can be recognized by convulsions from hypocalcaemia due to malfunctioning parathyroid glands and low level of parathyroid hormones].

184. A 30yo man presents with deep penetrating knife wound. He said he had TT when he left school. What will you do for him now?

- a. Human Ig only
- b. Human Ig and TT
- c. Full course of tetanus vaccine only
- d. Human Ig and full course of tetanus vaccine
- e. Antibiotic

Ans. The key is B. Human Ig and TT. It is a wrong key!! According to UK greenbook correct key is A. Human Ig only. [For tetanus vaccine and management uk protocol is a bit different from other countries].

185. A 32yo previously healthy woman has developed pain and swelling of both knees and ankles with nodular rash over her shins. As part of the inv a CXR has been performed. What is the single most likely CXR appearance?

- a. Apical granuloma
- b. Bilateral hilar lymphadenopathy
- c. Lobar consolidation
- d. Pleural effusion
- e. Reticular shadowing in the bases

Q. 1. What is the key?
Q. 2. What is the name of this condition? What are the points in favour?

Ans. 1. The key is B. bilateral hilar lymphadenopathy.
Ans. 2. The name is Lofgren's syndrome. It is the triad of i) erythema nodosum ii) bilateral hilar lymphadenopathy and iii) arthralgia.

186. A neonate's CXR shows double bubble sign. Exam: low set ears, flat occiput. What is the most likely dx?

- a. Downs syndrome
- b. Fragile X syndrome
- c. Turner's syndrome
- d. DiGeorge syndrome

Q. 1. What is the key?
Q. 2. What double bubble sign indicate?

Ans. 1. The key is A. Down's syndrome.
Ans. 2. Double bubble sign indicate duodenal atresia.

187. A 19yo boy complains of itching on the site of insect bite. What is the single most appropriate management?

- a. Penicillin oral
- b. Doxycycline oral
- c. Oral antihistamine
- d. Oral ciprofloxacin
- e. Reassurance

Ans. The key is C. Oral antihistamine.

188. A man presents with scrotal swelling, the swelling is cystic and is non-tender. It is located in the upper pole of the posterior part of the testis. What is the most likely dx?

- a. Epididymal cyst
- b. Testicular ca
- c. Hydrocele
- d. Teratoma
- e. Testicular torsion

Ans. The key is A. Epididymal cyst. [the location of upper pole of the posterior part of testis is the common site for epididymal pathology].

189. A young footballer has collapsed during a game. During initial evaluation: RR=14/min, pulse=88bpm, BP=110/70mmHg. He seems to be sweating and muttering some incomprehensible words. What is the most imp next step?

- a. CT
- b. MRI
- c. Blood sugar
- d. Body temp
- e. IV fluids

Ans. The key is C. Blood sugar. [Normal vital signs, sweating and collapse during exercise gives suspicion of hypoglycemia which is very easy to treat but fatal if left unrecognized. So most important next step is to check the blood sugar].

190. A 45yo waitress complains of pelvic pain which worsens pre-menstrually and on standing and walking. She also complains of post-coital ache. Select the most likely cause leading to her symptoms?

- a. PID
- b. Endometritis
- c. Pelvic congestion syndrome
- d. Adenomyosis
- e. Premature ovarian failure

Ans. The key is C. Pelvic congestion syndrome. [Women with pelvic congestion syndrome experience a constant pain that may be dull and aching, but is occasionally more acute. The pain is worse at the end of the day and after long periods of standing, and sufferers get relief when they lie down. The pain is worse during or after sexual intercourse, and can be worse just before the onset of the menstrual period. Cause is attributed to female hormone estrogen induced vascular (venous) changes. So it is usually seen in females].

191. A 37yo female had a fall with outstretched hand, presented with dinner fork deformity and tenderness over the right arm. What is the single most associated nerve injury?

- a. Axillary nerve
- b. Radial nerve
- c. Musculocutaneous nerve
- d. Median nerve
- e. Ulnar nerve

Ans. The key is D. Median nerve. [Median nerve is the nerve injured in Colle's fracture].

192. A mother comes with her 15m child. Which of the following will bother you?

- a. Shies away from strangers
- b. Can walk but not run
- c. Vocabulary consists of only 2 meaningless words
- d. She can't make a sentence
- e. None

Q. 1. What is the key?

Q. 2. How many words is told clearly by a 15 month old child?

Ans. 1. The key is C. Vocabulary consists of only 2 meaningless words.

Ans. 2. At 15 months the child can clearly say 5 words and his first meaningful clear word he says at 12 months.

193. A 35yo lady who has been using IUCD for one year now complains of pelvic pain and heavy painful periods. Select the most likely cause leading to her symptoms?

- a. PID
- b. Endometriosis
- c. Adenomyosis
- d. Fibroids
- e. Asherman syndrome

Q. 1. What is the key?

Q. 2. What points favour your diagnosis?

Ans. 1. The key is A. PID.

Ans. 2. The given picture may have D/D of PID or fibroid. As IUCD is a risk factor for PID, it is the most likely diagnosis of given picture. Menorrhagia for fibroids are usually painless].

194. The dx cells of Hodgkin disease are:

- a. T-cells
- b. R-S cells
- c. B-cells
- d. Macrophages
- e. Auer rods

Ans. The key is B. R-S cells. [Diagnostic cell in Hodgkins disease is Reed-Sternberg cells].

195. A 16yo girl is admitted after taking a paracetamol OD 4 h ago. She has consumed large amounts of alcohol. Her plasma paracetamol conc is just below the conc that would suggest tx. What should be the tx option for her?

- a. Refer to psychiatry ward
- b. Refer to medical ward
- c. N-acetylcystine
- d. Serum plasma paracetamol
- e. No further investigation

Ans. The key is A. Refer to psychiatry ward. [Short term acute alcohol consumption causes enzyme inhibition as in present case and even then paracetamol level is under tx level. So the patients drug level is in safe side but simultaneous drug overdose and alcohol consumption needs psychiatric evaluation and hence the option here is A].

196. A 64yo woman has been on HRT for 9yrs. She had regular withdrawal bleeds until 3 yrs ago and since then has been taking a no bleed prep. Recently she noticed a brown vaginal discharge. Choose the single most appropriate initial inv?

- a. Cervical smear
- b. High vaginal swab
- c. TFT

d. Transvaginal US

Q. 1. What is the key?

Q. 2. Why this test will be done?

Ans. 1. The key is D. Transvaginal US.

Ans. 2. To determine the endometrial thickness!

In a postmenopausal woman with vaginal bleeding, the risk of cancer is approximately 7.3% if her endometrium is thick (> 5 mm) and < 0.07% if her endometrium is thin (μ 5 mm).

In postmenopausal women without vaginal bleeding, the risk of cancer is approximately 6.7% if the endometrium is thick (> 11 mm) and 0.002% if the endometrium is thin (μ 11 mm).

197. A young girl complains of episodic headaches preceded by fortification spectra. Each episode last for 2-3 days. During headache pt prefers quiet, dark room. What is the tx of choice for acute stage?

- a. Paracetamol
- b. Aspirin
- c. Sumatriptan
- d. Gabapentin
- e. Cafergot

Ans. The key is B. Aspirin. This is a wrong key! Correct key is A. Paracetamol. [Aspirin can cause Reye's syndrome in children, so should not be given. If paracetamol or ibuprofen fail only then triptan should be given].

198. A 60yo pt recovering from a surgery for toxic goiter is found to be hypotensive, cyanosed in the the RR. Exam: tense neck. There is blood oozing from the drain. What is the most likely dx?

- a. Thyroid storm
- b. Reactionary hemorrhage
- c. Secondary hemorrhage
- d. Primary hemorrhage
- e. Tracheomalacia

Ans. The key is B. Reactionary haemorrhage. [in the recovery room, cyanosis, hypotension, tense neck, woozing of blood from drain; all these goes in favour of reactionary haemorrhage. "reactionary," hemorrhage that occurs within the first 24 hours after surgery].

199. A 33yo man is hit by a car. He loses consciousness but is found to be fine by the paramedics. When awaiting doctors review in the ED he suddenly becomes comatose. What is the most likely dx?

- a. SAH
- b. Subdural hemorrhage
- c. Intracerebral hemorrhage
- d. Extradural hemorrhage

Ans. The key is D. Extradural haemorrhage. [Age 33 (younger age), considerable head trauma, and lucid interval (present in both extradural and subdural) are the points in favour].

200. A 77yo male presents with hx of enuresis and change in behavior. Exam: waddling gait. What is the most likely dx?

- a. Subdural hemorrhage
- b. Brain tumor
- c. Normal pressure hydrocephalus
- d. Psychotic depression

Ans. The key is C. Normal pressure hydrocephalus. [age (usually occurs in 60s or 70s), loss of bladder control (enuresis), waddling gait and behavior change are all features of normal pressure hydrocephalus].

201. A 29yo teacher is involved in a tragic RTA. After that incident, he has been suffering from nightmares and avoided driving on the motorway. He has been dx with PTSD. What is the most appropriate management?

- a. CBT
- b. Diazepam
- c. Citalopram
- d. Dosalepin
- e. Olanzapin

Ans. The key is A. CBT. [CBT is the treatment of choice in PTSD].

202. A 5yo child presents with fever. He looks pale. His parents say he always feels tired. On exam: orchidomegaly & splenomegaly. Labs: WBC=1.7, Hgb=7.1, Plt=44. What is the dx?

- a. ALL
- b. CLL
- c. AML
- d. CML
- e. Hodgkins

Ans. The key is A. ALL. [normally in ALL CBC shows raised WBC, low RBC and low platelet; but it is also possible to all cell lines to be depressed, as is the presented case].

203. A 6wk child is brought in with vomiting, constipation and decreased serum K+. What is the dx?

- a. Pyloric stenosis
- b. Duodenal atresia
- c. Hirschsprung disease
- d. Achalasia cardia
- e. Tracheo-esophageal fistula

Ans. The key is A. Pyloric stenosis. [why not duodenal atresia? Pyloric stenosis is much more commoner than duodenal atresia; in duodenal atresia the vomitus should contain bile, which is not the case in pyloric stenosis].

204. A 17 yo girl had an episode of seizure. Contraction of muscles started from around the interphalangeal joints, which spread to the muscles of wrist and elbow. Choose possible type of seizure?

- a. Grand mal
- b. Tonic clonic
- c. Myoclonic
- d. Absent

Ans. The key is C. Myoclonic. [seizers associated with contraction of specific muscle group is seen in myoclonic seizures].

205. 46yo man, known case of chronic GN presents to OPD. He feels well. BP = 140/90mmHg. Urine dipstick: protein ++, blood ++ and serum creatinine=106mmol/L. Which medication can prevent the progression of this dx?

- a. ACEi
- b. Diuretics
- c. Cytotoxic meds
- d. Longterm antibiotics
- e. Steroids

Ans. The key is A. ACEI. [renal impairment is delayed by ACEI].

206. A 23 yo girl presented with perioral paresthesia and carpopedal spasm 20 mins after a huge argument with her boyfriend. What is the next step for this pt?

- a. SSRI
- b. Diazepam
- c. Rebreath into a paper bag
- d. Propranolol
- e. Alprazolam

Q. 1. What is the key?

Q. 2. What is the likely diagnosis?

Ans. 1. The key is C. Rebreathing in paper bag. [hyperventilation causes CO₂ washout and respiratory alkalosis. An increase in pH, alkalo-

sis, promotes increased protein binding, which decreases free calcium levels and this low calcium causes perioral paresthesia and carpopedal spasm. If you continue breathing and rebreathing in paper bag it will allow CO₂ concentration to rise in paper bag and as you rebreath this again and again you will regain some washed out CO₂ and thus relief to this alkalosis].

Ans. 2. The girl may have anxiety disorder when it precipitates leads to hyperventilation syndrome. X

207. A 25 yo woman has been feeling anxious and nervous for the last few months. She also complains of palpitations and tremors. Her symptoms last for a few minutes and are very hard to control. She tells you that taking alcohol initially helped her relieve her symptoms but now this effect is wearing off and she has her symptoms even after drinking alcohol. What is the dx?

- a. Panic disorder
- b. Depression
- c. OCD
- d. Alcohol addiction
- e. GAD

Ans. The key is A. Panic disorder.

208. A 2yo child is very naughty. His teacher complains that he is easily distracted. His parents say that he can't do a particular task for a long time. He sometimes hurts himself and breaks many things. This causes many troubles at home. What is the dx?

- a. ASD
- b. Dyslexia
- c. ADHD
- d. Antisocial personality disorder
- e. Oppositional defiant

Ans. The key is C. ADHD (Attention deficit hyperreactive disorder).

209. A 79 yo lady who is otherwise well recently started abdominal pain. She is afebrile and complains that she passed air bubbles during urination. A urethral catheter showed fecal leakage in the urinary bag. What is the likely pathology?

- a. Diuretics
- b. CD
- c. Rectosigmoid tumor
- d. Large bowel perforation
- e. UC

Ans. The key is B. CD. [debate came that Crohn's disease cannot occur in 79 yrs but this is not the case! "Crohn's disease can occur at any age, but is most frequently diagnosed in people ages 15 - 35. About 10% of patients are children under age 18". [http://www.nytimes.com/health/guides/disease/crohns-disease/risk-factors.html]]. So I think it can occur in this age also and the feature like fistula is a common

association of CD].

210. A 2 month child with diarrhea and vomiting for 6 days is brought in looking lethargic. What is the appropriate initial inv?

- a. BUE
- b. Random blood sugar
- c. CBC
- d. CXR
- e. AXR

Ans. The key is A. BUE. [Electrolyte imbalance should be checked in this baby presenting with diarrhea and vomiting for considerable time].

211. A 72 yo man fell while shopping and hurt his knee. His vitals are fine. He speaks in a low voice and is very slow to give answers. What is the most probable dx?

- a. Alzheimers
- b. Vascular demetia
- c. TIA
- d. Pseudo-dementia
- e. Picks dementia

Ans. The key is A. Alzheimers

212. A 47 yo man met with a RTA. He has multiple injuries. Pelvic fx is confirmed. He has not passed urine in the last 4 hrs. What is the next appropriate management for this pt?

- a. Urethral catheter
- b. Suprapubic catheter
- c. IV fluids
- d. IV furosemide
- e. Insulin

Q. 1. What is the key?

Q. 2. What is the reason of this management?

Ans. 1. The key is B. Suprapubic catheter.

Ans. 2. In pelvic fracture there is chance of urethral rupture and hence displacement of urethral catheter while try to place it.

213. A 49 yo pt presents with right hypochondriac pain. Inv show a big gallstone. What is the most appropriate management?

- a. Lap Cholecystectomy
- b. Reassure
- c. Low fat diet
- d. Ursodeoxycholic acid
- e. Emergency laparotomy

Q. 1. What is the key?

Q. 2. Points in favour?

Ans. 1. The key is A. Lap Cholecystectomy.

Ans. 2. i) as symptomatic only reassurance is not appropriate ii) as big stone ursodeoxycholic acid is less effective iii) less invasiv is preferred so laparoscopic rather than laparotomy.

214. In a man who is neglected and alcohol dependent, whith high suicidal risk, which factor can increase this risk further?

- a. Alcohol dependence
- b. SSRI
- c. S]moking
- d. Agoraphobia
- e. Court involvement

Ans. The key is A. Alcohol dependence. This is wrong key!! Correct key should be B. SSRI. [He is already alcohol dependent. So further (additional) risk factor is SSRI (SSRI has well known risk of developing suicidal ideation)]. Arrest and court involvement is also a risk factor and in a neglected person it is also a strong risk factor.

215. A 71 yo man presents with coarse tremor. He is on some meds. Which one can be the reason for the tremor?

- a. Lithium
- b. Diazepam
- c. Fluoxetine
- d. Imipramine
- e. Haloperidol

Ans. The key is A. Lithium. Actually in therapeutic dose lithium causes fine tremor but in toxic dose it causes coarse tremor. So the probable answer is lithium.

216. A young woman complains of diarrhea, abdominal cramps and mouth ulcers. AXR shows distended transverse colon with goblet cell depletion on rectal biopsy. What is the most probable dx?

- a. CD
- b. UC
- c. Bowel Ca
- d. Bowel obstruction
- e. IBS

Q. 1. What is the key?

Q. 2. What are points in favour?

Ans. 1. The key is B. UC.

Ans. 2. In UC there is goblet cell depletion and less mucous production in contrast with CD where there may be goblet cell hyperplasia

and mucous secretion is not reduced. Please note aphthous ulcer can develop in both CD and UC.

217. After eating a cookie at a garden party, a child began to cough and went blue. The mother also noticed that there were swollen patches on the skin. What is the dx?

- a. Allergic reaction
- b. Aspiration of food
- c. Cyanotic heart disease
- d. Trachea-esophageal fistula
- e. Achalasia cardia

Ans. The key is A. Allergic reaction.

218. A 70 yo man presents with balance difficulties, vomiting and nausea. Which of the following is the best inv?

- a. MRI cerebellum
- b. CT cerebellum
- c. Skull XR
- d. LP
- e. Blood culture

Ans. The key is A. MRI cerebellum. [Balance difficulties, vomiting and nausea suggests cerebellar lesion. In posterior fossa lesion MRI is preferred].

219. A 2 yo pt presents with colicky pain which radiates from loin to groin. He complains of similar episodes in the past. Inv has been done and 7mm stone was found in the ureter. What is the most appropriate management?

- a. Percutaneous nephrolithotomy
- b. Open surgery
- c. Ureteroscopy or laser
- d. Conservative tx
- e. ESWL

Q. 1. What is the key?

Q. 2. What treatments are recommended for different sized stones in Adults?

Ans. 1. The key is E. ESWL. [Given its minimally invasive features, extracorporeal shock wave lithotripsy (ESWL) has become a primary mode of treatment for the pediatric patients with reno-ureteral stones].

Ans. 2. Stones < 5mm: pass spontaneously, Increase fluid intake.

Stones 5mm-10mm /pain not resolving: medical expulsive therapy---> Nifedipine or Tamsulosin(and/or prednisolone).

Stones 10mm-2cm: ESWL or Ureteroscopy using dormia basket.

Stones > 2cm/large/multiple/complex: Percutaneous nephrolithotomy.

220. A footballer has been struck in the groin by a kick and a presents with severe pain and mild swelling in the scrotum. What is the most appropriate next step?

- a. USG
- b. Doppler
- c. Exploratory surgery
- d. IV fluids
- e. Antibiotics

Ans. The key is C. Exploratory surgery. [To exclude torsion].

221. A 47 yo ex-soldier suffers from low mood and anxiety. He can't forget the images he faces before and has always had flashbacks. He is not able to watch the news because there are usually some reports about war. What is he suffering from?

- a. Depression
- b. PTSD
- c. Panic attack
- d. Agoraphobia
- e. GAD

Ans. The key is B. PTSD. [repeated flashbacks and tendency to avoid the thoughts of stressor is diagnostic of PTSD].

222. A 36 yo woman has recently spent a lot of money on buying clothes. She goes out almost every night with her friends. She believes that she knows better than her friends, so she should choose the restaurant for eating out. She gave hx of having low mood at 12 yo. What's the dx?

- a. Mania
- b. Depression
- c. Bipolar affective disorder
- d. Borderline personality disorder
- e. Dysthymia

Ans. The key is C. Bipolar affective disorder. [Initial depressive episode (may be before a long) followed by mania is bipolar affective disorder].

223. A 28 yo female presents with a 3m hx of diarrhea. She complains of abdominal discomfort and passing stool 20x/day. Exam=febrile. Barium enema shows cobblestone mucosa. What is the most likely dx?

- a. Ameoba
- b. Colon Ca
- c. GE
- d. CD
- e. UC

Ans. The key is D. CD. [Hx of diarrhea, abdominal discomfort, and patient being febrile indicate gut inflammation and cobblestone appearance on barium enema is suggestive of CD].

224. A child is brought in with high grade fever, runny nose and bark-like cough. He is also drooling. What is the most appropriate tx for this child?

- a. Corticosteroids
- b. Paracetamol
- c. Adrenaline nebulizer
- d. IV antibiotics
- e. Intubation under GA

Ans. The key is E. Intubation under GA. This is a wrong key! In epiglottitis there is no cough and bark like cough is diagnostic of croup! So the correct key should be a. Corticosteroids. [high fever, bark-like cough in a child suggest croup which is treated with corticosteroids. Drooling is sign of epiglottitis which may be a bad recall here].

225. A 78yo lady on warfarin for atrial fibrillation lives in a care home. She presents with hx of progressive confusion for three days. She was also noticed to have bruises on her arms. INR = 7. What is the most probable dx?

- a. Alzheimers
- b. Delirium
- c. Subdural hemorrhage
- d. Vascular dementia
- e. Pick's dementia

Ans. The key is C. Subdural haemorrhage. [Age 78 yrs, living in a care home where unnoticed trivial injury is possible (like fall), warfarine and high INR is potential risk factor of subdural haemorrhage suggested by bruises on arms also].

226. A 28 yo drug user presents to the ED with collapse and anuria. His serum K⁺ = 7.5mmol/L. CXR = early pulmonary edema. What is the next appropriate management?

- a. Urgent hemodialysis
- b. IV calcium gluconate
- c. IV insulin + dextrose
- d. Furosemide
- e. IV NS 0.9%

Ans. The key is B. IV calcium gluconate. [IV calcium gluconate is given to protect the heart from lethal arrhythmia or cardiac arrest from high potassium level and used to buy time while definitive management is being taken. Actually calcium gluconate don't lower the potassium level that much but protect the heart from arrhythmia].

227. A 32 yo woman suffers an episode of severe occipital headache with vomiting and loss of consciousness. She is brought to the hospital where she is found to be conscious and completely alert. Exam: normal pulse & BP. No abnormal neurological signs. What is the next step in management?

- a. Admission for observation
- b. CT brain
- c. MRI head
- d. Reassurance and discharge
- e. XR skull

Ans. The key is B. CT brain. [basilar migraine can cause severe headache and LOC. But there occurs no neurological deficit and on recovering from unconsciousness becomes completely alert. But to diagnose basilar migraine there should at least history of two migraine attacks with aura. As here diagnostic criteria of basilar migraine is not fulfilled we can not discharge the patient without neuroimaging like CT or MRI].

228. A 25 yo woman was brought to the ED by her boyfriend. She has many superficial lacerations on her forearm. She is so distressed and constantly says her boyfriend is going to end the relationship. She denies trying to end her life. What is the most likely dx?

- a. Acute psychosis
- b. Severe depression
- c. Psychotic depression
- d. Borderline personality disorder
- e. Schizophrenia

Ans. The key is D. Borderline personality disorder. [Borderline personality disorder: Act impulsively and develop intense but short-lived emotional attachment to others. They are usually attention seekers but not suicidal].

229. A young woman was brought to the hospital. On exam she has low temperature and tremor. She says when she closes her eyes, she can see colors. What drug has been used?

- a. Amphetamines
- b. LSD
- c. Cocaine
- d. Heroin
- e. Ecstasy

Ans. The key is B. LSD.

230. A lady comes in severe liver disease and hematemesis. Her INR is >10. What should she be given?

- a. FFP
- b. Steroids
- c. Whole blood
- d. IV fluids
- e. Vit K

Ans. The key is A. FFP.

231. After eating a cookie at a garden party, a child began to cough and went blue. The mother also noticed that there were swollen patches on the skin. What is the initial management?

- a. OTC antihistamine
- b. Oxygen
- c. Bronchodilators
- d. Epinephrine IM
- e. Nebulized epinephrine

Ans. The key is D. Epinephrine IM [anaphylaxis with partially blocked airway].

232. A 63 yo female is noted to have left pupil unresponsive to light and is dilated. What is the most probable dx?

- a. Pontine hemorrhage
- b. Subdural hemorrhage
- c. Cerebellar hemorrhage
- d. Extradural hemorrhage
- e. Subarachnoid hemorrhage

Ans. The key is D. Extradural hemorrhage. This is a wrong key! Correct key is B. Subdural hemorrhage.

233. A 28yo business executive presents at the GP asking for some help because she has been arguing with her boyfriend frequently. She is worried about her weight, and she thinks she may be fat. She has been on a diet and lost 7 kgs in the last 2 months on purpose. She is eating less. She used to do a lot of exercise. Now she says she's feeling down, has some insomnia and feels tired and without energy. She has not showed up at work. She is worried because recently she got a loan to buy a luxury car. She can't be fired. She complains about her low mood. She thinks this is weird because she used to be extremely productive. She used to work showing an excellent performance at the office. She even received compliments from her boss. Now, she says her boyfriend is angry because her apartment is a chaos. Usually she spends a lot of time cleaning it, even upto 3 AM. She liked it to be perfect, but now it's a mess. On exam: BMI=23, no other signs. What is the most probable dx?

- a. Anorexia nervosa
- b. Bipolar disorder
- c. Binge eating disorder
- d. Hyperthyroidism
- e. Schizophrenia

Ans. The key is B. Bipolar disorder. [Now she is depressed but before hypomanic which makes the likely dx of bipolar disorder].

234. A woman brought her husband saying she wants the 'thing' on his forehead removed. The husband is refusing tx saying it improves his thinking. What is the most appropriate next step?

- a. Assess his mental capacity to refuse tx
- b. Remove lesion
- c. Refer to ED
- d. Mini-mental state exam
- e. Refuse surgery and send pt back

Ans. The key is A. Assess his mental capacity to refuse treatment.

235. A 37 yo man who has many convictions and has been imprisoned many times has a hx of many unsuccessful relationships. He has 2 boys but doesn't contact them. What is the most probable dx?

- a. Borderline personality disorder
- b. Schizophrenia
- c. Avoidant personality disorder
- d. Histrionic personality disorder
- e. Antisocial behavior disorder

Ans. The key is E. Antisocial behavior disorder. [Antisocial personality disorder is a particularly challenging type of personality disorder, characterised by impulsive, irresponsible and often criminal behavior].

236. A 60 yo man has a pathological rib fx. He also complains of recurrent infection. BMA is done. Labs: Ca²⁺ = 3.9mmol/L and ALP = 127u/L. What type of cell would be found in abundance in the marrow smear?

- a. Plasma cell
- b. Myeloid cell
- c. Bence-jones protein
- d. Megakaryocytes
- e. Reticulocytes

Q. 1. What is the key.

Q. 2. What is the diagnosis?

Q. 3. What are the points in favour of diagnosis?

Ans. 1. The key is A. Plasma cell.

Ans. 2. The diagnosis is multiple myeloma.

Ans. 3. Points in favour: i) age 60 yrs ii) pathological rib fracture (from metastases) iii) recurrent infection (due to B cell dysfunction (manifested as hypogammaglobulinemia), numerical and functional abnormalities of T cells, and dysfunction of natural killer cells), iv) raised calcium level.

237. A child presents with blue marks on the sclera, short stature and heart murmur. What is the dx?

- a. Osteogenesis imperfecta
- b. Hypopituitarism
- c. VSD
- d. Achondroplasia
- e. Dwarfism

Ans. The key is A. Osteogenesis imperfecta.

238. A 5month child can't speak but makes sounds. She can hold things with palm, not fingers. Can't sit independently but can hold her hand and sit when propped up against pillows. How's the child's development?

- a. Normal
- b. Delayed speech
- c. Delayed sitting
- d. Delayed motor development

Ans. The key is A. normal

239. A 27 yo woman has hit her neck in an RTA without complains of tingling or motor loss. What is the next most appropriate inv?

- a. MRI
- b. XR
- c. CT cervical
- d. Diagonal XR

Ans. The key is B. X-ray. [As there is no neurological deficit we can exclude any fracture by x-ray first]. [Diagonal x ray means ,oblique view of cervical spine. By this view we can assess facet joint arthropathy. This doesn't related to RTA].

240. A young female who has many superficial lacerations was brought into the ED by her boyfriend for superficially lashing her upper arm. She is adamant and screaming that she is not suicidal but scared her boyfriend wants to leave her. What is the dx?

- a. Acute psychosis
- b. Severe depression
- c. Obsessive
- d. Bipolar
- e. Borderline personality
- f. Schizophrenia

Ans. The key is acute psychosis. Probably this is wrong key! Correct key should be E. Borderline personality disorder. [Borderline personality disorder (BPD), also known as emotionally unstable personality disorder, is a long term pattern of abnormal behavior characterized by unstable relationships with other people, unstable sense of self, and unstable emotions.[3][4] There is often an extreme fear of abandonment, frequent dangerous behavior, a feeling of emptiness, and self-harm].

241. A 22yo woman was brought by her boyfriend with multiple superficial lacerations. There are scars of old cuts on her forearms. She is distressed because he wants to end the relationship. She denies suicide. What is the most likely dx?

- a. Acute psychosis
- b. Borderline personality disorder
- c. Severe depression
- d. Schizoid personality
- e. Psychotic depression

Ans. The key is B. Borderline personality. [Borderline personality disorder (BPD), also known as emotionally unstable personality disorder, is a long term pattern of abnormal behavior characterized by unstable relationships with other people, unstable sense of self, and unstable emotions.[3][4] There is often an extreme fear of abandonment, frequent dangerous behavior, a feeling of emptiness, and self-harm].

242. A 31yo single man lives with his mother. He usually drives to work. He always thinks when the traffic lights change, his mother is calling him, so he drives back home. What is the dx?

- a. OCD
- b. GAD
- c. Schizophrenia
- d. Bipolar
- e. Cyclothymia

Ans. The key is C. Schizophrenia. [delusion of reference - he thinks that the changing traffic lights are giving message to him].

243. A 56yo woman is known case of pernicious anemia. She refuses to take hydroxycobalamin IM as she is needle shy. She asks for oral medication. Why will oral meds be not effective?

- a. Intrinsic factor def
- b. Malabsorption
- c. Irritated gastric mucosa
- d. Lack of gastric acidity

Ans. The key is A. Intrinsic factor def. [Vitamin B12 cannot be absorbed without intrinsic factor].

244. An 11m baby had an apnea event. The parents are worried that if something like this happens in the future, how they are to deal. Advise them about infant CPR.

- a. Index and middle finger compression
- b. Compression with palm of one hand
- c. Compression with palm of two hands
- d. Compression with rescue breaths 30:2
- e. Compression with rescue breaths 15:2

Ans. The key is A. Index and middle finger compression.

245. A teacher brings in a child who says she fell down after hitting a table. On probing further, you decide that it was most probably an absence seizure. What led you to this dx?

- a. The child had not eaten since morning
- b. The child suddenly went blank and there was up-rolling of eyes
- c. The child started moving his fingers uncontrollably before he fell
- d. The child's body became rigid and then started to jerk

Ans. The key is B. The child suddenly went blank and there was up-rolling of eyes.

246. A man has discharge from his left ear after a fight. Where is the discharge coming from?

- a. CSF
- b. Inner ear
- c. Outer ear
- d. Brain

Ans. The key is A. CSF. [probable fracture base of skull].

247. A 40 yo manic depressive is noted to have high serum levels of lithium and profound hypokalemia. His GP had started him on anti-HTNs. Choose the single most likely cause?

- a. Verapamil
- b. Amiodarone
- c. Ranitidine
- d. Lithium
- e. Thiazide

Ans. The key is E. Thiazide. [Thiazide was prescribed for Hpt and when lithium was prescribed its level increased due to thiazide and thiazide also caused hypokalemia resulting the given picture].

248. A 74yo man presents with weakness in his arm and leg from which he recovered within a few days and short term memory loss. He has an extensor plantar response. He has similar episodes 2 years ago and became unable to identify objects and to make proper judgment. What is the most appropriate dx?

- a. Alcoholic dementia
- b. Pick's dementia
- c. Huntington's disease
- d. Alzheimer's disease
- e. Vascular dementia

Ans. The key is E. Vascular dementia. [hemiparesis, memory impairment, extensor planter reflex, inability to identify objects, poor judgment are features of strokes and thus vascular dementia].

249. A nurse comes to you saying that she has recently developed the habit of washing her hands after every 15-20 mins. She is unable to conc on her work and takes longer than before to finish tasks as she must constantly wash her hands. What is the most appropriate management?

- a. CBT
- b. SSRI
- c. ECT
- d. Antipsychotics
- e. Desensitization

Q.1. What is the key?

Q.2. What is the diagnosis?

Ans. 1. The key is A. CBT.

Ans. 2. The diagnosis is OCD.

250. A 61yo man underwent a surgery in which ileal resection had been done. He complains of fatigue, headache, and heart racing. Labs: MCV=108fL, Hgb=8.9g/dL. What is the most likely dx?

- a. Vit B12 def
- b. Iron def
- c. Folate def
- d. Hemolytic anemia
- e. Anemia of chronic disease

Q. 1. What is the key?

Q. 2. What are the points in favour?

Ans. 1. The key is Vit. B12 deficiency.

Ans. 2. Vit B12 is absorbed mostly in ileum. [As ileal resection is done B12 is not absorbed leading to megaloblastic anaemia].

251. A 7yo is brought by his mother who says that he was well at birth but has been suffering from repeated chest and GI infections since then. She also says that he is not growing well for this age. What is the likely condition of this child?

- a. CF
- b. SCID
- c. Primary Tcell immunodeficiency
- d. Primary Bcell immunodeficiency
- e. Malabsorption

Q. 1. What is the key?

Q. 2. What are the points in favour?

Ans. 1. The key is A. cystic fibrosis.

Ans. 2. CF involved in production of sweat, respiratory mucous, digestive fluid and mucous. These secretion becomes thick than normal predisposing to lung and GI infections since birth.

252. A 3yo child has a high temp for 4 days and he had not seen a doctor. Then mother notices rashes on buccal mucosa and some around the mouth. What is the most appropriate dx?

- a. Measles
- b. Roseola infectiosum
- c. Rubella
- d. Chicken pox
- e. Impetigo

Ans. The key is B. Roseola infectiosum. It is a wrong key! The correct key should be A. Measles! [Rash on buccal mucosa (koplicks spot) are characteristic of measles. Also as the rash developed after 4 days fever the dx is measles!].

Day of appearance of rash :

Measles (or rubeola - Day1) met scarlet (scarlet fever - day 2) . They went to Germany (german measles - rubella - day 3) . Had a baby called Roseola (roseola infantum - day 4) . She was naughty and so was "slapped on the cheek" (slapped cheek disease or erythema infectiosum or fifth disease- Day 5)

Rashes: time of appearance after fever onset

"Really Sick Children Must Take No Exercise":-

Number of days after fever onset that a rash will appear:

1 Day: Rubella

2 Days: Scarlet fever/ Smallpox

3 Days: Chickenpox

4 Days: Measles (and see the Koplik spots one day prior to rash)

5 Days: Typhus & rickettsia (this is variable)

6 Days: Nothing

7 Days: Enteric fever (salmonella)

253. A 70yo lady presents with fever for 3d and confusion. There is no significant PMH. What is the most probable dx?

- a. Delirium
- b. Hypoglycemia
- c. Alzheimers
- d. DKA

Ans. The key is A. Delirium. Delirium is an acute confusional state and declined cognitive function which involves changes in arousal (hyper-active, hypoactive or mixed), perceptual deficits, altered sleep-wake cycle, and psychotic features such as hallucinations and delusions.

254. An obese mother suffers from OSAS. Which of the following inv is best for her?

- a. ABC
- b. Overnight pulse-oximetry
- c. Polysomnography
- d. EEG

Ans. The key is B. Overnight pulse-oximetry. [It is already a diagnosed case of OSAS. So no need for reconfirmation with polysomnography. If like to know the current status or monitor overnight pulse oximetry is good].

255. A 28yo business man came to the sexual clinic. He was worried that he has HIV infection. 3 HIV tests were done and all the results are negative. After a few months, he comes back again and claims that he has HIV. What is the dx?

- a. Somatization
- b. Hypochondriac
- c. Manic-depressive
- d. OCD
- e. Schizophrenia

Ans. The key is B. Hypochondriac. [Worry about having a serious illness].

256. A 6wk child presents with progressive cyanosis, poor feeding, tachypnea over the first 2 wks of life and holosystolic murmur. What is the most appropriate condition?

- a. ASD
- b. VSD
- c. Tricuspid atresia
- d. PDA
- e. TOF

Q. 1. What is the key?

Q. 2. What are the points in favour?

Ans. 1. The key is E. Tetralogy of Fallot. It is a wrong key!! Correct answer is C. tricuspid atresia.

Ans. 2. Points in favour: i) tachypnoea over first 2 wks of life ii) progressive cyanosis iii) poor feeding iv) holosystolic murmur of VSD.

257. A 29yo woman who was dx to have migraine presents with severe onset of occipital headache. She lost her consciousness. CT=normal. Neurological exam=normal. What is the most appropriate management?

- a. Repeat CT
- b. MRI
- c. LP
- d. XR
- e. No inv required

Q. 1. What is the key?

Q. 2. What is the diagnosis?

Q. 3. What are the points in favour?

Ans. 1. The key is E. No investigation required.

Ans. 2. The diagnosis is basilar migraine.

Ans. 3. Points in favour i) history of migraine ii) severe occipital headache iii) LOC iv) CT normal v) neurological examination is normal.

258. A 19yo man has been happier and more positive than usual, with more energy than he has ever felt before for no particular reason. He has been getting more work done at the office today and has been socializing with his friends as usual. What is the most likely dx?

- a. Atypical depression
- b. Marked depression
- c. Bipolar syndrome
- d. Psychosis
- e. Hypomania

Q. 1. What is the key?

Q. 2. What are the points in favour of this diagnosis?

Ans. 1. The key is E. Hypomania.

Ans. 2. i) elevated mood ii) more energy than before iii) getting more work done at the office (loss of inhibition). These features are common for both mania and hypomania!! Then why it is not mania? It is not mania as in mania you will get psychotic symptoms like i) delusion of grandeur ii) auditory hallucinations, which are absent here!

259. A 35yo female attempts suicide 10x. There is no hx of psychiatric problems and all neurological exams are normal. What is the best tx?

- a. Problem focused tx
- b. CBT
- c. Antipsychotic
- d. Antidepressant
- e. ECT

Ans. The key is A. Problem focused tx. [patient is not psychotic and with normal neurology! So she may getting some problem in family life, finance, job or somewhere like this which she is not able to cope with and that is leading to her suicidal thoughts].

260. A 57yo man presents with weight loss, tiredness, fever and abdominal discomfort. Exam: spleen palpable up to the umbilicus. Labs: WBC=127, Hgb=8.7, Plt=138. What is the most likely dx?

- a. CML
- b. AML
- c. CLL
- d. APL
- e. Polycythemia

Q. 1. What is the key?

Q. 2. Why it is so diagnosed?

Ans. 1. The key is A. CML.

Ans. 2. Points in favour of CML: i) Age 57 years ii) weight loss iii) abdominal discomfort iv) anaemia v) fever vi) marked splenomegaly.

261. A baby born at 34 weeks with a heart murmur is kept in the incubator for almost 4 weeks. There is no murmur at discharge. What is the likely cause of this murmur?

- a. PDA
- b. TOF
- c. Aneurysm of sinus of Valsalva
- d. Aorto-pulmonary septal defect
- e. AVM

Q. 1. What is the key?

Q. 2. Why it was present in this baby?

Q. 3. If it is present after birth what is the management?

Ans. 1. The key is A. PDA.

Ans. 2. As it is more common in premature baby!

Ans. 3. Management:

· indomethacin closes the connection in the majority of cases

· if associated with another congenital heart defect amenable to surgery then prostaglandin E1 is useful to keep the duct open until after surgical repair.

262. A 6yo girl who has previously been well presented with a hx of tonic-clonic seizures lasting 4mins. Her mother brought her to the hospital and she appeared well. She is afebrile and didn't lose consciousness during the episode of seizure. She has no neurologic deficit. What is the most appropriate inv for her?

- a. ABG
- b. Serum electrolytes
- c. ECG
- d. Blood glucose

Q. 1. What is the key?

Q. 2. What are the points in favour?

Ans. 1. The key is B. Serum electrolyte.

Ans. 2. In epilepsy patient becomes unconscious. The child has no previous illness and she was conscious during the episode of seizure. So electrolyte imbalance may be the cause.

263. A 60yo woman was found by her son. She was confused and had urinary incontinence. She has recovered fully after 6h with no neurological complaints. What is the most likely dx?

- a. Stroke
- b. Vestibular insufficiency
- c. TIA
- d. Intracranial hemorrhage

Ans. The key is C. TIA.

264. A 34yo woman presents 3 weeks after childbirth. She has had very low mood and has been suffering from lack of sleep. She also has thought of harming her little baby. What is the most appropriate management for this pt?

- a. ECT
- b. CBT
- c. IV haloperidol
- d. Paroxetine
- e. Amitriptyline

Ans. The key is A. ECT. This is wrong key! Correct key is C. IV haloperidol. [Dx is postpartum psychosis. Patient.info, Wikipedia says antipsychotic and if needed additional mood stabilizer may be used as 1st line. NHS says antidepressant, antipsychotic and mood stabilizer (any one or in combination) as 1st line treatment. As antipsychotic has given priority likely correct answer is C. IV haloperidol. 2nd line is CBT, and last resort is ECT].

265. A 65yo woman presents with headache. She also complains of dizziness and tinnitus. She has Recently realized she has visual problems. There is hx of burning sensation in fingers and toes. On exam: splenomegaly, itchy after hot bath. Labs: RBC=87, Hgb=31.9, Plt=796. What is the dx?

- a. CML
- b. CLL
- c. Polycythemia vera
- d. Myelofibrosis
- e. NHL

Q. 1. What is the key?

Q. 2. What are the points in favour?

Ans. 1. The key is C. Polycythemia vera.

Ans. 2. Points in favour: i) hyperviscosity symptoms (headache, dizziness, tinnitus, visual problem) ii) pruritus, typically after a hot bath, iii) splenomegaly iv) RBC=87, Hb=31.9, Plt=796.

266. A 29yo male brought to ED in unconscious state. There is no significant past hx. Which of the following should be done as the initial inv?

- a. CT
- b. Blood glucose
- c. ABG
- d. MRI
- e. CBC

Ans. The key is B. Blood glucose.

267. A 45yo woman comes with red, swollen and exudating ulcer on the nipple and areola of right breast with palpable lump under the ulcer. What do you think is causing this skin condition?

- a. Inflammatory cells releasing cytokines
- b. Infiltration of the lymphatics by the carcinomatous cells
- c. Infiltration of the malignant skin cells to the breast tissue

Ans. The key is B. Infiltration of the lymphatics by the carcinomatous cells.

268. A 20yo young lady comes to the GP for advice regarding cervical ca. she is worried as her mother past away because of this. She would like to know what is the best method of contraception in her case?

- a. POP
- b. Barrier method
- c. IUCD
- d. COCP
- e. IUS

Ans. The key is A. POP. Probably wrong key! Correct key should be B. Barrier method! [spermatozoa itself acts as a carcinogen!!! So barrier method is the best protection from the given option!!].

269. A 66yo man, an hour after hemicolectomy has an urine output of 40ml. However, an hour after that, no urine seemed to be draining from the catheter. What is the most appropriate next step?

- a. IV fluids
- b. Blood transfusion
- c. Dialysis
- d. IV furosemide
- e. Check catheter

Ans. The key is E. Check catheter.

270. A 24yo pt presented with anaphylactic shock. What would be the dose of adrenaline?

- a. 0.5ml of 1:1000
- b. 0.5ml of 1:10000
- c. 1ml of 1:500
- d. 5ml of 1:1000
- e. 0.05ml of 1:100

Ans the key is A. 0.5 ml of 1:1000. [in cardiac arrest 1 ml of 1:1000 iv].

271. A 44yo woman complains of heavy bleeding per vagina. Transvaginal US was done and normal. Which of the following would be the most appropriate inv for her?

- a. Hysterectomy
- b. Endometrial biopsy
- c. CBC
- d. High vaginal swab
- e. Coagulation profile

Ans. The key is E. Coagulation profile. [Transvaginal US is normal i.e. no endometrial hyperplasia, no fibroid or obvious cause for heavy bleeding was found. So now most appropriate investigation should be coagulation profile].

272. A 60yo woman presented to OPD with dysphagia. No hx of weight loss or heartburn. No change in bowel habits. While doing endoscopy there is some difficulty passing through the LES, but no other abnormality is noted. What is the single most useful inv?

- a. CXR
- b. MRI
- c. Esophageal biopsy
- d. Esophageal manometry
- e. Abdominal XR

- Q. 1.** What is the key?
- Q. 2.** What is the diagnosis?
- Q. 3.** What is the treatment.

Ans. 1. The key is D. Oesophageal manometry.

Ans. 2. Achalasia cardia

Ans. 3. i) Oral medication: Nitrates or CCB ii) Balloon dilatation of the spincter iii) Oesophagomyotomy.

273. A 24yo woman presents with deep dyspareunia and severe pain in every cycle. What is the initial inv?

- a. Laparoscopy
- b. Pelvic US
- c. Hysteroscopy
- d. Vaginal Swab

- Q. 1.** What is the key?
- Q. 2.** What is the likely diagnosis?
- Q. 3** What is the treatment?

Ans. 1. The key is B. Pelvic US.

Ans. 2. The likely diagnosis is endometriosis.

Ans. 3. Treatment: There is no cure for endometriosis, but a number of treatments may improve symptoms. This may include pain medication [NSAIDs such as naproxen], hormonal treatments [COCP, or mirena], or surgery [Surgical removal of endometriosis when other measures fail].

274. A 38yo woman, 10d postpartum presents to the GP with hx of passing blood clots per vagina since yesterday. Exam: BP=90/40mmhg, pulse=110bpm, temp=38C, uterus tender on palpation and fundus 2cm above umbilicus, blood clots +++. Choose the single most likely dx/

- a. Abruptio of placenta 2nd to pre-eclampsia
- b. Concealed hemorrhage
- c. Primary PPH
- d. Secondary PPH
- e. Retained placenta
- f. Scabies

Q. 1. What is the key?

Q. 2. How the condition is defined?

Ans. 1. The key is D. Secondary PPH.

Ans. 2. Secondary PPH: Secondary PPH is defined as abnormal or excessive bleeding from the birth canal between 24 hours and 12 weeks postnatally. [www.rcog.org.uk/en/guidelines-research-services/guidelines/gtg52/].

275. A 32yo female with 3 prv 1st trimester miscarriages is dx with antiphospholipid syndrome. Anticardiolipin antibodies +ve. She is now 18wks pregnant. What would be the most appropriate management?

- a. Aspirin
- b. Aspirin & warfarin
- c. Aspirin & heparin
- d. Heparin only
- e. Warfarin only

Ans. The key is C. Aspirin & heparin.

276. A 23yo presents with vomiting, nausea and dizziness. She says her menstrual period has been delayed 4 weeks as she was stressed recently. There are no symptoms present. What is the next appropriate management?

- a. Refer to OP psychiatry
- b. Refer to OP ENT
- c. CT brain
- d. Dipstick for B-hCG
- e. MRI brain

Q. 1. What is the key?

Q. 2. What is the likely diagnosis?

Ans. 1. The key is D. Dipstick for B-hCG.

Ans. 2. Likely diagnosis is pregnancy. [Features like vomiting, nausea and dizziness are consistent with early pregnancy supported by delayed menstruation].

277. A 16yo girl came to the sexual clinic. She complains of painful and heavy bleeding. She says she doesn't a regular cycle. What is the most appropriate management?

- a. Mini pill
- b. Combined pill
- c. IUS
- d. Anti-prostoglandins
- e. Anti-fibrinolytics

Ans. The key is B. Combined pill.

278. A 36yo man walks into a bank and demands money claiming he owns the bank. On being denied, he goes to the police station to report this. What kind of delusions is he suffering from?

- a. Delusion of reference
- b. Delusion of control
- c. Delusion of guilt
- d. Delusion of persecution
- e. Delusion of grandeur

Ans. The key is E. Delusion of grandeur.

279. Which method of contraception can cause the risk of ectopic pregnancy?

- a. COCP
- b. IUCD
- c. Mirena
- d. POP

Ans. The key is B. IUCD.

280. A woman has pernicious anemia. She has been prescribed parenteral vitamin B12 tx but she is needle phobic. Why is oral tx not preferred for this pt?

- a. IM B12 is absorbed more
- b. Intrinsic factor deficiency affects oral B12 utilization
- c. IM B12 acts faster
- d. IM B12 needs lower dosage
- e. Pernicious anemia has swallowing difficulties

Ans. The key is B. Intrinsic factor deficiency affects oral B12 utilization.

281. An old man comes to the doctor complaining that a part of this body is rotten and he wants it removed. What is the most likely dx?

- a. Guilt
- b. Hypochondriasis
- c. Munchausen's
- d. Nihilism
- e. Capgras syndrome

Ans. The key is D. Nihilism. [nihilism (medical term is nihilistic delusion): parts of the body do not exist or are dead]

Guilt: an emotion that occurs when a person feels that they have violated a moral standard.

Hypochondriasis: worry about having a serious illness.

Munchausen's: a [psychiatric factitious disorder](#) wherein those affected feign [disease](#), illness, or psychological trauma to draw [attention, sympathy](#), or reassurance to themselves.

Capgras syndrome: a [delusion](#) that a friend, spouse, parent, or other close family member (or pet) has been replaced by an identical-looking [impostor](#).

282. A 31yo woman who is 32weeks pregnant attends the antenatal clinic. Labs: Hgb=10.7, MCV=91. What is the most appropriate management for this pt?

- a. Folate supplement
- b. Ferrous sulphate 200mg/d PO
- c. Iron dextran
- d. No tx req

Ans. The key is D. No tx required. [According to NICE, cut offs for iron supplements: at booking (8-10 weeks)- if less than 11 at 28 weeks and further- if less than 10.5 if less than these values=> give iron].

283. A 47yo man who is a chronic alcoholic with established liver damage, has been brought to the hospital after an episode of heavy drinking. His is not able to walk straight and is complaining of double vision and is shouting obscenities and expletives. What is the most likely dx?

- a. Korsakoff psychosis
- b. Delirium tremens
- c. Wernickes encephalopathy
- d. Tourettes syndrome
- e. Alcohol dependence

Ans. The key is C. Wernicke's encephalopathy. [triad of i) ophthalmo-

plegia, ii) ataxia iii) confusion].

284. A 32yo woman of 39wks gestation attends the antenatal day unit feeling very unwell with sudden onset of epigastric pain a/w nausea and vomiting. Temp 36.7C. Exam: RUQ tenderness. Bloods: mild anemia, low plts, elevated LFT and hemolysis. What is the most likely dx?

- a. Acute fatty liver of pregnancy
- b. Acute pyelonephritis
- c. Cholecystitis
- d. HELLP syndrome
- e. Acute hepatitis

Ans. The key is D. HELLP syndrome. [H=hemolysis, EL=elevated liver enzyme, LP=low platelet count].

285. A 57yo woman presents with dysuria, frequency and urinary incontinence. She complains of dyspareunia. Urine culture has been done and is sterile. What is the most appropriate step?

- a. Oral antibiotics
- b. Topical antibiotics
- c. Topical estrogen
- d. Oral estrogen
- e. Oral antibiotics and topical estrogen

Ans. The key is C. Topical estrogen. [There may be UTI like symptoms and dyspareunia in atrophic vaginitis for which topical oestrogen can be used].

286. A pt came to the ED with severe lower abdominal pain. Vitals: BP=125/85mmHg, Temp=38.9C. Exam: abdomen rigid, very uncomfortable during par vaginal. She gave a past hx of PID 3 years ago which was successfully treated with antibiotics. What is the appropriate inv?

- a. US
- b. Abdomen XR
- c. CT
- d. High vaginal
- e. Endocervical swab

Ans. The key is A. US. [Patient had previous PID. Current symptoms of severe cervical motion tenderness with significant rise of temperature is very much suggestive of pelvic abscess].

287. A pregnant woman with longterm hx of osteoarthritis came to the antenatal clinic with complaints of restricted joint movement and severe pain in her affected joints. What is the choice of drug?

- a. Paracetamol
- b. Steroid
- c. NSAID
- d. Paracetamol+dihydrocoiene
- e. Pethadine

Ans. The key is A. Paracetamol.

288. A 24yo 18wk pregnant lady presents with pain in her lower abdomen for the last 24h. She had painless vaginal bleeding. Exam: abdomen is tender, os is closed. What is the most probable dx?

- a. Threatened miscarriage
- b. Inevitable miscarriage
- c. Incomplete miscarriage
- d. Missed miscarriage
- e. Spontaneous miscarriage

Ans. The key is A. Threatened miscarriage. [gestational age 18 weeks, lower abdominal pain, tender abdomen, closed os and painless vaginal bleeding indicates threatened abortion].

289. A 2yo child playing in the garden had a clean cut. She didn't have any vaccinations. Also, there is no contraindication to vaccinations. Parents were worried about the vaccine side effects. What will you give?

- a. Clean the wound and dress it
- b. Give TT only
- c. Give DPT only
- d. Give DPT and tetanus lg
- e. Give complete DPT vaccine course

Ans. The key is E. Give complete DPT vaccine course.

290. A 32yo female who has had 3 prv miscarriages in the 1st trimester now comes with vaginal bleeding at 8wks. US reveals a viable fetus. What would be the most appropriate definitive management?

- a. Admit
- b. Aspirin
- c. Bed rest 2 weeks
- d. Cervical cerclage
- e. No tx

Ans. The key is B. Aspirin. [Early miscarriage is more common in antiphospholipid syndrome and treated with heparin or aspirin when become pregnant].

291. A 6yo girl started wetting herself up to 6x/day. What is the most appropriate tx?

- a. Sleep alarms
- b. Desmopressin
- c. Reassure
- d. Behavior training
- e. Imipramine

Ans. The given key is B. Desmopressin. This is wrong key. Correct key is D. Behavioral training. [This is not nocturnal enuresis but diurnal enuresis. In diurnal enuresis Desmopressin is not recommended. Behavioral training is mainstay of treatment in diurnal enuresis].

292. A 27yo 34wk pregnant lady presents with headache, epigastric pain and vomiting. Exam: pulse=115, BP=145/95mmHg, proteinuria ++. She complains of visual disturbance. What is the best medication for the tx of the BP?

- a. 4g MgSO₄ in 100ml 0.9%NS in 5mins
- b. 2g MgSO₄ IV bolus
- c. 5mg hydralazine IV
- d. Methyldopa 500mg/8h PO
- e. No tx

Ans. The given key is A. 4g MgSO₄ in 100ml 0.9%NS in 5mins. It is a wrong key. Correct key is E. No tx. [Here, question specifically asked for tx of BP. In case of BP of 145/95 mmHg no treatment for BP is needed. Ref: NICE guideline].

293. A 24yo lady who is 37wk pregnant was brought to the ED. Her husband says a few hours ago she complained of headache, visual disturbance and abdominal pain. On arrival at the ED she has a fit. What is the next appropriate management for this pt?

- a. 4g MgSO₄ in 100ml 0.9%NS in 5mins
- b. 2g MgSO₄ IV bolus
- c. 2g MgSO₄ in 500ml NS in 1h
- d. 4g MgSO₄ IV bolus
- e. 10mg diazepam in 500ml 0.9%NS in 1h

Ans. The key is A. 4g MgSO₄ in 100ml 0.9%NS in 5mins [NICE]. [Dx is eclampsia].

294. What is the pathological change in Barret's esophagitis?

- a. Squamous to columnar epithelium
- b. Columnar to squamous epithelium
- c. Dysplasia
- d. Metaplasia

e. Hyperplasia

Ans. The key is A. Squamous to columnar epithelium. [Both A and D are correct answer as Barrett's oesophagus is a change known as metaplasia].

295. A 34yo male presents with hx of headache presents with ataxia, nystagmus and vertigo. Where is the site of the lesion?

- a. Auditory canal
- b. 8th CN
- c. Cerebellum
- d. Cerebral hemisphere
- e. Brain stem

Ans. The key is C. Cerebellum. [Features described are consistent with cerebellar lesion].

296. A 24yo girl comes to the woman sexual clinic and seeks advice for contraception. She is on sodium valproate.

- a. She can't use COCP
- b. She can use COCP with extra precaution
- c. She can use COCP if anticonvulsant is changed to carbamazepin.
- d. She can use COCP with estrogen 50ug and progesterone higher dose
- e. She can use COCP

Ans. The key is E. She can use COCP. [sodium valproate has no effect on COCP].

297. A 27yo lady came to the ED 10 days ago with fever, suprapubic tenderness and vaginal discharge. PID was dx. She has been on the antibiotics for the last 10days. She presents again with lower abdominal pain. Temp=39.5C. what is the most appropriate next management?

- a. Vaginal swab
- b. Endocervical swab
- c. US
- d. Abdominal XR
- e. Laparoscopy

Ans. The key is C. US. [Initial presentation was of PID. But recurrence of symptoms suggests resistant condition like abscess formation].

298. An 18yo man complains of fatigue and dyspnea, he has left parasternal heave and systolic thrill with a harsh pan-systolic murmur at left parasternal edge. What is the most probable dx?

- a. TOF
- b. ASD
- c. VSD
- d. PDA
- e. TGA

Ans. The key is C. VSD.

299. A young girl presenting with fever, headache, vomiting, neck stiffness and photophobia. She has no rashes. What is the most appropriate test to confirm dx?

- a. Blood culture
- b. Blood glucose
- c. LP
- d. CXR
- e. CT

Ans. The key is C. LP. [Case of meningitis. LP will confirm the diagnosis].

300. A 65yo HTN man wakes up in the morning with slurred speech, weakness of the left half of his body and drooling. Which part of the brain is affected?

- a. Left parietal lobe
- b. Right internal capsule
- c. Right midbrain
- d. Left frontal lobe

Ans. The key is B. Right internal capsule. [As symptoms are on left side lesion is on right side of the brain. So answer should be either b) right internal capsule or c) right midbrain. If it was midbrain there would have cranial nerve involvement. On the other hand given picture is very much consistent with lacunar infarction of internal capsule!]

301. A 27yo presents with abdominal pain, bleeding, vomiting and diarrhea. Her LMP was 7wks ago. Exam: abdominal tenderness, BP=90/60mmHg. What is the next appropriate management?

- a. Immediate laparotomy
- b. Laparoscopy
- c. Salpingotomy
- d. Salpingectomy
- e. MTX

- Q. 1.** What is the key?
Q. 2. What is the diagnosis?
Q. 3. Justify the key.

Ans. 1. The key is A. Immediate laparotomy.

Ans. 2. The diagnosis is ruptured ectopic pregnancy.

Ans. 3. In ruptured ectopic pregnancy if there is shock we should go for immediate laparotomy.

302. A woman presents with complains of abdominal pain, unsteadiness, numbness of lower limb and palpitations. All inv are normal. What is the dx?

- a. Manhausen
- b. Somatization
- c. Hypochondriac
- d. Bipolar

Ans. The key is B. Somatization. [This is multiple, recurrent, medically unexplained symptoms usually starting early in life. Usually patient presents with one symptom at a time. Investigations are normal].

303. A 34yo African-caribbean man with a hx of sarcoidosis has presented with bilateral kidney stones. What is the most likely cause for this pt's stones?

- a. Hypercalcemia
- b. Hyperuricemia
- c. Diet
- d. Recurrent UTIs
- e. Hyperparathyroidism

Q. 1. What is the key?

Q. 2. Why this occurs?

Ans. 1. The key is A. Hypercalcemia.

Ans. 2. Hypercalcemia in sarcoidosis is due to the uncontrolled synthesis of 1,25-dihydroxyvitamin D3 by macrophages. 1,25-dihydroxyvitamin D3 leads to an increased absorption of calcium in the intestine and to an increased resorption of calcium in the bone.

304. Which of the following is NOT a physiological change during pregnancy?

- a. Tidal volume 500ml
- b. RBC vol 1.64L
- c. Cardiac output 6.5L/min
- d. Uterus weight 1.1kg
- e. ESR up by 4x

Ans. The key is A. Tidal volume 500 ml.

305. A 10yo boy presents with nose bleed. What measure should be taken to stop the bleeding?

- a. Press base of the nose
- b. Ice packs
- c. Press soft parts of the nose
- d. Start tranexemic acid
- e. IV fluids

Ans. The key is C. Press soft parts of the nose.

306. An MI pt who is already on aspirin no longer smokes and his cholesterol, ECG, echo and BP are normal. Choose the best option for him:

- a. Give statin
- b. Give statin+warfarin
- c. Low cholesterol diet
- d. Statin+ACEi

Ans. The key is D. Statin + ACEi.

[Offer all people who have had an acute MI treatment with the following drugs:

ACE (angiotensin-converting enzyme) inhibitor dual antiplatelet therapy (aspirin plus a second antiplatelet agent) beta-blocker statin. [2007, amended 2013] [NICE guideline].

307. A 46yo man is being treated for a pleural effusion. A chest drain has been sited just below the 4th rib in the mid-axillary line on his right side. What single structure is at particular risk of injury?

- a. Arzygos vein
- b. Diaphragm
- c. Intercostal artery
- d. Internal thoracic artery
- e. Liver

Ans. The key is C. Intercostal artery. [Most vulnerable structure is intercostal nerve, then intercostal artery then intercostals vein. As intercostal nerve is not in option intercostal artery is the answer here].

308. What advice would you give for the parents of a child with repeated UTI?

- a. Surgery
- b. Prophylactic antibiotics
- c. Increase fluids
- d. Toilet training
- e. Laxatives

Ans. The given key is A. Surgery. This is a wrong key. Correct option is B. Prophylactic antibiotic. [For repeated UTI prophylactic antibiotic should be given].

309. A pt presents with complete anuria following prolonged hypotension and shock in a pt who bled profusely from a placental abruption. What is the most probable dx?

- a. Post viral infection
- b. Acute papillary necrosis
- c. Acute cortical necrosis
- d. HUS
- e. Renal vein thrombosis

Q. 1. What is the key?

Q. 2. What is the reason for this?

Ans. 1. The key is C. Acute cortical necrosis.

Ans. 2. There are 2 reasons for this acute cortical necrosis. i) significant diminished arterial perfusion of the kidneys due to spasm of the feeding artery secondary to profuse bleeding from placental abruption ii) DIC secondary to placental abruption.

310. An alcoholic 56yo man had ascetic fluid analysis done which was found to be yellow color. What is the most appropriate cause?

- a. Alcoholic hepatitis
- b. Decompensated cirrhosis
- c. TB peritonitis
- d. Pyogenic peritonitis
- e. Neoplasm

Q. 1. What is the key?

Q. 2. How this diagnosis is made?

Ans. 1. The key is B. Decompensated cirrhosis.

Ans. 2. If the patient experiences serious problems described below his disease has progressed from compensated cirrhosis to decompensated cirrhosis:

Bleeding varices (internal bleeding)

Ascites (fluid in the belly)

Encephalopathy (confusion)

Jaundice (yellowing of eyes and skin).

311. A 15yo boy presents with testicular pain for 2days. There is no hx of trauma. Exam: temp=38.5C, right hemi-scrotum tenderness. What is the single most appropriate management?

- a. Give antibiotics
- b. Give analgesia
- c. Reassure
- d. US scrotum
- e. Exploratory surgery

Q. 1. What is the key?

Q. 2. What is the diagnosis?

Q. 3. What are the points in favour?

Ans. 1. The key is A. Give antibiotics.

Ans. 2. The diagnosis is epididymo-orchitis.

Ans. 3. Points in favour: i) No history of trauma ii) testicular pain with fever points towards epididymo-orchitis.

312. A 58yo lady presented with urinary incontinence. She looks anxious for her condition. Urine culture is sterile. Her urodynamic study is normal. What is the next step?

- a. Antibiotics
- b. Topical estrogen
- c. Systemic estrogen
- d. Duloxetine
- e. Pelvic floor exercise

Ans. The key is E. Pelvic floor exercise.

313. A 45yo lady came to family planning clinic for contraception advice. She is not keen to be pregnant for the next 3yrs. Her recent US showed multiple small submucosal fibroid. What is the best method of contraception for her?

- a. Etonogestrol
- b. COCP
- c. IUS
- d. POP
- e. IUCD

Ans. The key is C. IUS. [IUS gives 3-5 yrs long contraception. It also helps to shrink the fibroid].

314. A child presents with eczema. She was given two creams by the GP - emollient and steroid. What advice would you give her regarding application of the cream?

- a. Sparingly use both the cream
- b. First use emollient, then steroid
- c. Apply steroid then emollient
- d. Mix emollient & steroid before use
- e. Emollient at night with steroid

Ans. The key is B. First use emollient, then steroid. [emollient 30 minutes before steroid].

315. All the following drugs do not cause bronchoconstriction except?

- a. Atenolol
- b. Salbutamol
- c. Salmeterol
- d. Ipratropium bromide
- e. Cocaine

Ans. The key is A. Atenolol.

316. A 28 yo female who delivered 6 weeks ago feels sad and has no interest to feeding the baby. She has been eating poorly and having difficulty sleeping. She feels weak throughout the day and has stopped taking the baby out of the house. She also says that the baby has evil eyes. What is the most likely diagnosis?

- a. Postpartum blues
- b. Postpartum depression
- c. Postpartum psychosis
- d. Schizophrenia
- e. Psychotic depression

Q. 1. What is the key?

Q. 2. What are the points in favour?

Ans. 1. The key is C. Postpartum psychosis.

Ans. 2. Points in favour: i) features of depression: feels sad, poor eating, difficulty sleep, feeling weak ii) delusional ideas: thinks baby has evil eyes and not taking the baby out of the house. These points to postpartum psychosis. [Postpartum psychosis starts within 2 wks (occasionally later) of delivery and it can take 6 -12 months or more to recover from postpartum psychosis].

317. A 44yo man presents with periorbital and pedal edema. 24h urine shows 8g of protein/d and serum cholesterol=7mmol/L. Renal biopsy results are awaited. What would be the most likely dx?

- a. Minimal change disease
- b. Glomerulonephropathy
- c. Membranous glomerulonephropathy
- d. FSGS
- e. IgA nephropathy
- f. Mesangiocapillary

Ans. The given key is C. Membranous glomerulonephritis. This is wrong key. Correct key is D. FSGS. [FSGS is most common cause of

nephrotic syndrome in adults].

318. A 53yo man presents complaining of weight loss, lethargy, increasing abdominal discomfort and gout for the past yr. Exam: spleen palpated 5cm below left costal margin, no fluid wave. CBC: Hgb=10.5g/dL, WBC=200 – 85% neutrophils, plts=100, Na+=140mmol/L, K+ 4mmol/L, creat=151umol/L, urea=7mmol/L. Serum B12 increased. Philadelphia chromosome +ve. What is the most likely dx?

- a. CML
- b. CLL
- c. AML
- d. ALL
- e. Lymphoma

Q. 1. What is the key?

Q. 2. What are points in favour of this diagnosis?

Ans. 1. The key is A. CML.

Ans. 2. Points in favour: i) wt loss ii) lethargy iii) abdominal discomfort iv) splenomegaly v) gout [Elevated uric acid and vitamin B12 levels are found in 25% of patients of CML]. A blood picture is suggestive and +ve Philadelphia chromosome is diagnostic.

319. In a group of cancer pts, 10 died that wasn't treated while 5 died in the tx group. Which statement is correct?

- a. Absolute risk =10
- b. Relative risk =10
- c. Relative risk =5
- d. Absolute risk=5
- e. Relative risk=2

Ans. Given key is E. relative risk = 2. [RR= Number of death in not treated group/number of death in treated group].

320. A 67yo woman has presented with hard, irregular, poorly defined 5cm lump in her right breast. She has a bruise on the surface and there is no discharge. What is the most likely dx?

- a. Fibroadenosis
- b. Fat necrosis
- c. Fibroadenoma
- d. Duct ectasia
- e. Ca breast

Q. 1. What is the key?

Q. 2. Please justify the key.

Ans. 1. The key is B. Fat necrosis.

Ans. 2. Fat necrosis usually occurs following trauma or surgery. Given case is a fat necrosis of breast as there is no discharge and there is a

bruise indicating prior trauma.

321. A 67yo female who had undergone a radical mastectomy now comes with the complaint of swelling and redness in her right upper limb. Involvement of which of the following structures explain these symptoms?

- a. Epitrochlear LN
- b. Cephalic vein
- c. Subclavian artery
- d. Axillary group of LN
- e. Long thoracic nerve

Ans. The key is D. Axillary group of LN. [Axillary clearance compromise lymphatic flow and may results in swelling of upper limb].

322. A 50yo smoker and heavy drinker presents with complaints of racing heart. A 24h ECG comes out normal. What is your next step in management?

- a. ECHO
- b. Reassure
- c. Stress test

Ans. The key is B. Reassure. [Smoking and alcohol excess can cause palpitation without any recognizable arrhythmia and for this no treatment is required].

323. A 47yo man comes to the GP with a swelling in his left groin which disappears on lying down. The swelling was bluish in color and felt like a bag of worms. He also complains of a mass in the left loin along with hematuria occasionally. What could be the possible dx?

- a. Left sided RCC
- b. Varicosity 2nd to liver disease
- c. Testicular tumor
- d. UTI
- e. IVC obstruction

Q. 1. What is the key?

Q. 2. What is the condition described?

Q. 3. What is the link between these two conditions?

Ans. 1. The key is A. Left sided Renal cell carcinoma.

Ans. 2. Left sided varicocele.

Ans. 3. Most common secondary cause of left sided varicocele is RCC. Newly diagnosed varicocele over the age of 40yrs are very much suggestive of RCC. Varicocele is common on left side as left testicular veins drain to the left renal vein, while the right testicular vein drain directly into IVC.

324. A man presents with muffled hearing and feeling of pressure in ear with tinnitus and vertigo. He also complains of double vision when looking to the right. What is the most appropriate dx?

- a. Meniere's disease
- b. Acoustic neuroma
- c. Acute labyrinthitis
- d. Meningioma
- e. Otosclerosis

Q. 1. What is the key?

Q. 2. Justify the key.

Ans. 1. The key is B. Acoustic neuroma.

Ans. 2. Hearing loss, feeling of pressure in the ear with tinnitus, vertigo and involvement of cranial nerve i.e. right abducent nerve are suggestive of acoustic neuroma.

325. In 85% of the population this artery is dominant. What is the single most appropriate option?

- a. Left ant descending artery
- b. Coronary sinus
- c. Circumflex artery
- d. Left main stem, post descending artery
- e. Right coronary artery

Q. 1. What is the key?

Q. 2. Justify the key.

Ans. 1. The key is E. Right coronary artery.

Ans. 2. If the posterior descending artery is supplied by the circumflex artery then it is left dominant and if posterior descending artery is supplied by the right coronary artery then it is right dominant. As in 85% of population posterior descending artery is supplied by right coronary artery it is called the dominant that is right coronary artery is dominant.

326. A 54 yo lady presents with sudden, severe pain in the left half of her skull. She also complains of pain around her jaw. What is the next likely step?

- a. CT
- b. MRI
- c. Fundoscopy
- d. ESR
- e. Temporal artery biopsy

Q. 1. What is the key?

Q. 2. What is the diagnosis?

Q. 3. What are the points in favour of your diagnosis?

Ans. 1. The key is ESR.

Ans. 2. The diagnosis is Giant cell arteritis or temporal arteritis.

Ans. 3. Points in favour: i) Age >50yrs ii) Female sex iii) Severe pain in the left half of skull iv) Pain around the jaw (jaw claudication).

327. A teenage girl who was 'fine' until her boyfriend said he didn't want the relationship anymore. She took 10 tablets of paracetamol in front of his mother after taking alcohol. What should you do?

- a. Refer to psychiatry
- b. Counselling
- c. GP to sort out family issues
- d. Return to work to relieve her anger

Ans. The key is A. Refer to psychiatry. [10 tablets of paracetamol is not a life threatening toxic dose and simultaneous drug overdose and alcohol consumption needs psychiatric evaluation].

328. A 6yo fell on outstretched hand while playing. He feels tender at the elbow but otherwise well. What is the most likely dx?

- a. Spiral fx
- b. Green stick fx
- c. Compound fx
- d. Supracondylar fx
- e. Pulled elbow

Ans. The key is B. Green stick fracture.

329. A man has a BP of 160/90mmHg, proteinuria++. KUB US are equally reduced in size with smooth borders and normal pelvic calyceal system. What is the cause of HTN in the pt?

- a. Chronic glomerulonephritis
- b. Chronic pyelonephritis
- c. Bilateral renal artery stenosis
- d. Essential HTN
- e. Polycystic kidney

Ans. The key is bilateral renal artery stenosis. This is probably a wrong key. The correct key should be A. Chronic glomerulonephritis. [In bilateral renal artery stenosis BP is very high (much more than 90/160 mmHg)].

330. A lady presents with abdominal pain, dysuria, dyspareunia and vaginal discharge. What is your next step?

- a. Laparoscopy
- b. High vaginal swab
- c. Hysteroscopy
- d. Laparotomy
- e. US

Ans. The key is B. High vaginal swab. [Probable diagnosis is PID].

331. An old lady 72yo staying at a nursing home for a few years, a known HTN on reg tx presented with sudden dysphagia while eating with drooling of saliva and req urgent inv. What would be your next step?

- a. Ba swallow
- b. Chest CT
- c. Endoscopy
- d. Laryngoscopy
- e. CXR
- f. Endoscopy with biopsy

Ans. The key is C. Endoscopy. [Probable impacted food bolus (usually meat) which can be visualized and removed with the aid of endoscopy].

332. A man presents with outward deviation of his right eye and diplopia. Which nerve is affected?

- a. Left trochlear
- b. Left oculomotor
- c. Right trochlear
- d. Right abducens
- e. Right oculomotor

Ans. The given key is B. Left oculomotor! It is wrong key! Answer should be E. Right oculomotor.

333. A 60yo pt who has had a MI a week back presents with dyspnea and pericardial rub. ECG shows ST elevation. CXR: loss of margin at costo-vertebral angle. What is the single most likely cause?

- a. Cardiac tamponade
- b. Mitral regurge
- c. Dressler's syndrome
- d. Atrial fib
- e. Emboli

Q. 1. What is the key?

Q. 2. Why it is not reinfarction as there is ST elevation?

Ans. 1. The key is C. Dressler's syndrome.

Ans. 2. There is pericardial rub there is pericarditis and in pericarditis there is widespread ST elevation. So the condition is not new MI but Dressler's syndrome.

334. A 12yo girl presented with tics, LOC, no residual sign and no post-ictal phase. EEG abnormality in temporal lobe. The girl had a rapid recovery. What is the most probably dx?

- a. Generalized tonic-clonic
- b. Myoclonic
- c. Partialàgeneralized seizure
- d. Atonic seizure
- e. Febrile convulsion

Ans. The key is C. Partial → generalized seizure

335. A 48yo woman who has been taking medications for asthma for a long time has now presented with decreasing vision. What is the most probable cause for her decrease in vision?

- a. Inhaled salbutamol
- b. Inhaled steroids
- c. Aminophylline
- d. Beta-blockers
- e. Oral steroids

Q. 1. What is the key?

Q. 2. Justify the key.

Ans. 1. The key is E. Oral steroid.

Ans. 2. Prolonged steroid use leads to cataract formation.

336. A 34yo man after a car crash is in the ED and deteriorating. His GCS has fallen from 13 to 7. What is the most appropriate next step?

- a. CT
- b. Burr hole
- c. MRI
- d. Intubation
- e. IV fluids

Ans. The key is D. Intubation. [ABC protocol].

337. A pt with alternating swings or episodes from elation and depression had underwent tx and gotten better. What medication needed to be continued so he can stay well?

- a. Anxiolytics
- b. Mood stabilizers
- c. Antidepressants
- d. Antipsychotics

Ans. The key is B. Mood stabilizers [bipolar disorder treated with mood stabilizers].

338. A 40yo male with pre-existing glomerulonephritis having proteinuria and hematuria suddenly deteriorates and presents with oliguria and serum K+=7.8mmol/L, urea=13mmol/L, creat=342mmol/L, GFR=19mL/h. The best management would be?

- a. Calcium supplement
- b. Calcium resonate enema 30g
- c. 10units insulin with 50% dextrose
- d. Nebulized salbutamol
- e. 10ml of 10% calcium gluconate
- f. Hemodialysis urgent

Q. 1. What is the key?

Q. 2. Justify the key.

Ans. 1. The key is E. 10 ml of 10% calcium gluconate.

Ans. 2. To prevent cardiac arrhythmia. [Actually calcium gluconate neither shifts K⁺ to cells nor reduces serum K⁺ level that much. It just prevents cardiac arrest or life threatening cardiac arrhythmia and buys time till definitive measures are taken].

339. 34yo man was brought to the ED after a RTA. BP=50/0mmHg and chest wall not movingsymmetrically, RR=34bpm. What would be initial action?

- a. IV fluid infusion
- b. Intubation and ventilation
- c. CT chest
- d. Transfer to ITU

Ans. The key is B. Intubation and ventilation [ABC protocol].

340. A pt complains of SOB, wheeze, cough and nocturnal waking. He has dry scaly shin with rashes that are itchy. What is the single most likely dx?

- a. Scabies
- b. Eczema
- c. Rheumatism
- d. Dermatitis
- e. Psoriasis

Ans. The key is B. Eczema. [Asthma may be associated with atopy].

341. A 54yo woman has presented with episodes of abdominal ache, vomiting and postural hypotension. She also has a dark pigmentation of her skin. A dx of Addison's disease was made. What is the most likely electrolyte abnormality expected in this pt?

- a. High Na⁺, Low K⁺
- b. Low Na⁺, High K⁺
- c. Low Na⁺, Low K⁺
- d. High Na⁺, High K⁺
- e. Low Na⁺, Normal K⁺

Ans. The key is B. Low Na⁺, High K⁺. [with Addison disease, the sodium, chloride, and carbon dioxide levels are often low, while the potassium level is high].

342. An 8yo returned from Spain with severe pain in one ear. Exam: pus in auditory canal, tympanic membrane looks normal. What is the tx option?

- a. Gentamicin topical
- b. Amoxicillin PO
- c. Analgesia
- d. Amoxicillin IV

Q. 1. What is the key?

Q. 2. What is the diagnosis?

Ans. 1. The key is A. Gentamycin topical.

Ans. 2. Diagnosis is otitis externa.

343. A 6wk child is very sick-looking. Bloods: Na+=124, K+=2.8. Dehydrated. What would you choose to resuscitate?

- a. 0.18% NS + 4% dextrose + 20mmol KCl
- b. 0.9% NS
- c. 0.45% NS
- d. 0.45% NS + 5% dextrose
- e. 0.45% NS + 5% dextrose + 20 mmol KCl

Ans. The given key is E. But it is wrong key! The correct key is B. 0.9% NS. Explanation: Rsuscitation is mostly done with 0.9% NS or ringers lactate, or hartmans solution. Here is hypokalemia. To treat hypokalaemia the cut off value is below 2.5 mmol/L and absence of anuria during resuscitation. Maintenance is with fluid E.

344. A 68yo man gets repeated attacks of LOC and TIA. What is the most likely cause for this?

- a. Atrial fib
- b. Mitral stenosis
- c. Aortic stenosis
- d. HOCM
- e. Carotid artery stenosis

Ans. The key is E. Carotid artery stenosis.

345. Pt presented with hemoptysis 7d post-tonsillectomy. What is the next step?

- a. Packing
- b. Oral antibiotics + discharge
- c. Admit + IV antibiotics
- d. Return to theatre and explore
- e. Ice cream and cold fluids

Ans. The key is C. Admit + IV antibiotic. [infection is a common cause of secondary haemorrhage. Patient should be admitted to observe the course of bleeding and treatment is given with IV antibiotics].

346. A child was admitted following a RTA with initial GCS=15. Then during the night the noticed GCS reduced to 13. What is the management?

- a. Refer to neuro-surgeon
- b. IV fluids
- c. Oxygen
- d. CT brain
- e. Skull XR

Ans. The key is D. CT brain. [probable intracranial haemorrhage].

347. A 57yo woman who is suffering from HTN, presented to the hospital with complaints of recurrent falls when trying to get out of bed or getting up from sitting. She is on some anti-HTN therapy with no other med prbs. What is the cause of her fall?

- a. CCB
- b. Vertebrobasilar insufficiency
- c. Thiazide
- d. Hypoglycemia
- e. Infection

Ans. The key is C. Thiazide. [It causes postural hypotension by volume depletion].

348. A 56yo woman with MS presents with drooping of the left side of her lips. She also has loss of sensation over her face, hearing impairment and some in-coordination of her movements. What is the most likely anatomical site affected?

- a. Cerebellum
- b. Cerebrum
- c. Spinal cord
- d. Brain stem
- e. Optic nerve

Ans. The key is D. Brain stem. Features of 5, 7, 8th cranial nerve and cerebellum involvement suggestive of brainstem lesion.

349. A 68yo male presented with swelling in the lower pole of the parotid gland for the last 10yrs. Exam: firm in consistency. What's the most probable dx?

- a. Pleomorphic adenoma
- b. Adenolymphoma
- c. Mikulicz's disease
- d. Parotiditis
- e. Frey's syndrome

Ans. The key is A. Pleomorphic adenoma. [Pleomorphic adenoma (most common) - also called benign mixed tumour: is the most common tumour of the parotid gland and causes over a third of submandibular tumours. They are slow-growing and asymptomatic, having a malignant potentiality].

350. A 28yo shipyard worker was admitted for pain in calf while at work which has been increasing over the last 3m. There is no hx of HTN or DM but he is a smoker. Exam: loss of posterior tibial and dorsalis pedis pulsation along with a non-healing ulcer at the base of the right 1st MTP joint. What is the most probably dx?

- a. Thromboangitis obliterans
- b. Sciatica
- c. DVT
- d. Baker's cyst
- e. Embolus

Q. 1. What is the key?

Q. 2. What are the points in favour?

Ans. The key is A. Thromboangitis obliterans.

Ans. 2. i) young age ii) smoker iii) pain in calf iv) loss of posterior tibial and dorsalis pedis pulsation v) non-healing ulcer at the base of the right 1st MTP joint all are suggestive of Buerger's disease.

351. A 35yo lady presents with painful ulcers on her vulva, what is the appropriate inv which will lead to the dx?

- a. Anti-HSV antibodies
- b. Dark ground microscopy of the ulcer
- c. Treponema palladium antibody test
- d. Rapid plasma regain test
- e. VDRL

Ans. The key is A. Anti-HSV antibodies. [Genital Herpes may be asymptomatic or may remain dormant for months or even years. When symptoms occur soon after a person is infected, they tend to be severe. They may start as multiple small blisters that eventually break open and produce raw, painful sores that scab and heal over within a few weeks. The blisters and sores may be accompanied by flu-like symptoms with fever and swollen lymph nodes.

There are three major drugs commonly used to treat genital herpes symptoms: acyclovir (Zovirax), famciclovir (Famvir), and valacyclovir (Valtrex). These are all taken in pill form. Severe cases may be treated with the intravenous (IV) drug acyclovir].

352. A 53yo man presents with a longstanding hx of a 1cm lesion on his arm. It has started bleeding on touch. What is the most likely dx?

- a. Basal cell carcinoma
- b. Kaposi's sarcoma
- c. Malignant melanoma
- d. Squamous cell carcinoma
- e. Keratoacanthoma

Ans. The key is D. Squamous cell carcinoma. [SSCs Arises in squamous cells. SCCs may occur on all areas of the body including the mucous membranes and genitals, but are most common in areas frequently exposed to the sun, such as the rim of the ear, lower lip, face, balding scalp, neck, hands, arms and legs. SCCs often look like scaly red patches, open sores, elevated growths with a central depression, or warts; they may crust or bleed. A tissue sample (biopsy) will be examined under a microscope to arrive at a diagnosis. Squamous cell carcinomas detected at an early stage and removed promptly are almost always curable and cause minimal damage].

353. A 47yo man with hx of IHD complains of chest pain with SOB on exertion over the past few days. ECG normal, Echo= increased EF and decreased septal wall thickness. What is the most likely dx?

- a. Dilated CM
- b. Constrictive pericarditis
- c. Amyloidosis
- d. Subacute endocarditis

Ans. The key is A. Dilated CM. [In dilated cardiomyopathy ejection fraction is decreased (but here increased which goes in favour of constrictive pericarditis). On the other hand decreased septal wall thickness favours the diagnosis of dilated cardiomyopathy. So it seems to be a bad recall!!!].

354. An elderly pt who is known to have DM presents to the hospital with drowsiness, tremors and confusion. What inv should be done to help in further management?

- a. Blood sugar
- b. ECG
- c. Standing and lying BP
- d. Fasting blood sugar
- e. CT

Ans. The key is A. Blood sugar.

355. A 28yo pregnant woman with polyhydramnios and SOB comes for an anomaly scan at 31 wks. US= absence of gastric bubble. What is the most likely dx?

- a. Duodenal atresia
- b. Esophageal atresia
- c. Gastrochiasis
- d. Exomphalos
- e. Diaphragmatic hernia

Ans. The key is B. Esophageal atresia.

356. A 1m boy has been brought to the ED, conscious but with cool peripheries and has HR=222bpm. He has been irritable and feeding poorly for 24h. CXR=borderline enlarged heart with clear lung fields. ECG=regular narrow complex tachycardia, with difficulty identifying p wave. What is the single most appropriate immediate tx?

- a. Administer fluid bolus
- b. Administer oxygen
- c. Oral beta-blockers
- d. Synchronized DC cardio-version
- e. Unilateral carotid sinus massage

Q. 1. What is the key?

Q. 2. Justify the key.

Q. 3. What is the diagnosis?

Ans. 1. The key is D. Synchronized DC cardioversion.

Ans. As the patient is in probable hemodynamic instability (suggested by cool peripheries due to low BP or inadequate CO) so we should go for DC cardioversion.

Ans. 3. Probable diagnosis is SVT.

357. A 7yo child presented with chronic cough and is also found to be jaundiced on examination. What is the most likely dx?

- a. Congenital diaphragmatic hernia
- b. Congenital cystic adenomatoid malformation
- c. Bronchiolitis
- d. RDS
- e. Alpha 1 antitrypsin deficiency

Q. 1. What is the key?

Q. 2. Justify the key.

Ans. 1. The key is E. Alpha 1 antitrypsin deficiency.

Ans. 2. Unexplained liver disease with respiratory symptoms are very suggestive of AATD.

358. A 35yo construction worker is dx with indirect inguinal hernia. Which statement below best describes it?

- a. Passes through the superficial inguinal ring only
- b. Lies above and lateral to the pubic tubercle
- c. Does not pass through the superficial inguinal ring
- d. Passes through the deep inguinal ring

Ans. The key is D. Passes through the deep inguinal ring.

359. A woman has numerous painful ulcers on her vulva. What is the cause?

- a. Chlamydia
- b. Trichomonas
- c. Gardenella
- d. HSV
- e. EBV

Ans. The key is D. HSV.

360. A 72 yo man has been on warfarin for 2yrs because of past TIA and stroke. What is the most important complication that we should be careful with?

- a. Headache
- b. Osteoporosis
- c. Ear infection
- d. Limb ischemia
- e. Diarrhea

Ans. The given key is E. Diarrhoea which is considered as a wrong key and A. Headache is the correct key. [Headache is the warning sign of hemorrhagic stroke].

361. A 55yo man has been admitted for elective herniorrhaphy. Which among the following can be the reason to delay his surgery?

- a. Controlled asthma
- b. Controlled atrial fib
- c. DVT 2yrs ago
- d. Diastolic BP 90mmHg
- e. MI 2 months ago

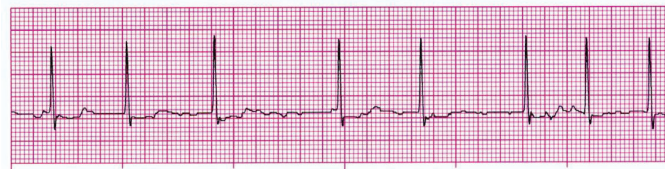Ans. The key is E. MI 2 months ago [better go for surgery 6 months post MI as surgery before this has higher mortality rate].

362. A 65yo known case of liver ca and metastasis presents with gastric reflux and bloatedness. On bone exam there is osteoporosis. He also has basal consolidation in the left lung. What is the vnext appropriate step?

- a. PPI IV
- b. Alendronate
- c. IV antibiotics
- d. Analgesic
- e. PPI PO

Ans. Here is two key C. IV antibiotics and E. PPI PO. Correct key is C. IV antibiotics. [Pneumonia should be treated first].

363. A 66yo man has the following ECG. What is the most appropriate next step in management?



- a. Metoprolol
- b. Digoxin
- c. Carotid sinus massage
- d. Adenosine
- e. Amiodarone.

Ans. The key is A. Metoprolol. [P waves are replaced by fibrillatory f-waves. Irregular R-R intervals. Dx atrial fibrillation].

364. A 22yo sexually active male came with 2d hx of fever with pain in scrotal area. Exam: scrotal skin is red and tender. What is the most appropriate dx?

- a. Torsion of testis
- b. Orchitis
- c. Inguinal hernia
- d. Epididymo-orchitis

Q. 1. What is the key?

Q. 2. How will you differentiate torsion from epididymo-orchitis?

Ans. 1. The key is D. Epididymo-orchitis.

Ans 2. In epididymo-orchitis there should be fever, elevation of testes reduces pain (positive prehn sign). In torsion testis lies at a higher level. In torsion urinalysis negative but in epididymo-orchitis it is positive. Epididymo-orchitis usually occurs in sexually active man.

365. A man on warfarin posted for hemicolectomy. As the pt is about to undergo surgery. What option is the best for him?

- a. Continue with warfarin
- b. Continue with warfarin and add heparin
- c. Stop warfarin and add aspirin
- d. Stop warfarin and add heparin
- e. Stop warfarin

Ans. The key is D. Stop warfarin and add heparin.

366. A 65yo known alcoholic is brought into hospital with confusion, aggressiveness and ophthalmoplegia. He is treated with diazepam. What other drug would you like to prescribe?

- a. Antibiotics
- b. Glucose
- c. IV fluids
- d. Disulfiram
- e. Vit B complex

Ans. The key is E. Vitamin B complex.

367. A 32yo woman has severe right sided abdominal pain radiating into the groin which has lasted for 3h. She is writhing in pain. She has no abdominal signs. What is the most likely cause of her abdominal pain?

- a. Appendicitis
- b. Ruptured ectopic pregnancy
- c. Salpingitis
- d. Ureteric colic
- e. Strangulated hernia

Q. 1. What is the key?

Q. 2. Abdominal pain radiating to groin, at which level of stone does it indicate?

Ans. 1. The key is D. Ureteric colic.

Ans. 2. It indicate stone at lower ureter. [i) Pain from upper ureteral stones tends to radiate to the flank and lumbar areas. ii) Midureteral calculi cause pain that radiates anteriorly and caudally. This midureteral pain in particular can easily mimic appendicitis on the right or acute diverticulitis on the left. iii) Distal ureteral stones cause pain that tends to radiate into the groin or testicle in the male or labia majora in the female.

368. A 39yo coal miner who smokes, drinks and has a fam hx of bladder cancer is suffering from BPH. The most important risk factor for his bladder carcinoma is?

- a. Fam hx
- b. Smoking
- c. Exposure to coal mine
- d. BPH

Q. 1. What is the key?

Q. 2. What are the risk factors for bladder cancer?

Ans. 1. The key is B. smoking.

Ans. 2. Risk factors of bladder cancer: i) Smoking ii) Exposure to chemicals used in dye industry iii) Whites are more likely to develop bladder cancer iv) Risk increases with age v) More common in men vi) Chronic bladder irritation and infections (urinary infections, kidney and bladder stones, bladder catheter left in place a long time.) vii) Personal history of bladder or other urothelial cancer viii) Family history ix) Chemotherapy or radiotherapy x) Pioglitazone for more than one year and certain herb xi) Arsenic in drinking water xii) Low fluid consumption.

369. A 34yo woman is referred to the endocrine clinic with a hx of thyrotoxicosis. At her 1st appointment she is found to have a smooth goiter, lid lag and bilateral exophthalmos with puffy eyelids and conjunctival injection. She wants to discuss the tx of her thyroid prb as she is keen to become pregnant. What is the most likely tx you would advise?

- a. 18m of carbimazole alone
- b. 18m of PTU (propylthiouracil) alone
- c. A combo of anti-thyroid drug and thyroidine
- d. Radioactive iodine
- e. Thyroidectomy

Q. 1. What is the key?

Q. 2. What is the reason?

Ans. 1. The key is B. 18m of PTU alone.

Ans. 2. Other drug option i.e Carbimazole is teratogenic [can cause i) spina bifida ii) cardiovascular malformations, hypospadias etc] if become pregnant. PTU is on the other hand relatively safe in pregnancy.

370. A child living with his stepfather is brought by the mother with multiple bruises, fever and fractures. What do you suspect?

- a. NAI
- b. Malnutrition
- c. Thrombocytopenia
- d. HIV

Ans. The key is A. NAI. [H/O living with stepfather, multiple bruises, fever and fractures are suggestive of NAI].

371. A young man who was held by the police was punched while in custody. He is now cyanosed and unresponsive. What is the 1st thing you would do?

- a. IV fluids
- b. Clear airway
- c. Turn pt and put in recovery position
- d. Give 100% oxygen
- e. Intubate and ventilate

Ans. The key is B. Clear airway. [ABC protocol].

372. A HTN male loses vision in his left eye. The eye shows hand movement and a light shined in the eye is seen as a faint light. Fundus exam: flame shaped hemorrhages. The right eye is normal. What is the cause of this pts unilateral blindness?

- a. HTN retinopathy
- b. CRA thrombosis
- c. CRV thrombosis
- d. Background retinopathy
- e. Retinal detachment

Ans. The key is A. HTN retinopathy [it is a wrong key. Correct key is C. central retinal vein thrombosis].

373. A mentally retarded child puts a green pea in his ear while eating. The carer confirms this. Otoscopy shows a green colored object in the ear canal. What is the most appropriate single best approach to remove this object?

- a. By magnet
- b. Syringing
- c. Under GA
- d. By hook
- e. By instilling olive oil

Ans. The key is Under GA. [Pea is not a magnetic material and hence it cannot be removed by magnet, it will swell up if syringing is attempted, as hook placement is likely with risk of pushing the pea deeper it is not also suitable in a mentally retarded child, and olive oil is not of help in case of pea. So to avoid injury it is better to remove under GA].

374. A pt presents with longstanding gastric reflux, dysphagia and chest pain. On barium enema, dilation of esophagus with tapering end is noted. He was found with Barrett's esophagus. He had progressive dysphagia to solids and then liquids. What is the single most appropriate dx?

- a. Achalasia
- b. Esophageal spasm
- c. GERD
- d. Barrett's esophagus
- e. Esophageal carcinoma

Ans. The key is E. Oesophageal carcinoma. [there is dilatation in oesophagus which is seen both in achalasia and carcinoma. Dysphagia to solid initially is very much suggestive of carcinoma and also barrett's change is a clue to carcinoma]

375. A 48yo lady presents with itching, excoriations, redness, bloody discharge and ulceration around her nipple. What is the most likely dx?

- a. Paget's disease of the breast
- b. Fibrocystic dysplasia
- c. Breast abscess
- d. Duct papilloma
- e. Eczema

Ans. The key is A. Paget's disease of the breast.

376. Pt with widespread ovarian carcinoma has bowel obstruction and severe colic for 2h and was normal in between severe pain for a few hours. What is the most appropriate management?

- a. PCA (morphine)
- b. Spasmolytics
- c. Palliative colostomy
- d. Oral morphine
- e. Laxatives

Q. 1. What is the key?

Q. 2. Why we should go for this option?

Ans. 1. The key is C. Palliative colostomy.

Ans. 2. Cancer or chemotherapy induced obstructions are unlikely to respond to conservative management [NBM, IV fluid, nasogastric suction] and hence only analgesia will not relieve it. So in such cases we have to go for palliative colostomy.

377. A 70yo man admits to asbestos exposure 20yrs ago and has attempted to quit smoking. He has noted weight loss and hoarseness of voice. Choose the single most likely type of cancer a.w risk factors present.

- a. Basal cell carcinoma
- b. Bronchial carcinoma
- c. Esophageal carcinoma
- d. Nasopharyngeal carcinoma
- e. Oral carcinoma

Q. 1. What is the key?

Q. 2. What are the conditions related to asbestos exposure?

Ans. 1. The key is B. Bronchial carcinoma. [Asbestos exposure is a risk factor for lung cancer and also has a synergistic effect with cigarette smoke. Hoarseness can be from involvement of recurrent laryngeal nerve].

Ans. 2. Conditions related to asbestos exposure: i) Pleural plaques (after a latent period of 20-40 yrs) ii) Pleural thickening iii) Asbestosis (latent period is typically 15-30 yrs) iv) Mesothelioma (prognosis is very poor) v) Lung cancer.

378. A 32yo woman had progressive decrease in vision over 3yrs. She is now dx as almost blind. What would be the mechanism?

- a. Cataract
- b. Glaucoma
- c. Retinopathy
- d. Uveitis
- e. Keratitis

Q. 1. What is the key ?

Q. 2. Why you made this diagnosis?

Ans. 1. The key is B. Glaucoma. This is wrong key! Correct option is retinopathy.

Ans. 2. Cataract is unlikely at this age. Uveitis and iritis doesn't have such degree of vision loss and iritis and anterior uveitis have pain, redness and photophobia. Open angle glaucoma mostly occurs after the age of 50yrs. Answer should be retinopathy (example retinitis pigmentosa).

379. A child during operation and immediately after showed glycosuria, but later his urine sugar was normal. Choose the most probable dx.

- a. Pre-diabetic state
- b. Normal finding
- c. Low renal tubular threshold
- d. DM

Q. 1. What is the key?

Q. 2. Why glycosuria occurred?

Ans. 1. The key is B. Normal finding.

Ans. 2. Stress during operation can cause transient hyperglycemia causing glycosuria secondary to stress induced rise of cortisol which becomes normal after some time.

380. A pt presented with hx of swelling in the region of the sub-mandibular region, which became more prominent and painful on chewing. He also gave hx of sour taste in the mouth, the area is tender on palpation. Choose the most probable dx?

- a. Chronic recurrent sialadenitis
- b. Adenolymphoma
- c. Mikulicz's disease
- d. Adenoid cystic carcinoma
- e. Sub-mandibular abscess

Ans. The key is A. Chronic recurrent sialadenitis. [pain, swelling, more pain on chewing, tenderness, and submandibular region suggests diagnosis of submandibular chronic recurrent sialadenitis, usually secondary to sialolithiasis or stricture].

381. ECG of an 80yo pt of ICH shows saw-tooth like waves, QRS complex of 80ms duration, ventricular rate=150/min and regular R-R interval. What is the most probable dx?

- a. Atrial fib
- b. Atrial flutter
- c. SVT
- d. Mobitz type1 second degree heart block
- e. Sinus tachycardia

Ans. The key is B. Atrial flutter. [Saw-tooth like waves, normal QRS complex of 80 ms (normal range 70-100 ms), ventricular rate of 150/min and regular R-R interval is diagnostic of atrial flutter].

382. A 50 yo woman who was treated for breast cancer 3 yrs ago now presents with increase thirst and confusion. She has become drowsy now. What is the most likely metabolic abnormality?

- a. Hypercalcemia
- b. Hyperkalemia
- c. Hypoglycemia
- d. Hyperglycemia
- e. Hypocalcemia

Q. 1. What is the key?

Q. 2. Justify the key

Ans. 1. The key is A. Hypercalcemia.

Ans. 2. Increased thirst, confusion, drowsiness these are features of hypercalcemia. Any solid organ tumour can produce hypercalcemia. Here treated Ca breast is the probable cause of hypercalcemia.

383. A 29yo woman presents to her GP with a hx of weight loss, heat intolerance, poor conc and palpitations. Which of the following is most likely to be a/w dx of thyroiditis a/w viral infection?

- a. Bilateral exophthalmos
- b. Diffuse, smooth goiter
- c. Reduced uptake on thyroid isotope scan
- d. Positive thyroid peroxidase antibodies
- e. Pretibial myxedema

Q. 1. What is the key?

Q. 2. What is the diagnosis?

Q. 3. What are the points in favour?

Ans. 1. The key is C. Reduced uptake on thyroid isotope scan.

Ans. 2. The diagnosis is De Quervain's or subacute thyroiditis.

Ans. 3. Viral or subacute thyroiditis: diagnostic criteria: i) Features of hyperthyroidism present. ii) Pain thyroid, not mentioned. iii) Investigations: high esr (60-100) not mentioned, Reduced uptake of radioactive iodine by the gland.

384. A lady, post-colostomy closure after 4days comes with fluctuating small swelling in the stoma. What is the management option for her?

- a. Local exploration
- b. Exploratory laparotomy
- c. Open laparotomy
- d. Reassure

Ans. The key is A. Local exploration.

385. A 65yo female pt was given tamoxifen, which of the following side effect caused by it will concern you?

- a. Fluid retention
- b. Vaginal bleeding
- c. Loss of appetite
- d. Headache and dizziness
- e. Anorgasm

Q. 1. What is the key?

Q. 2. What is the reason to select this key?

Ans. 1. The key is B. Vaginal bleeding.

Ans. 2. Tamoxifen can promote development of endometrial carcinoma. So vaginal bleeding will be of concern for us.

386. A 39yo man with acute renal failure presents with palpitations. His ECG shows tall tented T waves and wide QRS complex. What is the next best step?

- a. Dialysis
- b. IV calcium chloride
- c. IV insulin w/ dextrose
- d. Calcium resonium
- e. Nebulized salbutamol

Q. 1. What is the key?

Q. 2. What is the diagnosis?

Q. 3. What is the significant of tall tented T waves and wide QRS complex?

Ans. 1. The key is B. IV calcium chloride (both IV calcium gluconate or IV calcium chloride can be used when there is ECG changes).

Ans. 2. The ECG changes are suggestive of Hyperkalemia.

Ans. 3. At potassium level of >5.5mEq/L occurs tall tented T waves and at potassium level >7mEq/L occurs wide QRS complex with bizarre QRS morphology.

387. A 54yo pt 7 days after a total hip replacement presents with acute onset breathlessness and raised JVP. Which of the following inv will be most helpful in leading to a dx?

- a. CXR
- b. CTPA
- c. V/Q scan
- d. D-Dimer
- e. Doppler US of legs

Q. 1. What is the key?

Q. 2. Justify the key.

Ans. 1. The key is B. CTPA.

Ans. 2. The patient has a +ve two level PE Wells score (if it was negative we should do D-Dimer) and there is no renal impairment or history suggestive of allergy to contrast media (if these present we should have go for VQ scan) the investigation of choice is PTCA. NICE guideline.

388. A 7yo girl has been treated with penicillin after sore throat, fever and cough. Then she develops skin rash and itching. What is the most probable dx?

- a. Erythema nodosum
- b. Erythema multiforme
- c. SJS
- d. Erythema marginatum
- e. Erythema gangrenosum

Q. What is the key?

Q. What common drugs causes this to occur?

Ans. 1. The key is B. Erythema multiforme.

Ans. 2. Common drugs causing erythema multiforme are: antibiotics (including, sulphonamides, penicillin), anticonvulsants (phenytoin, barbiturates), aspirin, antituberculous, and allopurinol.

389. A 60yo man presented with a lump in the left supraclavicular region. His appetite is decreased and he has lost 5kg recently. What is the most probable dx?

- a. Thyroid carcinoma
- b. Stomach carcinoma
- c. Bronchial carcinoma
- d. Mesothelioma
- e. Laryngeal carcinoma

Ans. The key is B. Stomach carcinoma. [Mentioned lump in the left supraclavicular region is Vershow's gland, has long been regarded as strongly indicative of the presence of cancer in the abdomen, specifically gastric cancer].

390. A 64yo man has presented to the ED with a stroke. CT shows no hemorrhage. ECG shows atrial fib. He has been thrombolysed and he's awaiting discharge. What prophylactic regimen is best for him?

- a. Warfarin
- b. Heparin
- c. Aspirin
- d. Statins
- e. Beta blockers

Ans. The key is A. Warfarine. [Atrial fibrillation: post stroke- following a stroke or TIA warfarine should be given as the anticoagulant of choice. NICE guideline].

391. A 54yo man after a CVA presents with ataxia, intention tremors and slurred speech. Which part of the brain has been affected by the stroke?

- a. Inner ear
- b. Brain stem
- c. Diencephalon
- d. Cerebrum
- e. Cerebellum

Q. 1. What is the key?

Q. 2. What are the features of the condition?

Ans. 1. The key is E. Cerebellum.

Ans. 2. i) Ataxia ii) slurred speech or dysarthria iii) dysidiokokinesia

iv) intention tremor v) nystagmus.

392. A 57yo man with blood group A complains of symptoms of vomiting, tiredness, weight loss and palpitations. Exam: hepatomegaly, ascites, palpable left supraclavicular mass. What is the most likely dx?

- a. Gastric carcinoma
- b. Colorectal carcinoma
- c. Peptic ulcer disease
- d. Atrophic gastritis
- e. Krukenburg tumor

Ans. The key is A. Gastric carcinoma. [i) blood group A is associated with gastric cancer ii) vomiting, tiredness, weight loss are general features of gastric cancer iii) palpitation from anemia of cancer iv) hepatomegaly (metastasis) and ascites are late features of gastric cancer. v) palpable left supraclavicular mass- is Vershow's gland, has long been regarded as strongly indicative of gastric cancer].

393. A 21yo girl looking unkempt, agitated, malnourished and nervous came to the hospital asking for painkillers for her abdominal pain. She is sweating, shivering and complains of joint pain. What can be the substance misuse here?

- a. Alcohol
- b. Heroin
- c. Cocaine
- d. LSD
- e. Ecstasy

Ans. The key is B. Heroin. [agitation, nervousness, abdominal cramp, sweating, shivering and piloerection, arthralgia these are features of heroin withdrawal].

394. A child presents with increasing jaundice and pale stools. Choose the most appropriate test?

- a. US abdomen
- b. Sweat test
- c. TFT
- d. LFT
- e. Endomysial antibodies

Ans. The key is A. US abdomen. [This is a picture suggestive of obstructive jaundice. LFT can give clue like much raised bilirubin, AST and ALT not that high and raised alkaline phosphatase but still USG is diagnostic in case of obstructive jaundice].

395. A 32yo man presents with hearing loss. AC>BC in the right ear after Rhine test. He also complains of tinnitus, vertigo and numbness on same half of his face. What is the most appropriate inv for his condition?

- a. Audiometry
- b. CT
- c. MRI
- d. Tympanometry
- e. Weber's test

Ans. The key is C. MRI. [features are suggestive of acoustic neuroma, so MRI is the preferred option].

396. A 56 yo lady with lung cancer presents with urinary retention, postural hypotension, diminished reflexes and sluggish pupillary reaction. What is the most likely explanation for her symptoms?

- a. Paraneoplastic syndrome
- b. Progression of lung cancer
- c. Brain metastasis
- d. Hyponatremia
- e. Spinal cord compression

Ans. The key is A. Paraneoplastic syndrome. [Features given are well known features of autonomic neuropathy which can be a result of paraneoplastic syndrome].

397. An old woman having decreased vision can't see properly at night. She has changed her glasses quite a few times but to no effect. She has normal pupil and cornea. What is the most likely dx?

- a. Cataract
- b. Glaucoma
- c. Retinal detachment
- d. Iritis
- e. GCA

Ans. The key is B. Glaucoma. It is a wrong key. Correct key should be A. Cataract. [Age and normal pupil and cornea are suggestive of cataract. If it was glaucoma pupil would be a bit dilated and/or oval in shape].

398. A pt comes with sudden loss of vision. On fundoscopy the optic disc is normal. What is the underlying pathology?

- a. Iritis
- b. Glaucoma
- c. Vitreous chamber
- d. Retinal detachment

Q. 1. What is the key?

Q. 2. What are the causes of sudden painless loss of vision?

Ans. 1. The Key is D. Retinal detachment. [At an early stage optic disc remains normal in retinal detachment].

Ans. 2. Causes of sudden painless loss of vision:

- Retinal detachment
- Vitreous haemorrhage
- Retinal vein occlusion
- Retinal artery occlusion
- Optic neuritis
- Cerebrovascular accident

399. A child was woken up from sleep with severe pain in the testis. Exam: tenderness on palpation and only one testis was normal in size and position. What would be your next step?

- a. Analgesia
- b. Antibiotics
- c. Refer urgently to a surgeon
- d. Reassurance
- e. Discharge with analgesics

Ans. The key is A. Analgesia. [According to some US sites it is analgesia but no UK site support this! So for Plab exam the more acceptable option is C. Refer urgently to a surgeon].

400. A child suffering from asthma presents with Temp 39C, drooling saliva on to the mother's lap, and taking oxygen by mask. What sign will indicate that he is deteriorating?

- a. Intercostal recession
- b. Diffuse wheeze
- c. Drowsiness

Ans. The key is A. Intercostal recession. This is wrong key. Correct key is C. Drowsiness. [Intercostal recession is a sign of severe asthma but it can be seen at a lesser degree as well. So drowsiness is more appropriate answer].

401. A 12yo boy presents with painful swollen knee after a sudden fall. Which bursa is most likely to be affected?

- a. Semimembranous bursa
- b. Prepatellar bursa
- c. Pretibial bursa
- d. Suprapatellar bursa

Ans. The key is B. Prepatellar bursa. [A fall onto the knee can damage the prepatellar bursa. This usually causes bleeding into the bursa sac causing swollen painful knee. Prepatellar bursitis that is caused by an injury will usually go away on its own. The body will absorb the blood in the bursa over several weeks, and the bursa should return to normal. If swelling in the bursa is causing a slow recovery, a needle may be inserted to drain the blood and speed up the process. There is a slight risk of infection in putting a needle into the bursa].

402. A 61yo man has been referred to the OPD with frequent episodes of breathlessness and chest pain a/w palpitations. He has a regular pulse rate=60bpm. ECG=sinus rhythm. What is the most appropriate inv to be done?

- a. Cardiac enzymes
- b. CXR
- c. ECG
- d. Echo
- e. 24h ECG

Ans. The key is E. 24h ECG.

Indications of 24 h ambulatory holter monitoring:

To evaluate chest pain not reproduced with exercise testing

To evaluate other signs and symptoms that may be heart-related, such as fatigue, shortness of breath, dizziness, or fainting

To identify arrhythmias or palpitations

To assess risk for future heart-related events in certain conditions, such as idiopathic hypertrophic cardiomyopathy, post-heart attack with weakness of the left side of the heart, or Wolff-Parkinson-White syndrome

To assess the function of an implanted pacemaker

To determine the effectiveness of therapy for complex arrhythmias

403. A woman dx with Ca Breast presents now with urinary freq. which part of the brain is the metastasis spread to?

- a. Brain stem
- b. Pons
- c. Medulla
- d. Diencephalon
- e. Cerebral cortex

Ans. The key is D. Diencephalon. [diencephalon is made up of four distinct components: i) the thalamus ii) the subthalamus iii) the hypothalamus and iv) the epithalamus. Among these the hypothalamus has crucial role in causing urinary frequency].

404. A man is very depressed and miserable after his wife's death. He sees no point in living now that his wife is not around and apologises for his existence. He refuses any help offered. His son has brought him to the ED. The son can't deal with the father any more. What is the most appropriate next step?

- a. Voluntary admission to psychiatry ward
- b. Compulsory admission under MHA
- c. Refer to social services
- d. Alternate housing
- e. ECT

Ans. The key is B. Compulsory admission under MHA. [This patient is refusing any help offered! And his son cannot deal with him anymore! In this situation voluntary admission to psychiatry ward is not possible and the option of choice is "compulsory admission under MHA". The point here is the man has felt himself in danger by self neglect].

405. A 31yo man has epistaxis 10 days following polypectomy. What is the most likely dx?

- a. Nasal infection
- b. Coagulation disorder
- c. Carcinoma

Ans. The key is A. Nasal infection. [Infection is one of the most important cause of secondary hemorrhage].

406. A woman had an MI. She was breathless and is put on oxygen mask and GTN, her chest pain has improved. Her HR=40bpm. ECG shows ST elevation in leads I, II, III. What is your next step?

- a. LMWH
- b. Streptokinase
- c. Angiography
- d. Continue current management
- e. None

Ans. The key is B. Streptokinase. This is wrong key. Correct key is C. Angiography. [Now a days PCI is considered to have much better outcome than thrombolysis].

407. A 67yo male presents with polyuria and nocturia. His BMI=33, urine culture = negative for nitrates. What is the next dx inv?

- a. PSA
- b. Urea, creat and electrolytes
- c. MSU culture and sensitivity
- d. Acid fast urine test
- e. Blood sugar

Ans. The key is E. Blood sugar. [Age at presentation and class1 obesity favours the diagnosis of type2 DM].

408. A pt from Africa comes with nodular patch on the shin which is reddish brown. What is the most probable dx?

- a. Lupus vulgaris
- b. Erythema nodosum
- c. Pyoderma gangrenosum
- d. Erythema marginatum
- e. Solar keratosis

Ans. The key is B. Erythema nodosum. [Causes of erythema nodosum: MOST COMMON CAUSES- i) streptococcal infection ii) sarcoidosis. Other causes- tuberculosis, mycoplasma pneumonia, infectious mononucleosis, drugs- sulfa related drug, OCP, oestrogen; Behcet's disease, CD, UC; lymphoma, leukemia and some others].

409. A 29yo lady came to the ED with complaints of palpitations that have been there for the past 4 days and also feeling warmer than usual. Exam: HR=154bpm, irregular rhythm. What is the tx for her condition?

- a. Amiodarone
- b. Beta blockers
- c. Adenosine
- d. Verapamil
- e. Flecainide

Ans. The key is B. Beta blockers [The probable arrhythmia is AF secondary to thyrotoxicosis. Some of the symptoms of hyperthyroidism (such as tremor and palpitations, which are caused by excess thyroid hormone acting on the cardiac and nervous system) can be improved within a number of hours by beta-blockers. So to rapid control the symptoms of thyrotoxicosis Beta blocker should be used which will improve the arrhythmia as well].

410. A T2DM is undergoing a gastric surgery. What is the most appropriate pre-op management?

- a. Start him in IV insulin and glucose and K⁺ just before surgery
- b. Stop his oral hypoglycemic on the day of the procedure
- c. Continue regular oral hypoglycemic
- d. Stop oral hypoglycemic the prv night and start IV insulin with glucose and K⁺ before surgery
- e. Change to short acting oral hypoglycemic

Ans. The key is D. Stop oral hypoglycemic the prv night and start IV insulin with glucose and K⁺ before Surgery.

411. A 19yo boy is brought by his mother with complaint of lack of interest and no social interactions. He has no friends, he doesn't talk much, his only interest is in collecting cars/vehicles having around 2000 toy cars. What is the most appropriate dx?

- a. Borderline personality disorder
- b. Depression
- c. Schizoaffective disorder
- d. Autistic spectrum disorder

Ans. The key is D. Autistic spectrum disorder.

Autism spectrum disorders affect three different areas of a child's life:
Social interaction
Communication -- both verbal and nonverbal
Behaviors and interests

In some children, a loss of language is the major impairment. In others, unusual behaviors (like spending hours lining up toys) seem to be the dominant factors.

412. A 45yo man who is diabetic and HTN but poorly compliant has chronic SOB, develops severe SOB and chest pain. Pain is sharp, increased by breathing and relieved by sitting forward. What is the single most appropriate dx?

- a. MI
- b. Pericarditis
- c. Lung cancer
- d. Good pastures syndrome
- e. Progressive massive fibrosis

Ans. The key is B. Pericarditis. [Nature of pain i.e. sharp pain increased by breathing and relieved by sitting forward is suggestive of pericarditis].

Nature of pericardial pain: the most common symptom is sharp, stabbing chest pain behind the sternum or in the left side of your chest. However, some people with acute pericarditis describe their chest pain as dull, achy or pressure-like instead, and of varying intensity.

The pain of acute pericarditis may radiate to your left shoulder and neck. It often intensifies when you cough, lie down or inhale deeply. Sitting up and leaning forward can often ease the pain.

413. A 6m boy has been brought to ED following an apneic episode at home. He is now completely well but his parents are anxious as his cousin died of SIDS (Sudden Infant Death Syndrome) at a similar age. The parents ask for guidance on BLS for a baby of his age. What is the single most recommended technique for cardiac compressions?

- a. All fingers of both hands
- b. All fingers of one hand
- c. Heel of one hand
- d. Heel of both hand
- e. Index and middle fingertips of one hand

Ans. The key is E. Index and middle fingertips of one hand.

414. A 70yo man had a right hemicolectomy for ceacal carcinoma 6days ago. He now has abdominal distension and recurrent vomiting. He has not opened his bowels since surgery. There are no bowel sounds. WBC=9, Temp=37.3C. What is the single most appropriate next management?

- a. Antibiotic therapy IV
- b. Glycerine suppository
- c. Laparotomy
- d. NG tube suction and IV fluids
- e. TPN

Ans. The key is D. NG tube suction and IV fluids. [The patient has developed paralytic ileus which should be treated conservatively].

415. A 60yo man with a 4y hx of thirst, urinary freq and weight loss presents with a deep painless ulcer on the heel. What is the most appropriate inv?

- a. Ateriography
- b. Venography
- c. Blood sugar
- d. Biopsy for malignant melanoma
- e. Biopsy for pyoderma

Ans. The key is C. Blood sugar. [The patient probably developed diabetic foot].

416. A 16yo boy presents with rash on his buttocks and extensor surface following a sore throat. What is the most probable dx?

- a. Measles
- b. Bullous-pemphigoig
- c. Rubella
- d. ITP
- e. HSP

Ans. The key is D. ITP. It's probably a wrong key! The correct key should be E. HSP. [In HSP rash typically found in buttocks, legs and

feets and may also appear on the arms, face and trunk. But in ITP it mostly occurs in lower legs. HSP usually follow a sorethroat and ITP follow viral infection like flue or URTI. HSP is a vasculitis while ITP is deficiency of platelets from more destruction in spleen which is immune mediated].

417. A 34yo man with a white patch on the margin of the mid-third of the tongue. Which is the single most appropriate LN involved?

- a. External iliac LN
- b. Pre-aortic LN
- c. Aortic LN
- d. Inguinal LN
- e. Iliac LN
- f. Submental LN
- g. Submandibular LN
- h. Deep cervical LN

Ans. The key is G. Submandibular LN.

418. A 50yo lady presents to ED with sudden severe chest pain radiating to both shoulder and accompanying SOB. Exam: cold peripheries and paraparesis. What is the single most appropriate dx?

- a. MI
- b. Aortic dissection
- c. Pulmonary embolism
- d. Good pastures syndrome
- e. Motor neuron disease

Ans. The key is B. Aortic dissection. [Cold peripheries due to reduced blood flow to distal parts of dissection and reduced perfusion of nerves resulted in paraparesis. Usual management for type A dissection is surgery and for type B is conservative].

419. A 54yo myopic develops flashes of light and then sudden loss of vision. That is the single most appropriate tx?

- a. Pan retinal photo coagulation
- b. Peripheral iridectomy
- c. Scleral buckling
- d. Spectacles
- e. Surgical extraction of lens

Ans. The key is C. Scleral buckling. [It is a case of retinal detachment with treatment option of scleral buckling].

420. A 40yo chronic alcoholic who lives alone, brought in the ED having been found confused at home after a fall. He complains of a headache and gradually worsening confusion. What is the most likely dx?

- a. Head injury
- b. Hypoglycemia
- c. Extradural hematoma
- d. Subdural hematoma
- e. Delirium

Ans. The key is D. Subdural hematoma. [subdural hematoma may be acute or chronic. In chronic symptoms may not be apparent for several days or weeks. Symptoms of subdural hematomas are: fluctuating level of consciousness, ± insidious physical or intellectual slowing, sleepiness, headache, personality change and unsteadiness. Tx. Irrigation/evacuation e.g. via burr twist drill and burr hole craniostomy 1st line. Craniotomy if the clot organized 2nd line].

421. A 54yo man with alcohol dependence has tremor and sweating 3days into a hosp admission for a fx femur. He is apprehensive and fearful. What is the single most appropriate tx?

- a. Acamprostate
- b. Chlordiazepoxide
- c. Lorazepam
- d. Lofexidine
- e. Prochlorperazine

Ans. The key is B. Chlordiazepoxide. C. Lorazepam is also correct key! [Dx alcohol withdrawal symptom. According to NICE 1st line treatment is oral lorazepam and if symptom persists or oral medication is declined, give parenteral lorazepam, haloperidol or olanzapine. According to OHCM 1st line treatment is chlordiazepoxide.

Chlordiazepoxide should only be used at the lowest possible dose and for a maximum of up to four weeks. This will reduce the risks of developing tolerance, dependence and withdrawal].

422. A 5yo child complains of sore throat and earache. He is pyrexial. Exam: tonsils enlarged and hyperemic, exudes pus when pressed upon. What is the single most relevant dx?

- a. IM
- b. Acute follicular tonsillitis
- c. Scarlet fever
- d. Agranulocytosis
- e. Acute OM

Ans. The key is B. Acute follicular tonsillitis. [Tonsillitis is usually caused by a viral infection or, less commonly, a bacterial infection. The given case is a bacterial tonsillitis (probably caused by group A streptococcus). There are four main signs that tonsillitis is caused by a bacterial infection rather than a viral infection. They are:

a high temperature
white pus-filled spots on the tonsils
no cough
swollen and tender lymph nodes (glands).

423. A man with a fam hx of panic disorder is brought to the hosp with palpitations, tremors, sweating and muscles tightness on 3 occasions in the last 6 wks. He doesn't complain of headache and his BP is WNL. What is the single most appropriate long-term tx for him?

- a. Diazepam
- b. Olanzapine
- c. Haloperidol
- d. Fluoxetine
- e. Alprazolam

Ans. The key is D. Fluoxetine. [Recommended treatment for panic disorder is i) CBT ii) Medication (SSRIs or TCA). NICE recommends a total of seven to 14 hours of CBT to be completed within a four month period. Treatment will usually involve having a weekly one to two hour session. When drug is prescribed usually a SSRI is preferred. Antidepressants can take two to four weeks before becoming effective].

424. A 28yo man presents with rapid pounding in the chest. He is completely conscious throughout. The ECG was taken (SVT). What is the 1st med to be used to manage this condition?

- a. Amiodarone
- b. Adenosine
- c. Lidocaine
- d. Verapamil
- e. Metoprolol

Ans. The key is B. Adenosine. [Management of SVT: i) vagal manoeuvres (carotid sinus massage, valsalva manoeuvre) transiently increase AV-block, and unmask the underlying atrial rhythm. If unsuccessful then the first medicine used in SVT is adenosine, which causes transient AV block and works by i) transiently slowing ventricles to show the underlying atrial rhythm ii) cardioverting a junctional tachycardia to sinus rhythm. OHCM].

425. A 56yo woman who is depressed after her husband died of cancer 3m ago was given amitriptyline. Her sleep has improved and she now wants to stop medication but she still speaks about her husband. How would you manage her?

- a. CBT
- b. Continue amitriptyline
- c. Psychoanalysis
- d. Bereavement counselling
- e. Antipsychotic

Ans. The key is B. Continue amitriptyline. [depression is important feature of bereavement. Patient may pass sleepless nights. As this patients sleep has improved it indicate she has good response to antidepressant and as she still speaks about her husband there is chance to deterioration of her depression if antidepressant is stopped. For depressive episodes antidepressants should be continued for at least 6-9 months].

426. A 64yo man presents with a hx of left sided hemiparesis and slurred speech. He was absolutely fine 6h after the episode. What is the most appropriate prophylactic regimen?

- a. Aspirin 300mg for 2 weeks followed by aspirin 75mg
- b. Aspirin 300mg for 2 weeks followed by aspirin 75mg and dipyridamole 200mg
- c. Clopidogrel 75mg
- d. Dipyridamole 200mg
- e. Aspirin 300mg for 2 weeks

Ans. The key is B. Aspirin 300mg for 2 weeks followed by aspirin 75mg and dipyridamole 200mg. It is wrong key! Current recommended secondary prophylaxis is C. Clopidogrel 75mg.

427. A 63yo lady with a BMI=32 comes to the ED with complaints of pigmentation on her legs. Exam: dilated veins could be seen on the lateral side of her ankle. Which of the following is involved?

- a. Short saphenous vein
- b. Long saphenous vein
- c. Deep venous system
- d. Popliteal veins
- e. Saphano-femoral junction

Ans. The key is A. Short saphenous vein. [short saphenous vein travels lateral aspect of ankle while great or long saphenous vein travels medial aspect of ankle].

428. A 55yo man presents with hx of weight loss and tenesmus. He is dx with rectal carcinoma. Which risk factors help to develop rectal carcinoma except following?

- a. Smoking
- b. Family hx
- c. Polyp
- d. Prv carcinoma
- e. High fat diet
- f. High fibre diet

Ans. The key is F. High fibre diet. [except high fiber diet all others are risk factors to develop rectal carcinoma].

429. A pt presents with a painful, sticky red eye with a congested conjunctiva. What is the most suitable tx?

- a. Antibiotic PO
- b. Antihistamine PO
- c. Antibiotic drops
- d. Steroid drops
- e. IBS

Ans. The key is C. Antibiotic drops. [bacterial conjunctivitis is treated with antibiotic drops].

430. A 45yo woman complains of pain in her hands precipitated by exposure to the cold weather. She has breathlessness on walking. When she is eating, she can feel food suddenly sticking to the gullet. It seems to be in the middle of the esophagus but she can't localize exactly where it sticks. It is usually relieved with a drink of water. Choose the single most likely cause of dysphagia from the options?

- a. Esophageal carcinoma
- b. Systemic sclerosis
- c. SLE
- d. Pharyngeal carcinoma
- e. Globus hystericus

Ans. The key is B. Systemic sclerosis. [Raynods phenomena, pulmonary involvement, oesophageal dysmotility are suggestive of systemic sclerosis].

431. A 3yo child brought to the ED with a swelling over the left arm. XR shows multiple callus formation in the ribs. Exam: bruises on child's back. What is the most appropriate next step?

- a. Check child protection register
- b. Coagulation profile
- c. Skeletal survey
- d. Serum calcium
- e. DEXA scan

Ans. The key is C. Skeletal survey. [Skeletal survey is a series of x-ray which is usually used in NAI]. [after survey should think of child protection].

432. A 35yo woman has had bruising and petechiae for a week. She has also had recent menorrhagia but is otherwise well. Blood: Hgb=11.1, WBC=6.3, Plt=14. What is the single most likely dx?

- a. Acute leukemia
- b. Aplastic anemia
- c. HIV infection
- d. ITP
- e. SLE

Ans. The key is D. ITP. [As the patient is otherwise well acute leukemia, HIV and SLE is unlikely. Normal wbc count excludes aplastic anemia. So likely diagnosis is ITP].

433. A 30yo man complains of episodes of hearing music and sometimes threatening voices within a couple of hours of heavy drinking. What is the most likely dx?

- a. Delirium tremens
- b. Wernicke's encephalopathy
- c. Korsakoff's psychosis
- d. Alcohol hallucinosis
- e. Temporal lobe dysfunction

Ans. The key is D. Alcoholic hallucinosis. [Alcohol hallucinosis can occur during acute intoxication or withdrawal. It involves auditory and visual hallucinations, most commonly accusatory or threatening voices].

434. A pt had TIA which he recovered from. He has a hx of stroke and exam shows HR in sinus rhythm. He is already on aspirin 75mg and anti-HTN drugs. What other action should be taken?

- a. Add clopidogrel only
- b. Increase dose of aspirin to 300mg
- c. Add warfarin
- d. Add clopidogrel and statin
- e. Add statin only

Ans. The key is D. Add clopidogrel and statin. This is wrong key! Correct key should be E. Add statin only. [He who is already on aspirin need no change in aspirin dose. Clopidogrel is now drug of choice for secondary prevention in TIA but if someone is already on aspirin he should continue it as same dose and should be considered to shift to clopidogrel in next few visits. So for given case correct option is add statin only].

435. A 40yo woman suddenly collapsed and died. At the post-mortem autopsy, it was found that there a bleed from a berry aneurysm from the circle of Willis. In which space did the bleeding occur?

- a. Subarachnoid
- b. Subdural
- c. Extradural
- d. Subparietal
- e. Brain ventricles

Ans. The key is A. Subarachnoid.

436. A schizophrenic pt hears people only when he is about to fall asleep. What is the most likely dx?

- a. Hypnopompic hallucinations
- b. Hyponogogic hallucinations
- c. Hippocampal hallucinations
- d. Delirious hallucinations
- e. Auditory hallucinations

Ans. The key is B. Hypnogogic hallucinations.

437. A pt who came from India presents with cough, fever and enlarged cervical LN. Exam: caseating granulomata found in LN. What is the most appropriate dx?

- a. Lymphoma
- b. TB adenitis
- c. Thyroid carcinoma
- d. Goiter
- e. Thyroid cyst

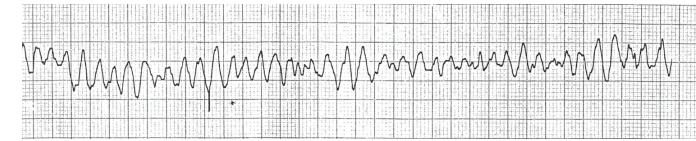
Ans. The key is B. TB adenitis. [caseating granulomata are diagnostic of TB].

438. A 44yo man comes with hx of early morning headaches and vomiting. CT brain shows ring enhancing lesions. What is the single most appropriate option?

- a. CMV
- b. Streptococcus
- c. Toxoplasmosis
- d. NHL
- e. Pneumocystis jirovecii

Ans. The key is C. Toxoplasmosis.

439. A 72yo man is found to be not breathing in the CCU with the following rhythm. What is the most likely dx?



- a. SVT
- b. VT
- c. VF
- d. Atrial fib
- e. Atrial flutter

Ans. The key is C. VF.

440. A 65yo man with difficulty in swallowing presents with an aspiration pneumonia. He has a bovine cough and fasciculating tongue. Sometimes as he swallows food it comes back through his nose. Choose the single most likely cause of dysphagia from the given option?

- a. Bulbar palsy
- b. Esophageal carcinoma
- c. Pharyngeal pouch
- d. Pseudobulbar palsy
- e. Systemic sclerosis

Ans. The key is A. Bulbar palsy. [Dysphagia, nasal regurgitation, fasciculating tongue these are features of bulbar palsy due to lower motor neuronal lesion of IX-XII nerves].

441. A 16yo teenager was brought to the ED after being stabbed on the upper right side of his back. Erect CXR revealed homogenous opacity on the lower right lung, trachea was centrally placed. What is the most probable explanation for the XR findings?

- a. Pneumothorax
- b. Hemothorax
- c. Pneumonia
- d. Tension pneumothorax
- e. Empyema

Ans. The key is B. Hemothorax. [In blunt trauma there may be hemo-pneumothorax but in sharp wound like stabbing there may occur only hemothorax].

442. A 55yo woman complains of retrosternal chest pain and dysphagia which is intermittent and unpredictable. The food suddenly sticks in the middle of the chest, but she can clear it with a drink of water and then finish the meal without any further problem. A barium meal shows a 'corkscrew esophagus'. What is the single most likely dysphagia?

- a. Esophageal candidiasis
- b. Esophageal carcinoma
- c. Esophageal spasm
- d. Pharyngeal pouch
- e. Plummer-vinson syndrome

Ans. The key is C. Esophageal spasm. [chest pain, unpredictable intermittent dysphagia and food suddenly sticks in the middle of the chest which can be cleared with a drink of water indicates uncoordinated irregular esophageal peristalsis which is characteristic of esophageal spasm! Also "cork-screw esophagus" seen in barium swallow is diagnostic of esophageal spasm].

443. A 38yo female presents with sudden loss of vision but fundoscopy is normal. She had a similar episode about 1 y ago which resolved completely within 3m. Exam: mild weakness of right upper limb and exaggerated reflexes. What is the single most appropriate tx?

- a. Pan retinal photo coagulation
- b. Pilocarpine eye drops
- c. Corticosteroids
- d. Peripheral iridectomy
- e. Surgical extraction of lens

Ans. The key is C. Corticosteroid. [Sudden loss of vision, remission and relapse of optic neuritis and focal neurological symptoms and exaggerated reflexes all points towards multiple sclerosis. Treatment option is corticosteroids].

444. A 15yo boy presents with a limp and pain in the knee. Exam: leg is externally rotated and 2cm shorter. There is limitation of flexion, abduction and medial rotation. As the hip is flexed external rotation is increased. Choose the most likely dx?

- a. Juvenile rheumatoid arthritis
- b. Osgood-schlatter disease
- c. Reactive arthritis
- d. Slipped femoral epiphysis
- e. Transient synovitis of the hip

Ans. The key is D. Slipped femoral epiphysis. [The given presentation is classic for slipped femoral epiphysis].

445. A 64yo woman has difficulty moving her right shoulder on recovering from surgery of the posterior triangle of her neck. What is the single most appropriate option?

- a. Accessory nerve
- b. Glossopharyngeal nerve
- c. Hypoglossal nerve
- d. Vagus nerve
- e. Vestibule-cochlear nerve

Ans. The key is A. Accessory nerve. [Accessory nerve lesion causes weakness of the trapezius muscle and can produce a drooping shoulder, winged scapula, and a weakness of forward elevation of the shoulder].

446. A 37yo man with an ulcer on the medial malleolus. Which of the following LN is involved?

- a. External iliac LN
- b. Pre-aortic LN
- c. Aortic LN
- d. Inguinal LN
- e. Iliac LN
- f. Submental LN
- g. Submandibular LN
- h. Deep cervical LN

Ans. The key is D. Inguinal LN.

447. A pt presents with weight loss of 5kgs despite good appetite. He also complains of palpitations, sweating and diarrhea. He has a lump in front of his neck which moves on swallowing. What is the most appropriate dx?

- a. Lymphoma
- b. TB adenitis
- c. Thyroid Ca
- d. Goiter
- e. Thyroid cyst

Ans. The key is D. Goiter.

448. A 76yo woman has become tired and confused following an influenza like illness. She is also breathless with signs of consolidation of the left lung base. What is the most likely dx?

- a. Drug toxicity
- b. Delirium tremens
- c. Infection toxicity
- d. Hypoglycemia
- e. Electrolyte imbalance

A. The key is C. Infection toxicity. [Infection toxicity or toxic shock syndrome is likely here as preceding flu like illness points towards toxin

(enterotoxin type B) from Staphylococcus aureus].

449. A young pt is complaining of vertigo whenever she moves sideways on the bed while lying supine. What would be the most appropriate next step?

- a. Head roll test
- b. Reassure
- c. Advice on posture
- d. Carotid Doppler
- e. CT

Ans. The key is A. Head roll test. [this is a case of "benign paroxysmal positional vertigo" for which the diagnosis is made by head roll test].

450. A 32yo man has OCD. What is the best tx?

- a. CBT
- b. SSRI
- c. TCA
- d. MAO inhibitors
- e. Reassure

Ans. The key is B. SSRI. This is wrong key! The correct key is CBT].

451. A 65yo woman says she died 3m ago and is very distressed that nobody has buried her. When she is outdoors, she hears people say that she is evil and needs to be punished. What is the most likely explanation for her symptoms?

- a. Schizophrenia
- b. Mania
- c. Psychotic depression
- d. Hysteria
- e. Toxic confusional state

Ans. The key is C. Psychotic depression. [Psychotic depression, also known as depressive psychosis, is a major depressive episode that is accompanied by psychotic symptoms (hallucinations, delusions). In this patient nihilistic delusion favours the diagnosis of psychotic depression. It can occur in the context of bipolar disorder or major depressive disorder].

452. A 50yo woman presents following a fall. She reports pain and weakness in her hands for several months, stiff legs, swallowing difficulties, and has bilateral wasting of the small muscles of her hands. Reflexes in the upper limbs are absent. Tongue fasciculations are present and both legs show increased tone, pyramidal weakness and hyper-reflexia with extensor plantars. Pain and temp sensation are impaired in the upper limbs. What is the most likely dx?

- a. MS
- b. MND
- c. Syringobulbia
- d. Syringomyelia
- e. Myasthenia gravis

Ans. The key is C. Syringobulbia. [In MS there are characteristic relapse and remission which is absent here; In MND there is no sensory deficit; Syringomyelia doesn't cause cranial nerve lesion and in myasthenia there is muscular weakness without atrophy. Here the features described well fits with syringobulbia].

453. Which of the following formulas is used for calculating fluids for burn pts?

- a. $4 \times \text{weight(lbs)} \times \text{area of burn} = \text{ml of fluids}$
- b. $4 \times \text{weight(kgs)} \times \text{area of burn} = \text{L of fluids}$
- c. $4 \times \text{weight(kgs)} \times \text{area of burn} = \text{ml of fluids}$
- d. $4 \times \text{weight(lbs)} \times \text{area of burn} = \text{L of fluids}$
- e. $4.5 \times \text{weight(kgs)} \times \text{area of burn} = \text{dL of fluids}$

Ans. The key is C. $4 \times \text{weight(kgs)} \times \text{area of burn} = \text{ml of fluids}$.

454. A 65yo male presents with dyspnea and palpitations. Exam: pulse=170bpm, BP=120/80mmHg. Carotid massage has been done as first instance. What is the next step of the management?

- a. Adenosine
- b. Amlodipine
- c. DC cardioversion
- d. Lidocaine
- e. Beta blocker

Ans. The key is A. Adenosine. [The likely diagnosis is SVT. 1st vagal manoeuvres, if fails iv adenosine.

• Vagal manoeuvres (carotid sinus massage, Valsalva manoeuvre) transiently increase

AV block, and may unmask an underlying atrial rhythm.

• If unsuccessful, give adenosine, which causes transient AV block; OHCM, 9th edition].

455. A 48yo farmer presented with fever, malaise, cough and SOB. Exam: tachypnea, coarse endinspiratory crackles and wheeze throughout, cyanosis. Also complaint severe weight loss. His CXR shows fluffy nodular shadowing and there is PMN leukocytosis. What is the single most appropriate dx?

- a. Ankylosing spondylitis
- b. Churg-strauss syndrome
- c. Cryptogenic organizing
- d. Extrinsic allergic alveolitis
- e. Progressive massive fibrosis

Ans. The key is D. Extrinsic allergic alveolitis.

456. A 35yo lady is admitted with pyrexia, weight loss, diarrhea and her skin is lemon yellow in color. CBC = high MCV. What is the most probably dx?

- a. Aplastic anemia
- b. Pernicious anemia
- c. Leukemia
- d. ITP
- e. Lymphoma

Ans. The key is B. Pernicious anemia. [It may be graves with pernicious anemia. Lemon yellow pallor occurs in pernicious anemia. Hyperthyroidism may cause persistently raised body temperature. Both are autoimmune disease which favours this association].

457. A 72yo woman who had a repair of strangulated femoral hernia 2 days ago becomes noisy, aggressive and confused. She is febrile, CBC normal apart from raised MCV. What is the most likely dx?

- a. Electrolyte imbalance
- b. Delirium tremens
- c. Wernicke's encephalopathy
- d. Infection toxicity
- e. Hypoglycemia

Ans. The key is B. Delirium tremens. [Electrolyte imbalance may cause confusion but not aggressiveness; infection toxicity will cause high fever, low BP, rash etc which are absent here (fever here is hyperthermia of delirium tremens which is seen in some cases). Abstinence from alcohol in the hospital caused delirium tremens (chronic alcoholism is supported by high MCV) here].

458. An old lady had UTI and was treated with antibiotics. She then developed diarrhea. What is the single most likely dx?

- a. Co-amoxiclav
- b. Piperacillin + tazobactam
- c. Ceftriaxone
- d. Vancomycin

Ans. The key is D. Vancomycin. [Pseudomembranous colitis is treated with metronidazole or vancomycin].

459. A 56yo man has symptoms of sleep apnea and daytime headaches and somnolence. Spirometry shows a decreased tidal volume and vital capacity. What is the single most appropriate dx?

- a. Ankylosing spondylitis
- b. Churg-strauss syndrome
- c. Good pasture syndrome
- d. Motor neuron disease
- e. Progressive massive fibrosis
- f. Spinal cord compression

Ans. The key is D. Motor neuron disease. [involvement of respiratory muscles in MND is associated with poor respiration causing sleep apnoea].

460. A 55yo man presents with mild headache. He has changed his spectacles thrice in 1 yr. there is mild cupping present in the disc and sickle shaped scotoma present in both eyes. What is the single most appropriate tx?

- a. Pan retinal photo coagulation
- b. Pilocarpine eye drops
- c. Corticosteroids
- d. Scleral buckling
- e. Analgesics alone

Ans. The key is B. Pilocarpine. [This is a case of open angle glaucoma, treatment is with pilocarpine].

461. A 55yo woman was found collapsed at home, paramedics revived her but in the ambulance she had a cardiac arrest and couldn't be saved. The paramedic's report tells that the woman was immobile lately due to hip pain and that they found ulcers on the medial side of ankle. She had DM and was on anti-diabetics. What is the cause of her death?

- a. Acute MI
- b. DKA
- c. Pulmonary embolism
- d. Acute pericarditis
- e. Cardiac tamponade

Ans. The key is C. Pulmonary embolism. [Immobilization due to hip pain may resulted in DVT and later pulmonary embolism. Please note ulcer in medial side indicate undiagnosed DVT and its presence favour the presence of DVT and followed by pulmonary embolism].

462. An 18yo previously well student is in his 1st year at uni. He has been brought to the ED in an agitated, deluded and disoriented state. What is the most probable reason for his condition?

- a. Drug toxicity
- b. Delirium tremens
- c. Infection toxicity
- d. Electrolyte imbalance
- e. Head injury

Ans. The key is A. Drug toxicity. [Young age and 1st yr in university is likely to point towards drug toxicity].

463. A young adult presents to the ED after a motorcycle crash. The pt has bruises around the left orbital area. GCS=13, examination notes alcoholic breath. Shortly afterwards, his GCS drops to 7. What is the single most important initial assessment test?

- a. MRI brain
- b. CT brain
- c. CXR
- d. CT angio brain
- e. Head XR

Ans. The key is B. CT brain. [Likely cause is epidural hematoma].

464. A 30yo female attends OPD with a fever and dry cough. She says that she had headache, myalgia and joint pain like one week ago. Exam: pulse=100bpm, temp=37.5C. CXR: bilateral patchy consolidation. What is the single most likely causative organism?

- a. Pneumococcal pneumonia
- b. Legionella
- c. Mycoplasma
- d. Klebsiella
- e. Chlamydia pneumonia

Ans. The key is C. Mycoplasma. [Myalgia, joint pain, bilateral patchy consolidations points towards mycoplasma pneumonia].

465. A 46yo man is being investigated for indigestion. Jejunal biopsy shows deposition of macrophages containing PAS (Periodic acid-schiff) +ve granules. What is the most likely dx?

- a. Bacterial overgrowth
- b. Celiac disease
- c. Tropical sprue
- d. Whipple's disease
- e. Small bowel lymphoma

Ans. The key is D. Whipple's disease. [periodic acid-schiff +ve granules containing macrophages in jejunal biopsy is diagnostic of whipples disease].

466. A 32yo woman of 38wks gestation complains of feeling unwell with fever, rigors and abdominal pains. The pain was initially located in the abdomen and was a/w urinary freq and dysuria. The pain has now become more generalized specifically radiating to the right loin. She says that she has felt occasional uterine tightening. CTG is reassuring. Select the most likely dx?

- a. Acute fatty liver of pregnancy
- b. Acute pyelonephritis
- c. Rount ligament stretching
- d. Cholecystitis
- e. UTI

Ans. The key is B. Acute pyelonephritis. [Fever, rigor, abdominal pain a/w frequency, dysurea and radiation to the rt loin suggests rt sided pyelonephritis].

467. A 32yo pt presents with cervical lymphadenopathy and splenomegaly. What is the single most appropriate option?

- a. Hemophilus
- b. Streptococcus
- c. Toxoplasmosis
- d. NHL
- e. Pneumocystis jirovecii

Ans. The key is D. NHL. [Here only two points are mentioned- cervical lymphadenopathy and splenomegaly! This combination makes NHL as the most likely cause though splenomegaly is a relatively uncommon feature of it!!! This combination does not fit in other options!]

468. A 62yo man who was admitted for surgery 3days ago suddenly becomes confused. His attn span is reduced. He is restless and physically aggressive and picks at his bed sheets. What single aspect of the pt's hx recovered in his notes is most likely to aid in making the dx?

- a. Alcohol consumption
- b. Head trauma
- c. Hx of anxiety
- d. Prescribed med
- e. Obvious cognitive impairment

Ans. The key is A. Alcohol consumption. [abstinence from alcohol in the hospital lead to delirium tremens].

469. A 10yo girl presents with pallor and features of renal failure. She has hematuria as well as proteinuria. The serum urea and creat are elevated. These symptoms started after an episode of bloody diarrhea 4days ago. What is the most probable dx?

- a. TTP
- b. HUS
- c. ITP
- d. HSP
- e. ARF

Ans. The key is B. HUS. [Most cases of hemolytic uremic syndrome develop in children after two to 14 days of diarrhea often bloody, due to infection with a certain strain of E. coli. Features may be i) abdominal pain, ii) pale skin, iii) hematuria and proteinuria, iv) features of renal failure like- nausea/vomiting, swelling of face, hand, feet or entire body etc. v) elevated urea and creatinine etc.].

470. A 40yo woman has had intermittent tension, dizziness and anxiety for 4months. Each episode usually resolves after a few hours. She said she takes alcohol to make her calm. She is in a loving relationship and has no probs at work or home. What is the next step in her management?

- a. Collateral info
- b. CT brain
- c. CBC
- d. LFT
- e. TFT

Ans. The key is A. Collateral info.

471. A 45yo IV drug abuser is brought into the ED with complaint of fever, shivering, malaise, SOB and productive cough. Exam: temp=39C, pulse=110bpm, BP=100/70mmHg. Inv: CXR=bilateral cavitating bronchopneumonia. What is the single most likely causative organism?

- a. Mycoplasma
- b. Staphylococcus
- c. Chlamydia pneumonia
- d. Pseudomonas
- e. PCP

Ans. The key is B. Staphylococcus. [Among the given causes Staphylococcus and PCP are recognized cause of cavitating pneumonia. This case is with productive cough which goes more with staphylococcus as PCP is not productive but rather associated with dry cough. Drug abuse can support both staphylococcus and PCP].

472. A 71yo woman looks disheveled, unkempt and sad with poor eye contact. She has recently lost her husband. Which of the following describes her condition?

- a. Anxiety
- b. Hallucination
- c. Mania
- d. High mood
- e. Low mood

Ans. The key is E. Low mood.

473. A 62yo male comes to the GP complaining of double vision while climbing downstairs. Which of the following nerve is most likely involved?

- a. Abducens nerve
- b. Trochlear nerve
- c. Oculomotor nerve
- d. Optic nerve
- e. Trigeminal nerve

Ans. The key is B. Trochlear nerve. [oculomotor may cause palsy of inferior rectus, medial rectus and superior rectus causing double vision in multiple gaze! But trochlear involving superior oblique only causes diplopia in downgaze only. So the answer is Trochlear nerve].

474. L1 level, what is the most appropriate landmark?

- a. Mcburney's point
- b. Stellate ganglion
- c. Deep inguinal ring
- d. Termination of the spinal cord
- e. Transpyloric plane

Ans. The given key is D. Termination of the spinal cord. This is a wrong key. The correct key is E. Transpyloric plane. [The termination of the spinal cord is between L1 and L2 (variable between people). L1 landmark- duodenum first part, superior mesenteric artery, hila of both kidneys, upper border of pancreas, splenic artery, pylorus and fundus of gall bladder].

475. A 32yo woman presents to the ED with headache and vomiting. She was decorating her ceiling that morning when the headache began, felt mainly occipital with neck pain. Some 2hs later she felt nauseated, vomited and was unable to walk. She also noticed that her voice had altered. She takes no reg meds and has no significant PMH. Exam: acuity, field and fundi are normal. She has upbeat nystagmus in all directions of gaze with normal facial muscles and tongue movements. Her uvulas deviated to the right and her speech is slurred. Limb exam: left arm past-pointing and dysidiadochokinesis with reduced pin prick sensation in her right arm and leg. Although

power is normal, she can't walk as she feels too unsteady. Where is the most likely site of lesion?

- a. Right medial medulla
- b. Left medial pons
- c. Left cerebellar hemisphere
- d. Right lateral medulla
- e. Left lateral medulla

Ans. The key is Left lateral medulla. [There is a loss of pain and temperature sensation on the contralateral (opposite) side of the body and ipsilateral (same) side of the face. There is associated cerebellar symptoms and other cranial nerve involvement. The condition is known as Lateral Medullary Syndrome].

476. A 28yo female presents with 1 wk hx of jaundice and 2d hx of altered sleep pattern and moods. She was dx with hypothyroidism for which she is receiving thyroxine. TFT showed increased TSH. PT=70s. What is the most probable dx?

- a. Acute on chronic liver failure
- b. Hyper-acute liver failure
- c. Autoimmune hepatitis
- d. Acute liver failure
- e. Drug induced hepatitis

Ans. The key is C. Autoimmune hepatitis. [Autoimmune hepatitis may present as acute hepatitis, chronic hepatitis, or well-established cirrhosis. Autoimmune hepatitis rarely presents as fulminant hepatic failure. One third may present as acute hepatitis marked by fever, hepatic tenderness and jaundice. Non specific features are anorexia, weight loss and behavioural change (here altered sleep pattern and moods). There may be coagulopathy (here PT=70s.) leading to epistaxis, gum bleeding etc. Presence of other autoimmune disease like hypothyroidism supports the diagnosis of autoimmune hepatitis].

477. A 55yo man has a chronic cough and sputum, night sweats and weight loss. What is the single most likely causative organism?

- a. Coagulase +ve cocci in sputum
- b. Gram -ve diplococci in sputum
- c. Gram +ve diplococci in sputum
- d. Pneumocystis carinii in sputum
- e. Sputum staining for mycobacterium tuberculosis

Ans. The key is E. Sputum staining for mycobacterium tuberculosis. [Chronic cough and sputum, night sweats and weight loss are classic features of tuberculosis].

478. A 20yo pregnant 32wks by date presents to the antenatal clinic with hx of painless vaginal bleeding after intercourse. Exam: P/A - soft and relaxed, uterus=dates, CTG=reactive. Choose the single most likely dx?

- a. Abruptio of placenta 2nd to pre-eclampsia
- b. Antepartum hemorrhage
- c. Placenta previa
- d. Preterm labor
- e. Placenta percreta

Ans. The key is C. Placenta previa.

479. A 30yo man presents to the ED with difficulty breathing. He has returned from India. Exam: throat reveals grey membranes on the tonsils and uvula. He has mild pyrexia. What is the single most relevant dx?

- a. Diphtheria
- b. IM
- c. Acute follicular tonsillitis
- d. Scarlet fever
- e. Agranulocytosis

Ans. The key is A. Diphtheria. [history of travel to india, grey membrane in tonsil and uvula, low grade fever, and dyspnoea support the diagnosis of diphtheria].

480. A 23yo man comes to the ED with a hx of drug misuse. He recognizes that he has a prb and is willing to see a psychiatrist. Which of the following terms best describes this situation?

- a. Judgement
- b. Thought insertion
- c. Thought block
- d. Mood
- e. Insight

Ans. The key is E. Insight. [in psychiatry, the patient's awareness and understanding of the origins and meaning of his attitudes, feelings, and behavior and of his disturbing symptoms (self-understanding) is known as insight].

481. A pt with hodgkins lymphoma who is under tx develops high fever. His blood results show WBC <2800 and has a chest infection. Choose the most likely tx?

- a. Co-amoxiclav
- b. Piperacillin+tazobactam
- c. Erythromycin
- d. Piperacillin+Co-amoxiclav
- e. Penicillin+tazobactam

Ans. The key is B. Piperacillin+tazobactam. [Here patients WBC is <2800, i.e. patient has leucopenia (probable neutropenia). Piperacillin/Tazobactam may be used in the management of neutropenic patients with fever suspected to be due to a bacterial infection as in patient with postchemotherapy neutropenia. Even febrile neutropenia can be seen in patients with cancer per-se!].

482. A 25yo woman presents with urinary freq, dysuria and fever. Urine microscopy shows 20-50 RBC and 10-20 WBC in each field. What is the most probable dx?

- a. Schistosomiasis
- b. Kidney trauma
- c. Ureteric calculus
- d. Bladder calculi
- e. Cystitis

Ans. The key is E. Cystitis. [Hematuria and significant WBC in urine (>10 per HPF) makes cystitis the most likely diagnosis].

483. A 65yo presents with dyspareunia after sex. She is in menopause. She complains of bleeding after sex. What is the most probable dx?

- a. Cervical ca
- b. Endometrial ca
- c. Ovarian ca
- d. Breast ca
- e. Vaginal ca

Ans. The key is B. Endometrial carcinoma. [Any post menopausal bleeding is endometrial carcinoma unless proven otherwise].

484. A 45yo man underwent an emergency splenectomy following a fall from his bicycle. He smokes 5 cigarettes/day. Post-op, despite mobile, he develops swinging pyrexia and a swollen painful left calf. His CXR shows lung atelectasis and abdominal US demonstrates a small sub-phrenic collection. What is the single most likely risk factor for DVT in this pt?

- a. Immobility
- b. Intraperitoneal hemorrhage
- c. Smoking
- d. Splenectomy
- e. Sub-phrenic collection

Ans. The key is D. Splenectomy. [Splenectomized patients have an increased risk of developing deep vein thrombosis and pulmonary embolism].

485. A 6m baby had LOC after which he had jerky movement of hands and feet. What is the most probable dx?

- a. Infantile spasm
- b. Absence
- c. Partial simple seizure
- d. Atonic seizure
- e. Partial complex

Ans. The given key is A. Infantile spasm which is a wrong key! Correct key is E. Partial complex. [In partial simple seizure there is no LOC (loss of consciousness). Infantile spasm though may be associated with occasional LOC but its nature is more generalized rather than the focal nature described here. So the likely option is E. Partial complex seizure].

486. A 24yo primigravida who is 30wk pregnant presents to the labor ward with a hx of constant abdominal pain for the last few hours. She also gives a hx of having lost a cupful of fresh blood per vagina before the pain started. Abdominal exam: irritable uterus, CTG=reactive. Choose the single most likely dx?

- a. Abruptio of placenta 2nd to pre-eclampsia
- b. Antepartum hemorrhage
- c. Placenta previa
- d. Vasa previa
- e. Revealed hemorrhage

Ans. The key is B. Antepartum hemorrhage. [Though presentation indicates abruptio placenta but abruptio placenta 2nd to pre-eclampsia can't be the option as no features are suggestive of pre-eclampsia here. So better option is B. Antepartum hemorrhage which also includes abruptio placenta. Only bleeding cannot indicate whether it is concealed, mixed or revealed].

487. A 62yo lady presents with right sided headache and loss of vision. What is the single most inv?

- a. ESR
- b. BUE
- c. CT head
- d. XR orbit
- e. IOP

Ans. The key is A. ESR. [Elderly (age 62), rt sided headache and loss of vision are suggestive of temporal arteritis where elevated ESR is highly suggestive of this diagnosis].

488. A 24yo man asks his GP for a sick note from work. He says that feels down, is lethargic and has stopped enjoying playing the piccolo (his main hobby). He was admitted to the psychiatry ward last year following an episode of overspending, promiscuity and distractibility. What is the most probable dx?

- a. Psychosis
- b. Cyclothymia
- c. Bipolar affective disorder
- d. Seasonal affective disorder

Ans. The key is C. Bipolar affective disorder. [presently patient has depression and previous features of mania makes the diagnosis of bipolar affective disorder likely].

489. A 42yo female who is obese comes with severe upper abdominal pain with a temp=37.8C. She has 5 children. What is the most probable dx?

- a. Ectopic pregnancy
- b. Ovarian torsion
- c. Hepatitis
- d. Biliary colic
- e. Cholecystitis

Ans. The key is cholecystitis. [Fat, female, fare, forty and fertile are the mnemonic for cholecystitis! Here the presentation of severe upper abdominal pain with fever along with the mnemonic features points towards the diagnosis of cholecystitis].

490. A child has just recovered from meningitis. What inv will you do before discharge?

- a. CT scan
- b. EEG
- c. Blood culture
- d. Repeat LP
- e. Hearing test

Ans. The key is E. Hearing test. [deafness is a common complication of meningitis, so hearing test is suggested before discharge].

491. A primiparous woman with no prev infection with herpes zoster is 18wk pregnant. She had recent contact with a young 21yo pt having widespread chicken pox. What is the most suitable management for the pregnant lady?

- a. Acyclovir PO
- b. Acyclovir IV +IVIG
- c. Acyclovir IV
- d. Reassure
- e. IVIG

Ans. The key is E. IVIG. [If the pregnant woman is not immune to

VZV and she has had a significant exposure, she should be offered varicella-zoster immunoglobulin (VZIG) as soon as possible. VZIG is effective when given up to 10 days after contact (in the case of continuous exposures, this is defined as 10 days from the appearance of the rash in the index case). RCOG guideline].

492. A 40yo woman presents to the GP with low mood. Of note, she has an increased appetite and has gone up 2 dress sizes. She also complains that she can't get out of bed until the afternoon. What is the most likely dx?

- a. Pseudo depression
- b. Moderate depression
- c. Severe depression
- d. Dysthymia
- e. Atypical depression

Ans. The key is E. Atypical depression. [Atypical depression is a sub-type of major depression or dysthymic disorder that involves several specific symptoms, including increased appetite or weight gain, sleepiness or excessive sleep, marked fatigue or weakness, moods that are strongly reactive to environmental circumstances, and feeling extremely sensitive to rejection].

493. An 8yo boy is clinically obese. As a baby he was floppy and difficult to feed. He now has learning difficulties and is constantly eating despite measures by his parents to hide food out of reach. What is the most probable dx?

- a. Cushing's syndrome
- b. Congenital hypothyroidism
- c. Prader Willi syndrome
- d. Lawrence moon bieder syndrome
- e. Down's syndrome

Ans. The key is C. Prader Willi syndrome. [Prader Willi syndrome rare congenital disorder characterized by learning difficulties, growth abnormalities, and obsessive eating, caused especially by the absence of certain genes normally present on the copy of chromosome 15 inherited from the father].

494. A 20yo lady is suffering from fever and loss of appetite. She has been dx with toxoplasmosis. What is the tx?

- a. Pyrimethamine
- b. Pyrimethamine + sulfadiazine
- c. Clindamycin
- d. Spiramycin
- e. Trimethoprim + sulfamethoxazole

Ans. The key is B. Pyrimethamine + sulfadiazine. [If the eye is involved, or if immunocompromised, tx option is pyrimethamine + sulfadiazine OHCM 9th edition, page 404].

495. A 68yo woman has a sudden onset of pain and loss of hearing in her left ear and unsteadiness when walking. There are small lesions visible on her palate and left external auditory meatus. What is the single most likely dx?

- a. Acute mastoiditis
- b. Cholesteatoma
- c. Herpes zoster infection
- d. Oropharyngeal malignancy
- e. OM with infusion

Ans. The key is C. Herpes zoster infection.

496. A 45yo woman has been dx with GCA and is being treated with steroids. What is the other drug that can be added to this?

- a. ACEi
- b. Beta blockers
- c. Aspirin
- d. Interferons
- e. IVIG

Ans. The key is C. Aspirin [Low dose aspirin is increasingly being recommended for people with a history of giant cell arteritis. It has been found to be effective in preventing complications of giant cell arteritis, such as heart attacks or stroke (nhs.uk)].

497. A 17yo man has acute pain and earache on the right side of his face. Temp=38.4C and has extensive pre-auricular swelling on the right, tender on palpation bilaterally. What is the single most likely dx?

- a. Acute mastoiditis
- b. Acute otitis externa
- c. Acute OM
- d. Mumps
- e. OM with effusion

Ans. The key is D. Mumps. [C/F: prodromal malaise, increased temperature, painful parotid swelling, becoming bilateral in 70%. OHCS 9th edition, page 142].

498. An ECG of an elderly lady who collapsed in the ED shows rapid ventricular rate of 220bpm, QRS=140ms. What is the most probable dx?

- a. Atrial fibrillation
- b. VT
- c. SVT
- d. Mobitz type1 2nd degree heart block
- e. Sinus tachycardia

Ans. The key is B. Ventricular tachycardia. [Dx: i) history (if IHD/MI likelihood of a ventricular arrhythmia is > 95%), ii) 12 lead ECG, and iii) lack of response to IV adenosine]. ECG findings in favour of VT:

Positive QRS concordance in chest leads

Marked left axis deviation

AV dissociation (occurs in 25%) or 2:1 or 3:1 AV block

Fusion beats or capture beats

OHCM 9th edition, page 816]. [In the given case collapse, ventricular rate of 220 and broad QRS of 140ms points towards VT].

499. A pt presents with purple papular lesions on his face and upper trunk measuring 1-2 cm across. They aren't painful or itchy. What is the single most likely dx?

- a. Kaposi's sarcoma
- b. Hairy leukoplakia
- c. Cryptosporidium
- d. CMV infection
- e. Cryptococcal infection

Ans. The key is A. Kaposi's sarcoma. [It is a spindle-cell tumour derived from capillary endothelial cells or from fibrous tissue, caused by human herpes virus. It presents as purple papules (½ to 1 cm) or plaques on skin and mucosa (any organ). It metastasizes to nodes. OHCM 9th edition, page 716].

500. A 6yo boy is clinically obese, his BMI >95th centile. He has no other medical prbs, examination is unremarkable. His mother says that she has tried everything to help him lose weight. What is the most probable dx?

- a. Cushing's syndrome
- b. Congenital hypothyroidism
- c. Down's syndrome
- d. Lawrence moon bieder syndrome
- e. Primary obesity

Ans. The key is E. Primary obesity.

501. A 20yo boy is brought by his parents suspecting that he has taken some drug. He is agitated, irritated and can't sleep. Exam: perforated nasal septum. Which of the following is the most likely to be responsible for his symptoms?

- a. Heroin
- b. Cocaine
- c. Ecstasy/MDMA/amphetamine
- d. Alcohol
- e. Opioids

Ans. The key is B. Cocaine. [drug abuse with perforated nasal septum indicates cocaine abuse].

502. For a pt presenting with Parkinson's disease which of the following drugs is most useful in the management of the tremor?

- a. Apomorphine
- b. Cabergoline
- c. Selegiline
- d. Amantadine
- e. Benzhexol

Ans. The key is E. Benzhexol. [Benzhexol (an antiparkinsonian agent of anticholinergic class) is the drug of choice in parkinson's disease induced tremor]].

503. A 26yo woman has become aware of increasing right sided hearing deficiency since her recent pregnancy. Her eardrums are normal. Her hearing tests show: BC-normal. Weber test lateralizes to the right ear. What is the single most likely dx?

- a. Encephalopathy
- b. Functional hearing loss
- c. Tympano-sclerosis
- d. Otosclerosis
- e. Sensorineural deafness

Ans. The key is D. Otosclerosis. [There are no features of encephalopathy. As Weber test is lateralized it is unlikely to be functional hearing loss. In tympanosclerosis ear drum becomes chalky white. So as the ear drum is normal it is not tympanosclerosis. Weber test is lateralized to right and deafness is also on the right. So it not sensorineural deafness but conductive deafness which makes otosclerosis as the most likely diagnosis].

504. A 58yo T1DM on anti-HTN therapy for 13yrs developed central chest pain for 45 mins while driving a/w cold sweating and dyspnea. What is the single most appropriate dx?

- a. MI
- b. Pericarditis
- c. Pulmonary embolism
- d. Costochondritis
- e. Pneumothorax

Ans. The key is A. MI. [In pericarditis pain is aggravated by inspiration or lying flat and relieved by leaning forward. Pericardial rub may present and there may be fever. In pneumothorax pain is not central but pleuritic. Pulmonary embolism=dyspnoea and pleuritic chest pain. In costochondritis localized pain/tenderness at the costochondral junction enhanced by motion, coughing, or sneezing. The given picture of central chest pain for 45 minutes (more than 30 minutes), sweating and dyspnoea with major risk factor of DM and Htn suggest the diagnosis of MI].

505. A man was brought to the ED from a shopping mall after collapsing there. He is conscious and answering questions now. His ECG shows irregular rhythm. Your choice of inv:

- a. CT
- b. MRI
- c. 24h ECG
- d. Echo

Ans. The key is D. Echo. [Echo may show clot in atrial appendage responsible for this attack of TIA secondary to atrial fibrillation].

506. A 10yo boy is clinically obese and the shortest in his class. He had a renal transplant last year and his mother is worried that he is being bullied. What is the most probable dx?

- a. Cushing's syndrome
- b. Congenital hypothyroidism
- c. Pseudocushing's syndrome
- d. Lawrence moon biedel syndrome
- e. Down's syndrome

Ans. The key is A. Cushing's syndrome. [Renal transplant--> immune suppression is needed-> exogenous steroid--> cushing syndrome. short stature--> if steroids are used in early age then they cause premature fusion of growth plate/calcification].

507. A 45yo man had cancer of head of pancreas which has been removed. He has a hx of longstanding heartburn. He now comes with rigid abdomen which is tender, temp 37.5C, BP=90/70mmHg, pulse=120bpm. What is the next step of the inv?

- a. CT abdomen
- b. XR abdomen
- c. MRI abdomen
- d. US abdomen
- e. Endoscopy

Ans. The key is B. X-ray abdomen. [X-ray abdomen will help diagnosing perforation by showing gas under diaphragm. This is a case of perforated peptic ulcer with the features of shock, abdominal rigidity and raised temperature. Stress from serious disease and operation causes the body to produce higher amounts of acid, which can irritate preexisting ulcers leading to easy perforation].

508. A 50yo man presents to the ED with acute back pain radiating down to his legs. Pain which is usually relieved by lying down and exacerbated by long walks and prolonged sitting. What inv would be the best option?

- a. MRI
- b. CT spine
- c. XR spine
- d. Dual energy XR absorptiometry
- e. Serum paraprotein electrophoresis

Ans. The key is A. MRI. [Back pain radiating to leg, pain relieved by lying down and exacerbated by long walk and prolonged sitting are characteristic of lumbar (intervertebral) disc disease].

509. What is the most appropriate antibiotic to treat uncomplicated chlamydial infection in a 21yo female who isn't pregnant?

- a. Erythromycin
- b. Ciprofloxacin
- c. Metronidazole
- d. Cefixime
- e. Doxycycline

Ans. The key is E. Doxycycline. [Doxycycline 100 mg twice-daily for seven days or a single dose of 1 g of azithromycin or Erythromycin 500 mg twice daily for 14 days or four times daily for seven days or Ofloxacin 200 mg twice-daily or 400 mg once-daily for 7 days. In pregnant Azithromycin 1g single dose is recommended then erythromycin 500 mg twice daily for fourteen days or four times daily for seven days. Then amoxicillin 500 mg three times daily for 7 days].

510. A 45yo manual worker presented with a 2h hx of chest pain radiating to his left arm. His ECG is normal. What is the single most appropriate inv?

- a. Cardiac enzymes
- b. CXR
- c. CT
- d. ECG
- e. V/Q scan

Ans. A. Cardiac enzymes.

511. A 26yo woman had bipolar disorder for 10yrs and is on Lithium for it. She is symptom free for the past 4 years. She is now planning her pregnancy and wants to know whether she should continue taking lithium. What is the single most appropriate advice?

- a. Continue lithium at the same dose and stop when pregnancy is confirmed
- b. Continue lithium during pregnancy and stop when breast feeding
- c. Reduce lithium dosage but continue throughout pregnancy
- d. Reduce lithium gradually and stop when pregnancy is confirmed
- e. Switch to sodium valproate

Ans. The key is D. Reduce lithium gradually and stop when pregnancy is confirmed.

512. A pt presents with dysphagia and pain on swallowing. He has sore mouth and soreness in the corners of the mouth. What is the single most likely dx?

- a. Kaposi's sarcoma
- b. Molluscum contagiosum
- c. CMV infection
- d. Candida infection
- e. Toxoplasma abscess

Ans. The key is D. Candida infection. [Candida is more common than CMV].

513. A 30yo lady has epistaxis for 30mins. Her Hgb is normal, MCV normal, WBC normal, PT/APTT/Bleeding time are normal. Where is the defect?

- a. Plts
- b. Coagulation factor
- c. Sepsis
- d. Anatomical
- e. RBC

Ans. The key is D. Anatomical. [bleeding time, coagulation profile, Hb%, cell count and parameters are normal. So the cause of bleeding here is anatomical defect].

514. Midpoint between the suprasternal notch and pubic symphysis. What is the single most appropriate landmark?

- Fundus of the gallbladder
- b. Mcburney's point
- c. Stellate ganglion
- d. Deep inguinal ring
- e. Transpyloric plane

Ans. The key is E. Transpyloric plane.

515. Tip of the 9th costal cartilage. What is the single most appropriate landmark?

- a. Fundus of the gallbladder
- b. Deep inguinal ring
- c. Termination of the spinal cord
- d. Transpyloric plane
- e. Vena cava opening in the diaphragm

Ans. The key is A. Fundus of the gallbladder.

516. A child complains of RIF pain and diarrhea. On colonoscopy, granular transmural ulcers are seen near the ileo-cecal junction. What should be the management?

- a. Sulfasalazine
- b. Paracetamol
- c. Ibuprofen
- d. Metronidazole

Ans. The key is A. Sulfasalazine. [Pain in RIF, diarrhea, granular transmural ulcers near the ileo-cecal junction points towards the diagnosis of Crohn's disease (predominantly ileo-cecal type)].

517. A 60yo woman presents with acute onset of bone and back pain following a rough journey in a car. Exam: tenderness at mid-thoracic vertebra with spasm, she feels better once she bends forward. What is the single most probable dx?

- a. Osteoporotic fx vertebra
- b. Myofascial pain
- c. Whiplash injury
- d. MI
- e. Pancreatitis

Ans. The key is B. Myofascial pain. [Myofascial pain syndrome is a chronic pain disorder. In myofascial pain syndrome, pressure on sensitive points in your muscles (trigger points) causes pain in seemingly unrelated parts of your body. This is called referred pain. Myofascial pain syndrome typically occurs after a muscle has been contracted repetitively].

518. A 70yo woman presents with recurrent episodes of parotid swelling. She complains of difficulty in talking and speaking and her eyes feel gritty on waking in the morning. What is the single most likely dx?

- a. C1 esterase deficiency
- b. Crohns disease
- c. Mumps
- d. Sarcoidosis
- e. Sjogrens syndrome

Ans. The key is E. Sjogrens syndrome. [parotid swelling, difficulty talking and speaking (due to dryness or less saliva), eyes feeling gritty on waking in the morning due to dryness of eye are suggestive of Sjogrens syndrome].

519. A 39yo woman has not had her period for 10months. She feels well but is anxious as her mother had an early menopause. Choose the single most appropriate initial inv?

- a. Serum estradiol conc.
- b. Serum FSH/LH
- c. Serum progesterone conc.
- d. None
- e. Transvaginal US

Ans. The key is B. Serum FSH/LH [here serum oestrogen is also important as i) low oestrogen + low FSH + low LH suggest hypothalamic amenorrhoea and ii) low oestrogen + high FSH + high LH suggest premature ovarian failure! So the main determinant is serum FSH/LH. Likely cause here is premature ovarian failure].

520. A 50yo man with DM suddenly develops persistent crushing central chest pain radiating to the neck. What is the single most appropriate dx?

- a. Angina
- b. Costochondritis (tietz's disease)
- c. Dissecting aneurysm
- d. MI
- e. Pulmonary embolism

Ans. The key is C. Dissecting aortic aneurism. Probably wrong key. Correct key should be D. MI. [The features described is insufficient and can be seen in both aortic dissection and MI. However dissection pain is described as tearing and crushing pain is often used for mi pain. Both dissection and mi can have pain radiation to neck. History of diabetes goes with mi as it is a recognized risk factor for mi. Some may argue in DM mi will be painless! But it is not always the case. MI is only painless when autonomic neuropathy becomes well established].

521 A 22yo man has rushed into the ED asking for help. He describes recurrent episodes of fearfulness, palpitations, faintness, hyperventilation, dryness of the mouth with peri-oral tingling and cramping of the hands. His symptoms last 5-10 mins and have worsened since their onset 3months ago. He is worried he may be having a heart attack. An ECG shows sinus tachycardia. What is the single most appropriate immediate intervention?

- a. High flow oxygen
- b. IV sedation
- c. Rebreathe into a paper bag
- d. Refer for anxiety management course
- e. Refer for urgent cardiology opinion

Ans. The key is C. Rebreathing into paper bag. [Patient has anxiety disorder (panic) which causes hyperventilation and CO2 washout leading to respiratory alkalosis. Symptoms will improve by rebreathing into paper bag as it will cause gradual increase of CO2 in paper bag and decrease the severity of respiratory alkalosis].

522. An 8yo boy has longstanding asthma. He has admitted with a severe episode and is tired and drowsy. He has not improved on oxygen, inhaled B2 agonist and IV hydrocortisone. CXR shows bilateral hyperinflation. He is too breathless to use a peakflow meter and is O2 sat <90%. What is the single most appropriate inv?

- a. CBG
- b. CXR
- c. CT chest
- d. Pulse oximetry
- e. Spirometry

Ans. The key is A. CBG. [It will point towards acidosis and indicate whether assisted ventilation is needed or not].

523. A man was operated for colorectal ca. His pain is relieved with morphine 60mg bd PO but now he can't swallow medications. What will be the next regimen of analgesic administration?

- a. Oxycodone
- b. Fentanyl patch
- c. Morphine 60mg IV/d
- d. Morphine 240mg IV/d

Ans. The key is B. Fentanyl patch. [Here S/C morphine 1/2 the dose of oral can be given (not present in option) or I/V morphine 1/3rd the oral dose can be given. Here I/V doses are not appropriate so we should go for B. Fentanyl patch as required morphine dose is known].

524. Just above the mid-inguinal point. What is the single most appropriate landmark?

- a. Femoral artery pulse felt
- b. Mcburney's point
- c. Stellate ganglion
- d. Deep inguinal ring
- e. Transpyloric plane

Ans. The key is D. Deep inguinal ring.

525. 5th ICS in the ant axillary line. What is the single most appropriate landmark?

- a. Apex beat
- b. Chest drain insertion
- c. Stellate ganglion
- d. Transpyloric plane
- e. Vena cava opening into the diaphragm

Ans. B. Chest drain insertion.

526. A 34yo man with MS has taken an OD of 100 tablets of paracetamol with intent to end his life. He has been brought to the ED for tx but is refusing all intervention.


- a. Assessment
- b. Evaluate pt's capacity to refuse tx
- c. Establish if pt has a prv mental illness

Ans. The key is B. Evaluate patients capacity to refuse treatment.

527. A 23yo woman with painless vaginal bleeding at 36wks pregnancy otherwise seems to be normal. What should be done next step?

- a. Vaginal US
- b. Abdominal US
- c. Vaginal exam
- d. Reassurance

Ans. The key is B. Abdominal US. This is a wrong key. The correct key is A. Vaginal US. [Painless vaginal bleeding at 36 weeks indicates the diagnosis of placenta previa, which can be better evaluated by vaginal US].

 [sogc.org/wp-content/uploads/2013/01/189E-CPG-March-2013.pdf](https://www.sogc.org/wp-content/uploads/2013/01/189E-CPG-March-2013.pdf)

Benefits, Harms, and Costs: Accurate diagnosis of placenta previa may reduce hospital stays and unnecessary interventions.

Recommendations:

1. Transvaginal sonography, if available, may be used to investigate placental location at any time in pregnancy when the placenta is thought to be low-lying. It is significantly more accurate than transabdominal sonography, and its safety is well established. (11–2A)

528. A 29yo lady admitted with hx of repeated UTI now developed hematuria with loin pain. What is the most probable dx?

- a. Acute pyelonephritis
- b. Chronic pyelonephritis
- c. UTI
- d. Bladder stone

Ans. The key is A. Acute pyelonephritis. [In a patient having hematuria and loin pain with history of repeated UTI suggest acute pyelonephritis].

529. A 45yo chronic smoker attends the OPD with complaints of persistent cough and copious amount of purulent sputum. He had hx of measles in the past. Exam: finger clubbing and inspiratory crepitations on auscultation. What is the single most likely dx/

- a. Interstitial lung disease
- b. Bronchiectasis
- c. Asthma
- d. COPD
- e. Sarcoidosis

Ans. The key is B. Bronchiectasis. [Persistent cough with copious purulent sputum and finger clubbing points towards the diagnosis of bronchiectasis. Severe lung infections such as tuberculosis (TB), whooping cough, pneumonia or measles can damage the airways at the time of infection. Bronchiectasis may then develop].

530. A 68yo man has had malaise for 5 days and fever for 2 days. He has cough and there is dullness to percussion at the left lung base. What is the single most appropriate inv?

- a. Bronchoscopy
- b. CXR
- c. CT
- d. MRI
- e. V/Q scan

Ans. The key is B. CXR. [Given presentation is suggestive of pneumonia for which investigation of choice is CXR].

531. A 5yo child was admitted with hx of feeling tired and lethargic all the time, bleeding gums and sore throat since the last 3months. Exam: hepatosplenomegaly. What is the most probable dx?

- a. ALL
- b. AML
- c. CML
- d. CLL
- e. Lymphoma

Ans. The key is A. ALL. [Commonest leukemia in children is ALL. Bleeding gums (low platelet), feeling tired and lethargic, sorethroat,

hepatosplenomegally all are well known features of ALL].

532. A 65yo man presents with back pain. Exam: splenomegaly and anemia. Blood: WBC=22, Hgb=10.9, Plt=100, ESR=25. He has been found to have Philadelphia chromosome. What is the single most likely dx?

- a. ALL
- b. AML
- c. CML
- d. CLL
- e. Lymphoma

Ans. The key is C. CML. [anaemia, raised WBC count, low platelet (platelet may be variable) are known features of CML, splenomegaly (particularly if massive) is very suggestive of CML and Philadelphia chromosome is characteristic of CML].

533. A 24yo woman has 8wk amenorrhea, right sided pelvic pain and vaginal bleeding. She is afebrile. Peritonism is elicited in the RIF. Vaginal exam reveals right sided cervical excitation. What is the most probable dx?

- a. Ectopic pregnancy
- b. Salpingitis
- c. Endometriosis
- d. Ovarian torsion
- e. Ovarian tumor

Ans. The key is A. Ectopic pregnancy. [Salpingitis, Endometriosis, ovarian torsions do not associated with amenorrhoea. In ovarian tumour three main features are i) increased abdominal size and persistent bloating (not bloating that comes and goes) ii) persistent pelvic and abdominal pain iii) difficulty eating and feeling full quickly, or feeling nauseous. Patient with pelvic pain and vaginal bleeding, peritonism and cervical excitation obviously points towards Ectopic pregnancy].

534. A 64 yo woman has been treated for breast cancer with tamoxifen. What other drug should be added to her tx regime?

- a. Bisphosphonates
- b. Calcium
- c. Vit D
- d. Calcitonin
- e. Phosphate binders

Ans. The key is A. Bisphosphonates. [bisphosphonates reduce the risk of bone metastasis in cancers and is normally taken as adjuvant therapy in many types of tumours including breast cancer. Plus it prevents bone resorption].

535. A 26yo woman with regular menses and her 28yo partner comes to the GP surgery complaining of primary infertility for 2yrs. What would be the single best investigation to see whether she is ovulating or not?

- a. Basal body temp estimation
- b. Cervical smear
- c. Day2 LH and FSH
- d. Day21 progesterone
- e. Endometrial biopsy

Ans. The key is D. Day 21 progesterone. [Mid-luteal progesterone level to assess ovulation: If low, it may need repeating, as ovulation does not occur every month. The blood test is taken seven days before the anticipated period, that is on day 21 of a 28-day cycle. However, this day will need to be adjusted for different lengths of cycle. Ref: patient.co.uk].

536. A 10yo boy who takes regular high dose inhaled steroids for his longstanding asthma has been advised to use bronchodilators to control his acute attacks. His parents are unsure when should he use his bronchodilator. What is the single most appropriate inv?

- a. CXR
- b. None
- c. Peak flow rate diary
- d. Pulse oximetry

Ans. The key is C. Peak flow rate diary. [Peak flow rate diary shows diurnal variation. This diary shows when the bronchoconstriction remains worse and guides to use bronchodilators prior to that times].

537. A woman presented with blurred vision and intermittent clumsiness for 3m. Reflexes are brisk in her arm and optic disc is pale. What is the single most appropriate test to confirm dx?

- a. CSF analysis
- b. CT
- c. MRI
- d. EEG
- e. EMG

Ans. The key is C. MRI. [Features are suggestive of multiple sclerosis. Investigation of choice is gadolinium enhanced MRI].

538. A 63yo man presents after having a seizure. Exam: alert, orientated, inattention on the left side and hyperreflexia of the arm. What is the most probable dx?

- a. Cerebral tumor
- b. Pituitary adenoma
- c. Cerebellar abscess
- d. Huntingtons chorea
- e. Parkinsonism

Ans. The key is A. Cerebral tumour.

539. A 40yo man with a 25y hx of smoking presents with progressive hoarseness of voice, difficulty swallowing and episodes of hemoptysis. He mentioned that he used to be a regular cannabis user. What is the single most likely dx?

- a. Nasopharyngeal cancer
- b. Pharyngeal carcinoma
- c. Sinus squamous cell carcinoma
- d. Squamous cell laryngeal cancer
- e. Hypopharyngeal tumor

Ans. The key is D. Squamous cell laryngeal cancer.

Chronic hoarseness is the most common early symptom.

Other symptoms of laryngeal cancer include pain, dysphagia, a lump in the neck, sore throat, earache or a persistent cough.

Patients may also describe breathlessness, aspiration, haemoptysis, fatigue and weakness, or weight loss.

(Patient.co.uk)

540. A 30yo lady complains of intermittent diarrhea, chronic abdominal and pelvic pain and tenesmus. Sometimes she notices blood in her stool. Select the most likely cause leading to her symptoms?

- a. Inflammatory bowel disease
- b. Diverticulosis
- c. Irritable bowel disease
- d. Adenomyosis
- e. UTI

Ans. The key is A. Inflammatory bowel disease. [Tenesmus excludes diverticulitis, occasional blood in stool excludes irritable bowel disease. Features are not consistent with adenomyosis or UTI but suggestive of inflammatory bowel disease].

541. A 50yo lady with weak limbs when examined was found to have burn marks on finger tips, wasted and weak hands with diminished reflexes. She also has weak spastic legs and dissociated sensory loss. What is the dx?

- a. MS
- b. Syringomyelia
- c. MND
- d. Guillain-Barre
- e. Friedreich's ataxia

Ans. The key is B. Syringomyelia. [weak limbs, burn mark on fingertip (as pain and temperature sensation are lost due to spinothalamic tract damage), wasted and weak hands with diminished reflexes, weak spastic legs with dissociated sensory loss are features suggestive of

Syringomyelia].

Common features are given below:

Sensory features: 1) loss of pain and temperature sensation 2) sensory loss is experienced over the arms, shoulders and upper body 3) light touch, vibration and position senses in the feet are affected as the syrinx enlarges into the dorsal column.

Motor features: (when lower motor neurons of the anterior horn cells are affected) 1) muscle wasting and weakness begins in the hands and then affects the forearms and shoulders. 2) tendon reflexes are lost. Autonomic involvement like bladder and bowel can occur. [patient.co.uk]

542. A 23yo woman is being followed up 6wks after a surgical procedure to evacuate the uterus following a miscarriage. The histology has shown changes consistent with a hydatidiform mole. What is the single most appropriate inv in this case?

- a. Abdominal US
- b. Maternal karyotype
- c. Paternal blood group
- d. Serum B-HCG
- e. Transvaginal US

Ans. The key is D. Serum -HCG. [When you are first diagnosed with a hydatidiform mole, your hCG level will be raised. When the hydatidiform mole is treated (removed), the hCG level will usually return to a normal, non-pregnant amount and should remain so. If you develop GTN, the hCG level can remain elevated or continue to rise further. So, this blood test is a good way to check for the possible development of GTN (Gestational trophoblastic neoplasia).

543. A 67yo man with hx of weight loss complains of hoarseness of voice. CT reveals opacity in the right upper mediastinum. He denied any hx of difficulty breathing. What is the single most appropriate inv?

- a. Laryngoscopy
- b. Bronchoscopy
- c. LN biopsy
- d. Bronchoalveolar lavage
- e. Barium swallow

Ans. The key is C. Lymph node biopsy. [There is weight loss and there is an opacity in right upper mediastinum. May indicate enlarged lymph node or lymphoma causing pressure on right recurrent laryngeal nerve resulting in hoarseness. As CT didn't reveal any bronchial lesion and no breathing difficulty it is unlikely to be a bronchial pathology. So CT guided lymph node biopsy can reveal the diagnosis].

544. A 52yo man whose voice became hoarse following thyroid surgery 1 wk ago shows no improvement. Which anatomical site is most likely affected?

- a. Bilateral recurrent laryngeal nerve
- b. Unilateral recurrent laryngeal nerve
- c. Unilateral external laryngeal nerve
- d. Bilateral external laryngeal nerve
- e. Vocal cords

Ans. The key is B. Unilateral recurrent laryngeal nerve.

545. A 73yo male presents with a 12m hx of falls. His relatives have also noticed rather strange behavior of late and more recently he has had episodes of enuresis. Exam: disorientation to time and place, broad-based, clumsy gait. What is the most probable dx?

- a. Dementia
- b. Pituitary adenoma
- c. CVD
- d. Syringomyelia
- e. Normal pressure hydrocephalus

Ans. The key is E. Normal pressure hydrocephalus. [hx of falls and broad based clumsy gait (balance and gait disturbance), strange behavior and disorientation to time and place (due to dementia), episodes of enuresis (urinary incontinence) points towards normal pressure hydrocephalus. Classic triad of normal pressure hydrocephalus: i) gait abnormality ii) urinary incontinence and iii) dementia].

546. A 75yo nursing home resident complains of headache, confusion and impaired vision for 4days. She has multiple bruises on her head. What is the most likely cause of confusion in this pt/

- a. Alcohol intoxication
- b. Infection
- c. Subdural hematoma
- d. Hypoglycemia
- e. Hyponatremia

Ans. The key is C. Subdural hematoma. [elderly patient with multiple bruises on her head suggest head injury which can lead to subdural hematoma. Headache, confusion and impaired vision for 4 days indicate subacute subdural hematoma (three phases i) acute ii) subacute 3 – 7 days and iii) chronic 2 – 3 weeks]. Symptoms of subdural hematoma: a headache that keeps getting worse feeling and being sick/confusion personality changes, such as being unusually aggressive or having rapid mood swings feeling drowsy and finding it difficult to keep your eyes open

speech problems, such as slurred speech problems with your vision, such as double vision paralysis (loss of movement) on one side of the body problems walking and frequent falls seizures (fits) loss of consciousness

[Reference: nhs.uk]

547. A 50yo woman returned by air to the UK from Australia. 3days later she presented with sharp chest pain and breathlessness. Her CXR and ECG are normal. What is the single most appropriate inv?

- a. Bronchoscopy
- b. Cardiac enzymes
- c. CT
- d. MRI
- e. Pulse oximetry
- f. V/Q scan
- g. CTPA

Ans. The key is G. CTPA. [Prolonged plane journey is a recognized risk factor for thromboembolism and hence pulmonary embolism also! Sharp chest pain and breathlessness after 3 days of plane journey is highly suggestive of pulmonary embolism the investigation of choice for which is CTPA].

548. A tall thin young man has sudden pain in the chest and becomes breathless while crying. What is the single most appropriate inv?

- a. Cardiac enzymes
- b. CXR
- c. CT
- d. ECG
- e. V/Q scan

Ans. The key is B. CXR. [tall thin young men are particularly prone to develop pneumothorax. Sudden pain and breathlessness in this young man are highly suggestive of pneumothorax. So investigation of choice is CXR].

549. A 21yo woman has had several sudden onset episodes of palpitations, sweating, nausea and overwhelming fear. On one occasion she was woken from sleep and feared she was going insane. There is no prev psychiatric disorder. What is the most probable dx?

- a. Pheochromocytoma
- b. Panic disorder
- c. GAD
- d. Phobia
- e. Acute stress disorder

Ans. The key is B. Panic disorder. [here closest d/d to panic disorder is pheochromocytoma. But in pheochromocytoma the most important feature is resistant hypertension and other important features are headache and abdominal pain which all are absent here. Moreover overwhelming fear is more suggestive of panic disorder. Hence here the diagnosis is B. Panic disorder].

550. A 55yo woman with a persistent cough and hx of smoking develops left sided chest pain exacerbated by deep breathing with fever and localized crackles. What is the single most appropriate dx?

- a. Dissecting aneurysm
- b. Pericarditis
- c. Pneumonia
- d. Pneumothorax
- e. Pulmonary embolism

Ans. The key is C. Pneumonia. [chest pain exacerbated with deep breathing, fever and localized crackles are highly suggestive of pneumonia].

551. A 40yo woman complains of dysphagia for both solids and liquids. She sometimes suffers from severe retrosternal chest pain. Barium swallow reveals a dilated esophagus which tapers to a fine distal end. What is the best management strategy?

- a. Reassurance
- b. Antispasmodics
- c. Dilatation of the LES
- d. Endoscopic diverticulectomy
- e. Barium swallow

Ans. The key is C. Dilatation of LES. [Dysphagia for both solids and liquids suggest neuromuscular dysphagia while dysphagia only for solid suggests mechanical obstruction. Here features are consistent with achalasia for which lower oesophageal sphincter dilation (balloon dilatation) is a treatment modality].

552. A 38yo female G4 at 32wks of pregnancy presented with thick white marks on the inside of her mouth for 3wks. Her mouth including her tongue appeared inflamed on examination. She smokes 20 cigarettes/day despite advice to quit. She attends her ANC regularly. What is the most probable dx?

- a. Lichen planus
- b. Aphthous ulcer
- c. Smoking
- d. Candidiasis
- e. Leukoplakia

Ans. The key is D. Candidiasis. [lichen planus may have lace like appearance and not thick white mark. Aphthous ulcer has yellowish floor and surrounded by erythematous halo. Smoking may cause tongue coating but not like thick white mark on the inside of mouth.

Leukoplakia is with raised edges/Bright white patches and sharply defined and cannot be rubbed out like candida patch; here also inflamed tongue points towards infection. So candidiasis is the most probable option].

553. A 69yo woman has had a stroke. Her left upper and lower limbs are paralyzed and she is having difficulty in speaking. Which anatomical site is most likely affected?

- a. Hippocampus
- b. Cerebellum
- c. Internal capsule
- d. Thalamus
- e. Brain stem

Ans. The key is C. internal capsule. [Hippocampal lesion causes mainly memory impairment. Cerebellum has its diagnostic features that is not present here. Thalamic lesion can lead to impairment of arousal, orientation, learning and memory, facial paresis, language deficit, hemispatial neglect, hemisensory loss, hemiparesis, hemiataxia and visual field defect. Brainstem stroke causes impaired consciousness, disorder of blood pressure, and breathing abnormality. Given picture is typical of lesion in internal capsule].

554. A 72yo man brought to the ED with onset of paraplegia following a trivial fall. He was treated for prostatic malignancy in the past. What is the single most probable dx?

- a. Paget's disease
- b. Osteoporotic fx of vertebra
- c. Secondary
- d. Multiple myeloma
- e. Spondylosis

Ans. The key is C. Secondary. [In male osteoporotic fracture is less common. As patient had prostatic malignancy pathological fracture from secondary metastasis to bone (here vertebra leading to paraplegia) is more common].

555. A 14yo girl has developed an itchy, scaly patch on her scalp. She had a similar patch that cleared spontaneously 2yrs ago. Her aunt has a similar undiagnosed rash on the extensor aspects of her elbows and knees. What is the single most likely dx?

- a. Eczema
- b. Fungal infection
- c. Impetigo
- d. Lichen planus
- e. Psoriasis

Ans. The key is E. Psoriasis. [itchy, scaly patch on scalp are classic presentation of scalp psoriasis. Her aunts presentations (similar rash on

extensor aspects of her elbow and knees) are suggestive of psoriasis. It is thought to be an immunological disease].

556. A pt after transurethral prostatic biopsy. What electrolyte imbalance can he develop?

- a. Hyperkalemia
- b. Hyponatremia
- c. Hypocalcemia
- d. Hypernatremia
- e. Hypercalcemia

Ans. The key is B. Hyponatremia. [Use of fluid for bladder irrigation may lead to dilutional hyponatremia].

557. A 28yo woman has been admitted at 38wks gestation. Her BP=190/120mmHg and proteinuria +++. Immediately following admission she has a grand-mal seizure. What is the single most appropriate initial management?

- a. Diazepam IV
- b. Fetal CTG
- c. Hydralazine IV
- d. Immediate delivery
- e. Magnesium sulphate IV

Ans. The key is E. Magnesium sulphate IV. [patient has established eclampsia. So she should be treated with Magnesium sulphate as with 4g magnesium sulfate in 100mL 0.9% saline IVI over 5min + maintenance IVI of 1g/h for 24h. Beware depressed respiration. If recurrent seizure give 2g IVI magnesium sulfate over 5 min. Check tendon reflexes and respiratory rate every 15min. Stop magnesium sulfate IVI if respiratory rate <14/min or tendon reflex loss, or urine output <20mL/h]. [OHCS, 9th edition, page 49].

558. A 27yo woman had pre-eclampsia and was delivered by C-section. She is now complaining of RUQ pain different from wound pain. What inv will you do immediately?

- a. Coagulation profile
- b. LFT
- c. Liver US
- d. MRCP
- e. None

Ans. The key is B. LFT. [In a post caesarian patient having pre-eclampsia RUQ pain different from wound pain points towards the diagnosis of HELLP syndrome. So immediate investigation to be done is LFT]. [OHCS, 9th edition, page 26].

559. A 10yo girl has been referred for assessment of hearing as she is finding difficulty in hearing her teacher in the class. Her hearing tests show: BC normal, symmetrical AC threshold reduced bilaterally, weber test shows no lateralization. What is the single most likely dx?

- a. Chronic perforation of tympanic membrane
- b. Chronic secretory OM with effusion
- c. Congenital sensorineural deficit
- d. Otosclerosis
- e. Presbycusis

Ans. The key is B. Chronic secretory OM with effusion.

560. A thin 18yo girl has bilateral parotid swelling with thickened calluses on the dorsum of her hand. What is the single most likely dx?

- a. Bulimia nervosa
- b. C1 esterase deficiency
- c. Crohn's disease
- d. Mumps
- e. Sarcoidosis

Ans. The key is A. Bulimia nervosa. [18 year thin girl, bilateral parotid swelling and thickened calluses on the knuckles from self induced vomiting are suggestive of Bulimia nervosa. Bulimia often is associated with bilateral parotid swelling (parotid hypertrophy)].

561. A 48yo presents with severe chest pain since the last 40mins. In the ED he is given oxygen, GTN, morphine. ECG=ST elevation. Bloods=increased troponin levels. What is the next step of management?

- a. Beta blockers
- b. Percutaneous angiography
- c. Anticoagulant & heparin
- d. Clopidogrel
- e. Aspirin

Ans. The key is B. Percutaneous angiography. This is a wrong key! Correct key is E. Aspirin. [In any case of IHD, most important initial management is aspirin].

562. A 34yo female presents with a foul smelling discharge. What set of organisms are we looking for to be treated here?

- a. Chlamydia, gonorrhea
- b. Chlamydia, gardenella
- c. Chlamydia, gonorrhea, gardenella
- d. Gonorrhea, gardenella
- e. Gardenella only

Ans. The key is E. Gardenella only. [Here foul smelling discharge is

caused by gardenella. So most acceptable answer is E. Gardenella only].

563. A 6wk formula fed baby boy is found at the child health surveillance to be deeply jaundiced. His weight gain is poor and his stools are pale. What is the most likely dx?

- a. Galactosemia
- b. Biliary atresia
- c. G6PD deficiency
- d. Rh incompatibility
- e. Congenital viral infection

Ans. The key is B. Biliary atresia. [Deep jaundice at 6th week with pale stools suggests obstructive jaundice. So most likely diagnosis here is biliary atresia].

564. A 45yo man with colon cancer now develops increased thirst, increased frequency in urination and weight loss. His fasting blood glucose=9mmol/L. what is the most appropriate management?

- a. Oral hypoglycemic
- b. Insulin long acting
- c. Short acting insulin before meal
- d. IV insulin
- e. Subcutaneous insulin

Ans. The key is A. Oral hypoglycemic. [Increased thirst and increased frequency in urination along with weight loss is suggestive of DM supported by fasting blood glucose of 9 mmol/L. At the age of 45 most likely type of diabetes is NIDDM or type 2 DM which is treated by oral hypoglycemic agents].

565. A 34yo man from Zimbabwe is admitted with abdominal pain to the ED. An AXR reveals bladder calcification. What is the most likely cause?

- a. Schistosoma mansoni
- b. Sarcoidosis
- c. Leishmaniasis
- d. TB
- e. Schistosoma hematobium

Ans. The key is E. Schistosoma hematobium. [Bladder involvement is caused by Schistosoma hematobium while Schistosoma mansoni causes intestinal disease].

566. A 6yo came with full thickness burn. He is crying continuously. What is the next step of management?

- a. Refer to burn unit
- b. IV fluid stat
- c. Antibiotic
- d. Analgesia
- e. Dressing

Ans. The key is analgesia. This is a wrong key. Correct key should be B. IV fluid stat. [Here already mentioned full thickness burn which is painless. Child often cry from anxiety for hypoxaemia and hypovolaemia rather than pain. The patient then responds better to oxygen or increased fluid administration rather than to narcotic analgesics. Ref: patient.info].

567. A 78yo nursing home resident is revived due to the development of an intensely itchy rash. Exam: white linear lesions are seen on the wrists and elbows and red papules are present on the penis. What is the most appropriate management?

- a. Topical permethrin
- b. Referral to GUM clinic
- c. Topical betnovate
- d. Topical ketoconazole
- e. Topical selenium sulphide/hydrocortisone

Ans. The key is A. Topical permethrin. [The intensely itchy rash, scratch marks and burrows on wrist and elbow red papules on penis are suggestive of scabies. Topical permethrin are used to treat it].

568. A 4yo has earache and fever. Has taken paracetamol several times. Now it's noticed that he increases the TV volume. His pre-school hearing test shows symmetric loss of 40db. What is the most likely dx?

- a. OM with effusion
- b. Otitis externa
- c. Cholesteatoma
- d. CSOM
- e. Tonsillitis

Ans. The key is A. OM with effusion.

569. A pt presents with gradual onset of headache, neck stiffness, photophobia and fluctuating LOC. CSF shows lymphocytosis but no organism on gram stain. CT brain is normal. What is the single most likely dx?

- a. Hairy leukoplakia
- b. TB
- c. CMV infection
- d. Candida infection
- e. Cryptococcal infection

Ans. The key is B. TB. [Fungal meningitis can also present like this but it is much more rare. Moreover negative gram stain excludes fungal cause here. Hence TB meningitis is more acceptable answer].

570. An 18m boy has been brought to the ED because he has been refusing to move his left arm and crying more than usual for the past 24h. He has recently been looked after by his mother's new bf while she attended college. Assessment shows multiple bruises and a fx of the left humerus which is put in plaster. What is the single most appropriate next step?

- a. Admit under care of pediatrician
- b. Discharge with painkillers
- c. Follow up in fx clinic
- d. Follow up in pediatric OPD
- e. Follow up with GP

Ans. The key is A. Admit under care of pediatrician. [This is NAI. So the child cannot be handover to the risk again and should be admitted to protect him from further injury done by mothers boyfriend while serial x-rays and relevant investigations done and asked for child protection unit's help].

571. A 74yo female presents with headache and neck stiffness to the ED. Following a LP the pt was started on IV ceftriaxone. CSF culture = listeria monocytogenes. What is the appropriate tx?

- a. Add IV amoxicillin
- b. Change to IV amoxicillin + gentamicin
- c. Add IV ciprofloxacin
- d. Add IV co-amoxiclav
- e. Continue IV ceftriaxone as mono-therapy

Ans. The key is B. Change to IV amoxicillin + gentamycin. [From the given option B is the most acceptable. However Ampicillin + gentamycin is the drug combination of choice].

572. A pt presents with fever, dry cough and breathlessness. He is tachypneic but chest is clear. Oxygen saturation is normal at rest but drops on exercise. What is the single most likely dx?

- a. CMV infection
- b. Candida infection
- c. Pneumocystis carinii infection
- d. Cryptococcal infection
- e. Toxoplasma abscess

Ans. The key is C. Pneumocystis carinii infection. [Fever, dry cough, breathlessness, tachypnoea with clear chest is seen in pneumocystis carinii pneumonia. Normal oxygen saturation which drops on exercise is characteristic of pneumocystis carinii pneumonia].

573. A 14yo boy fell and hit his head in the playground school. He didn't lose consciousness. He has swelling and tenderness of the right cheek with a subconjunctival hemorrhage on his right eye. What is the most appropriate initial inv?

- a. CT brain
- b. EEG
- c. MRI
- d. Skull XR
- e. Facial XR

Ans. The key is E. Facial X-ray. [There is no sign of basal fracture (Panda sign is suggestive of basal fracture, not subconjunctival hemorrhage- unless posterior border of hemorrhage is not visible) and no indication of CT scan (there are some criteria for CT scan which are not fulfilled here)].

Selection of children (under 16 years) for CT scan
CT scan of the brain within one hour (with a written radiology report within one hour of the scan being undertaken):
<ul style="list-style-type: none"> Clinical suspicion of non-accidental injury Post-traumatic seizure (no past medical history of epilepsy) GCS <14 on initial assessment or, if <1 year, GCS <15 GCS <15 two hours after injury Suspected open or depressed skull fracture or tense fontanelle Signs of base of skull fracture* Focal neurological deficit Aged <1 - bruise, swelling or laceration >5 cm on the head

574. A 15m child is due for his MMR vaccine. There is a fam hx of egg allergy. He is febrile with acute OM. What is the single most appropriate action?

- a. Defer immunization for 2wks
- b. Don't give vaccine
- c. Give half dose of vaccine
- d. Give paracetamol with future doses of the same vaccine
- e. Proceed with standard immunization schedule

Ans. The key is A. Defer immunization for 2 wks.

575. A 33yo lady with Hodgkin's lymphoma presents with temp=40C, left sided abdominal pain and lymphadenitis. Blood was taken for test. What will you do next?

- a. Wait for blood test
- b. Start broad spectrum IV antibiotics
- c. Oral antibiotics
- d. CBC
- e. Monitor pyrexia

Ans. The key is B. Start broad spectrum IV antibiotics. [The patient is immunocompromised with signs of infection (temp=40°C, left sided abdominal pain and lymphadenitis) broad spectrum IV antibiotic should be started empirically while waiting for blood reports].

576. A 40yo man with marked weight loss over the preceding 6m has bilateral white, vertically corrugated lesion on the lateral surfaces of the tongue. What is the single most likely dx?

- a. C1 esterase deficiency
- b. Crohns disease
- c. HIV disease
- d. Sarcoidosis
- e. Sjogren's syndrome

Ans. The key is C. HIV disease. [The lesion described is leukoplakia which is likely association of HIV disease].

577. A 3m baby was miserable and cried for 2h following his 1st routine immunization with DTP, HiB and meningitis. What is the single most appropriate action?

- a. Defer immunization for 2wks
- b. Don't give vaccine
- c. Give half dose of vaccine
- d. Give paracetamol with future doses of the same vaccine
- e. Proceed with standard immunization schedule

Ans. The key is E. Proceed with standard immunization schedule.

578. A 65yo man with HTN develops gingival hyperplasia. What is the single most likely dx?

- a. ACEi
- b. Beta blockers
- c. Crohns disease
- d. Nifedipine
- e. Sarcoidosis

Ans. The key is D. Nifedipine. [Gingival hyperplasia is a recognized side effect of calcium channel blockers].

579. A 65yo woman is undergoing coronary angiography. What measure will protect her kidneys from contrast?

- a. Furosemide
- b. Dextrose
- c. 0.45% saline
- d. 0.9% saline

Ans. The key is D. 0.9% saline.

580. An 83yo woman who is a resident in a nursing home is admitted to hospital with a 4d hx of diarrhea. She has had no weight loss or change in appetite. She has been on analgesics for 3wks for her back pain. She is in obvious discomfort. On rectal exam: fecal impaction. What is the single most appropriate immediate management?

- a. Codeine phosphate for pain relief
- b. High fiber diet
- c. Oral laxative
- d. Phosphate enema
- e. Urinary catheterization

Ans. The key is D. Phosphate enema. [In fecal impaction oral laxative is not the choice but phosphate enema is the best option here].

581. A 26yo woman being treated for a carcinoma of the bronchus with steroids presents with vomiting, abdominal pain and sudden falls in the morning. What is the most specific cause for her symptoms?

- a. Steroid side effects
- b. Postural hypotension
- c. Adrenal insufficiency
- d. Conn's disease
- e. Cushing's disease

Ans. The key is C. Adrenal insufficiency. [Patients on steroid develop suppression of hypothalamic pituitary adrenal axis and frequently may lead to adrenal insufficiency (here vomiting, abdominal pain and sudden falls in the morning secondary to postural hypotension on getting

up from bed points towards the diagnosis of adrenal insufficiency)].

582. A 78yo woman presents with unilateral headache and pain on chewing. ESR=70mm/hr. She is on oral steroids. What is the appropriate additional tx?

- a. Bisphosphonates
- b. HRT
- c. ACEi
- d. IFN
- e. IV steroids

Ans. The key is A. Bisphosphonates. [The elderly lady with giant cell arteritis is getting high dose steroid which can lead to demineralization and osteopenia or osteoporosis. So to prevent this bisphosphonates are given].

583. A 30yo man is suffering from fever, rash and photophobia. Doctors are suspecting he is suffering from meningitis. Which is the best medication for this condition?

- a. Ampicillin
- b. Cefotaxime
- c. Tetracycline
- d. Acyclovir
- e. Dexamethasone

Ans. The key is B. Cefotaxime. [The patient is getting probable meningococcal meningitis. Before confirming the diagnosis suggested treatment is, where the organism is unknown:

• <55yrs: cefotaxime 2g/6h slow IV.

• >55yrs: cefotaxime as above + ampicillin 2g IV/4h (for Listeria). So in given case Cefotaxime is the option. Ref: OHCM, 9th edition, page 832].

584. A 15yo girl was admitted with anemia, chest infection and thrombocytopenia. She was treated and her symptoms had regressed. She was brought again with fever and the same symptoms a few days later. She also seems to have features of meningitis. What is the most likely dx?

- a. AML
- b. ALL
- c. Aplastic anemia
- d. CML
- e. CLL

Ans. The key is B. ALL. [The age supports the diagnosis of ALL along with the given picture. Same picture can happen in aplastic anaemia but there is not a single factor mentioned in favour of it. So ALL can be taken as best option in the given scenario].

585. A pt was admitted to the ED after a head injury. When examined on arrival his GCS=15 and then at night his GCS deteriorated to 12. What investigation should be done?

- a. CT head
- b. XR skull
- c. IV mannitol
- d. Drill a burr hole
- e. Shift to OR

Ans. The key is A. CT head. [Initial GCS 15 followed by later GCS 12 are suggestive of intracranial haemorrhage. So the best investigation to be done is CT head].

586. A 4yo boy who prv had normal hearing, has a mild earache relieved by paracetamol. He has been noticed to turn up the vol on the TV. He has bilateral dull tympanic membranes. His preschool hearing test shows symmetrical loss of 40dB. What is the single most likely dx?

- a. Acute otitis externa
- b. Acute OM
- c. Ear wax
- d. Foreign body
- e. OM with effusion

Ans. The key is OM with effusion.

587. An 18yo man presents to his GP with thirst and polyuria. Some 6m ago he had a significant head injury as the result of a RTA. He is referred to the local endocrine clinic. Which of the following results would be the most useful in confirming the dx of diabetes insipidus after a water deprivation test (without additional desmopressin)?

- a. Plasma sodium of 126mmol/l
- b. Plasma sodium of 150mmol/l
- c. Plasma osmolality of 335mosmol/kg and urine osmolality of 700mosmol/kg
- d. Plasma osmolality of 280mosmol/kg and urine osmolality of 700mosmol/kg
- e. Plasma osmolality of 335mosmol/kg and urine osmolality of 200mosmol/kg

Ans. The key is E. Plasma osmolality of 335 mosmol/kg and urine osmolality of 200 mosmol/kg. [In DI plasma osmolality will be high due to excess fluid loss with urine and urine osmolality will be low due to polyuria. Hence E. is the best option here(normal plasma osmolality 275-295 mosmol/kg and normal urine osmolality is 300-900 mosmol/kg)].

588. A 75yo man has left-sided earache and discomfort when he swallows. There is ulceration at the back of his tongue and he has a palpable non-tender cervical mass. What is the single most likely dx?

- a. Acute mastoiditis
- b. Dental abscess
- c. Herpes zoster infection
- d. Oropharyngeal malignancy
- e. Tonsillitis

Ans. The key is D. Oropharyngeal malignancy. [Pain ear and discomfort during swallowing, ulceration at the back of the tongue and palpable non tender cervical lymphnode is suggestive of oropharyngeal malignancy. Acute mastoiditis and tonsillitis will not cause tongue ulcer. Similarly dental abscess will not cause tongue ulcer. In herpes zoster pain and vesicle will be in the affected nerve distribution].

589. A 42yo man has been tired and sleepy for the last few weeks in the morning. His work has started getting affected as he feels sleepy in the meetings. His BMI=36. What is the single most likely dx?

- a. Idiopathic hypersomnia
- b. Narcolepsy
- c. Chest hyperventilation syndrome
- d. OSAS
- e. REM-related sleep disorder

Ans. The key is D. OSAS. [Day time somnolence and obesity (high BMI of 36) points the diagnosis of OSAS].

590. A 35yo pregnant woman has been having tingling and numbness of her thumb, index and middle fingers for a while. She has been treated with local steroids but it hasn't helped her much and now she has planned to undergo a surgical procedure. Which of the following structures will be incised?

- a. Flexor digitorum profundus
- b. Transverse carpal ligament
- c. Palmar aponeurosis
- d. Extensor retinaculum

Ans. The key is B. Transverse carpal ligament. [This is a case of carpal tunnel syndrome. So transverse carpal ligament is the structure which will be incised].

591. A 58yo pt presents with altered bowel habits and bleeding per rectum. Exam and sigmoidoscopy showed an ulcer. What is the single most likely dx?

- a. Colorectal carcinoma
- b. Celiac disease
- c. Crohns disease
- d. UC
- e. IBS

Ans. The key is A. Colorectal carcinoma. [Age, altered bowel habits, bleeding per rectum and isolated ulcer on sigmoidoscopy suggest colorectal cancer].

592. A mother is concerned that her 18m son has a vocabulary of ten words but can't form a sentence. What is the best management strategy?

- a. Arrange hearing test
- b. Assess developmental milestones
- c. Reassurance
- d. Refer to speech therapist
- e. MRI brain

Ans. The key is C. Reassurance. [Two words joining can be done in 2yrs and inability to form a sentence in 18 months is quite normal. So the option is reassurance].

593. A 55yo man has weight loss, dyspnea and syncope. He smokes 20 cigarettes/day. Inv confirms squamous cell carcinoma in the left bronchus. What is the single most likely biochemical abnormality to be a/w the condition?

- a. Hypercalcemia
- b. Hyperkalemia
- c. Hypernatremia
- d. Hypocalcemia
- e. Hypomagnesium

Ans. The key is A. Hypercalcemia. [Hypercalcemia is common in squamous cell carcinoma].

594. A 72yo man presents with intermittent difficulty in swallowing with regurgitation of stale food materials. Sometimes he wakes up at night with a feeling of suffocation. Choose the single most likely cause of dysphagia?

- a. Benign structure
- b. Esophageal carcinoma
- c. Esophageal spasm
- d. Pharyngeal pouch
- e. Systemic sclerosis

Ans. The key is D. Pharyngeal pouch. [In benign stricture, esophageal carcinoma and systemic sclerosis there is persistent dysphagia not intermittent. In oesophageal spasm there may be intermittent dysphagia but there will be no regurgitation of stale food material and no nocturnal regurgitation in recumbency. The clinical picture described well fits with pharyngeal pouch].

595. A 9m child is brought to the ED with an irreducible firm swelling which descended into the left groin when the child has been crying. Exam: both testicles are palpable in the scrotum. What is the most appropriate management strategy?

- a. Reassurance
- b. Emergency herniotomy
- c. Elective herniotomy
- d. Emergency herniotomy + orchidopexy
- e. Elective herniotomy + orchidopexy

Ans. The key is C. Elective herniotomy. [If there was features of strangulation we would go for emergency herniotomy. But as only irreducible we shall proceed to elective herniotomy].

596. A 37yo woman was admitted for femur fx repair after a RTA. On the 4th post-op day she became confused and starts picking on her bed sheets and complains of seeing spiders all over. What is the most likely dx?

- a. Delirium tremens
- b. Wernickes encephalopathy
- c. Korsakoffs psychosis
- d. Psychotic depression

Ans. The key is A. Delirium tremens. [withdrawal of alcohol due to hospital admission lead to delirium tremens. Wernicke's encephalopathy has triad of i) mental confusion ii) abnormal eye movements & iii) unsteady gait. Korsakoff's syndrome cannot be diagnosed until the person has stopped drinking alcohol for several weeks, to enable the immediate symptoms of alcohol intoxication and withdrawal to subside. Features of Korsakoffs psychosis i) dementia, loss of short term memory ii) difficulty in acquiring new information or learning

new skills iii) personality change iv) confabulation].

597. A 36yo pt came with diarrhea, bleeding, weight loss and fistula. What is the single most likely dx?

- a. Celiac disease
- b. Crohns disease
- c. UC
- d. IBS

Ans. The key is B. Crohns disease.

598. A 72yo woman who is taking loop diuretics is suffering from palpitations and muscle weakness. What is the electrolyte imbalance found?

- a. Na+ 130mmol/l, K+ 2.5mmol/l
- b. Na+ 130mmol/l, K+ 5.5mmol/l
- c. Na+ 140mmol/l, K+ 4.5mmol/l
- d. Na+ 150mmol/l, K+ 3.5mmol/l
- e. None

Ans. The key is A. Na+ 130mmol/l, K+ 2.5mmol/l. [Loop diuretic causes hypokalemia and hyponatremia].

599. A 60yo diabetic pt on anti-diabetic medication developed diarrhea. What is the most likely cause for his diarrhea?

- a. Autonomic neuropathy
- b. Infective
- c. Celiac disease
- d. Crohns disease

Ans. The key is A. Autonomic neuropathy.

600. Which artery runs in the anterior inter-ventricular groove?

- a. Acute marginal branch
- b. Left ant descending artery
- c. Septal branches
- d. Circumflex artery
- e. Right coronary artery

Ans. B. Left anterior descending artery.

601. A mother presents with her 12m daughter. The child has no meaningful words, is unable to sit unaided and can't play with her toys. She doesn't laugh and has poor interaction with her siblings. What is the best management strategy?

- a. Arrange hearing test
- b. Assess developmental milestones
- c. Reassure
- d. Refer to speech therapist
- e. MRI brain

Ans. The key is B. Assess developmental milestones. [At 12 months one word should be said clearly, in 8 months child can sit independently, smiles at 2 months and plays with toys since early infancy. So she needs to assess developmental milestones].

602. A pt presents with progressive visual deterioration. Exam: large, multiple cotton wool spots in both eyes. What is the single most likely dx?

- a. Kaposi's sarcoma
- b. Cryptosporidium
- c. CMV infection
- d. Pneumocystis carinii infection
- e. Cryptococcal infection

Ans. The key is C. CMV infection. [Large multiple cotton wool spots are seen in early stage of CMV retinitis].

603. A 53yo had a dental extraction after which he recently had a mitral valve prolapse, high temp of 39C, cardiac failure and new cardiac murmur. What is the single most likely dx?

- a. Atheroma
- b. Congenital
- c. Regeneration
- d. Infection
- e. Neoplastic

Ans. The key is D. Infection. [Infective endocarditis].

604. A 12yo boy with a hx of fall on an outstretched hand was brought to the ED with swelling and pain around the elbow. His radial nerve was affected. What is the type of fx?

- a. Angulated fx
- b. Epiphyseal fx
- c. Compound fx
- d. Spiral fx

Ans. The key is D. Spiral fracture. It is wrong key. The correct option should be A. Angulated (supracondylar fracture). [Around 50% interosseous nerve lesions occur in supracondylar fracture whereas 25% shows radial nerve damage. If the fracture is spiral fracture of lower

third of humerus it causes nerve damage in 18% almost all of which are radial nerve lesion. However as the fracture is around the elbow (not above) it is supracondylar fracture].

605. A 32yo lady complains that she hears everyone saying that she is an evil person. What type of hallucinations is she suffering from?

- a. 2nd person auditory hallucinations
- b. 3rd person auditory hallucinations
- c. Echo de la pense
- d. Gedankenlautwerden

Ans. The key is B. 3rd person auditory hallucinations. [Third person hallucinations are auditory hallucinations in which patients hear voices talking about themselves, referring to them in the third person, for example "he is an evil person"].

606. A 65yo woman had an excision of colonic tumor 3yrs ago. Now she is losing weight and feels lethargic. Exam: pale but no abdominal findings. What is the most appropriate inv?

- a. CA 125
- b. CA 153
- c. CA 199
- d. CEA
- e. AFP

Ans. The key is D. CEA. [CA 125 = ovarian cancer; CA 153 = cancer breast; CA 199 = pancreatic cancer; CEA = colorectal carcinoma; AFP = hepatocellular carcinoma].

607. A 46yo African-Caribbean man is found to have BP=160/90mmHg on 3 separate occasions. What is the best initial tx?

- a. ACEi
- b. Beta-blockers
- c. ARBs
- d. None
- e. CCB

Ans. The key is E. CCB. [If age less than 55 years but Afro-Caribbean origin then CCB].

608. A 39yo woman will undergo tubal sterilization and she wants to know the failure rate of this type of sterilization.

- a. 1:50
- b. 1:200
- c. 1:500
- d. 1:1000
- e. 1:5000

Ans. The key is B. 1:200.

609. Which of the following reflexes and innervating spinal nerves are correctly paired?

- a. Anal reflex – S1
- b. Ankle jerk – L5
- c. Biceps jerk – C7 & C8
- d. Knee jerk – L3 & L4
- e. Triceps jerk – T1

Ans. The key is D. Knee jerk – L3 & L4. [Anal reflex – S2-4; Ankle jerk – S1-2; Biceps jerk – C5-6; Knee jerk – L3-4; Triceps jerk – C7].

610. A 62yo man with rheumatoid arthritis struck his hand against a door. He subsequently found that although he could extend the interphalangeal joint of his right thumb, the MCP joint of the thumb remained flex. What is the single most likely tendon to have been damaged?

- a. Extensor carpi ulnaris
- b. Extensor digitorum
- c. Extensor indicis
- d. Extensor pollicis brevis
- e. Extensor pollicis longus

Ans. The key is D. Extensor pollicis brevis. [Action of extensor pollicis brevis = extension of thumb at metacarpophalangeal joint. Extensor pollicis longus = extends the terminal phalanx of the thumb].

611. A 68yo lady complains of falls to the ground without any warning, maintains consciousness and no confusion. She says this has occurred at number of times. What is the dx?

- a. Stokes Adams attack
- b. Hypoglycemia
- c. Vasovagal syncope
- d. Drop attacks
- e. Epilepsy

Ans. The key is D. Drop attacks. [Drop attacks are sudden spontaneous falls while standing or walking, with complete recovery in seconds or minutes. There is usually no recognized loss of consciousness, and the event is remembered].

612. A 50yo man complains of being pursued by the police for a crime he denies committing. He has poor concentration and impaired short-term memory. He admits to drinking large amounts of alcohol for the last 20yrs. What is the most probable dx?

- a. Dementia
- b. Hallucination
- c. Wernicke's encephalopathy
- d. Schizophrenia
- e. Korsakoff psychosis

Ans. The key is E. Korsakoff psychosis. [Dementia, i.e. short term memory loss is seen in korsakoff psychosis].

613. A pt with prv hx of HTN, the membranes have ruptured and the cervix is 3cm dilated. 4h later on examination showed that the cervix was still 3cm dilated. What is the single most appropriate management for her labor?

- a. Repeat vaginal examination in 4h
- b. CTG
- c. C-section
- d. External rotation
- e. IV syntocin drip

Ans. The key is E. IV syntocinon drip. [There is no progress of labour in 4 hours. Hence syntocinon drip should be given].

614. A 6yo girl has had 2 short episodes of cough and wheeze over the last 12m. These 2 acute episodes responded quickly to bronchodilator, she has no symptoms or abnormal physical signs. She has slight eczema and her mother has asthma. What is the single most appropriate inv?

- a. CXR
- b. Peak flow rate diary
- c. Pulse oximetry
- d. Spirometry
- e. Sweat test

Ans. The key is D. Spirometry. [spirometry is the preferred initial test (if available) to assess the presence and severity of airflow obstruction less effort dependent and more repeatable though less applicable in acute severe asthma].

615. A 45yo man had recently started taking anti-HTN therapy. 6m later his RBS=14mmol/l. Which single drug is most likely to have caused this?

- a. Amlodipine
- b. Bendroflumethiazide
- c. Doxazosin
- d. Lorisartan
- e. Ramipril

Ans. The key is B. Bendroflumethiazide. [High blood sugar is a well known side effect of bendroflumethiazide].

616. A 27yo waitress has pelvic pain, dysmenorrhea and increasingly heavy periods. She also complains of dyspareunia. There is generalized pelvic tenderness without peritonism. Pelvic US is normal. What is the most likely dx?

- a. Endometriosis
- b. Uterine fibroid
- c. Pelvic congestion syndrome
- d. PID
- e. Tubal pregnancy

Ans. The key is C. Pelvic congestion syndrome. [In pelvic congestion syndrome there develops varicose veins in the lower abdomen from prolonged standing (as occurred here in a waitress who remains standing for long) with some pain syndromes like pelvic pain, dysmenorrhea, dyspareunia and generalized pelvic tenderness without peritonism. Also there may be associated menorrhagia].

617. A 14yo girl is clinically obese. She has not started her periods yet and has severe acne. Among her inv, a high insulin level is found. What is the most probable dx?

- a. Cushing's syndrome
- b. Grave's disease
- c. Acquired hypothyroidism
- d. PCOS
- e. Addison's disease

Ans. The key is D. PCOS. [It is not cushing's as insulin levels in cushing's are not usually raised! Here obesity, primary amenorrhea, acne and particularly high level of insulin makes the likely diagnosis to PCOS].

618. An 18yo girl with primary amenorrhea complains of severe abdominal pain every 4-8weeks which is now getting worse. Exam: lower abdominal mass is felt. What is the most probable dx?

- a. Ectopic pregnancy
- b. Ovarian carcinoma
- c. Hematometrium
- d. Biliary colic
- e. Renal carcinoma

Ans. The key is C. Hematometrium. [Primary amenorrhea and periodic pain indicate hematometrium either secondary to imperforated hymen or vaginal septum].

619. A 14yo boy with asthma suddenly developed chest pain and increasing breathlessness during a game of football. When seen in the ED he was not cyanosed. He has reduced breath sounds on the right side. His oxygen saturation is 94% on air. What is the single most appropriate inv?

- a. Capillary blood gases
- b. CXR
- c. CT chest
- d. Exercise challenge
- e. MRI chest

Ans. The key is B. CXR. [Asthma is a predisposing factor for spontaneous pneumothorax. The presentation indicates pneumothorax for which most appropriate investigation is CXR].

620. A 36yo woman was recently admitted to a psychiatric ward. She believes that the staff and other pts know exactly what she is thinking all the time. What is the most likely symptom this pt is suffering from?

- a. Thought insertion
- b. Thought withdrawal
- c. Thought block
- d. Thought broadcasting
- e. Hallucination

Ans. The key is D. Thought broadcasting.

621. A 60yo woman is admitted to the hospital after a fall. She is noted to have poor eye contact. When asked how she is feeling, she admits to feeling low in mood and losing enjoyment in all her usual hobbies. She has also found it difficult to concentrate, feels that she is not good at anything, feels guilty over minor issues and feels very negative about the future. What is the most likely dx?

- a. Mild depression
- b. Moderate depression
- c. Severe depression
- d. Psychosis
- e. Seasonal depression

Ans. The key is A. Mild depression. [Mild depression: i) Low mood ii) Anhedonia iii) Guilt iv) Hopelessness v) Worthlessness vi) Inability to concentrate].

622. A 70yo woman lives in a nursing home following a stroke has developed reddish scaly rash on her trunk. She has many scratch marks on her limbs and trunk with scaling lesions on her hands and feet. What is the single most appropriate initial tx?

- a. Aqueous cream
- b. Chlorpheniramine
- c. Coal tar
- d. 1% hydrocortisone ointment
- e. Permethrin

Ans. The key is E. Permethrine. [This is a case of scabies and scaly rash denotes the infection of most severe type the crusted or Norwegian scabies. Should be treated with permethrine].

623. A 16yo boy following a RTA was brought to the ED with a swelling and deformity in his right thigh. Exam: airway is patent and is found to have a pulseless leg. Which structure is involved in this fx?

- a. Femoral artery
- b. Posterior tibial artery
- c. Common peroneal nerve
- d. Dorsalis pedis

Ans. The key is A. Femoral artery.

624. A man sat cross-legged for about 30mins. After this he was unable to dorsiflex his left foot and had loss of sensation in the web space between the big toe and the 2nd toe. He also has sensory loss on the same side of the foot after 2h. Which of the following was affected?

- a. Femoral nerve
- b. Sural nerve
- c. Peroneal nerve
- d. Sciatic nerve

Ans. The key is C. Peroneal nerve. [Common peroneal nerve winds round the fibular neck at knee joint and when a man sits cross legged for a considerable time pressure exerted on the nerve may cause nerve palsy].

625. A 25yo woman is presenting with diarrhea and abdominal bloating over the last 4m. Exam: she has blistering rash over her elbows. Biochemistry: low serum albumin, calcium and folate conc. On jejunal biopsy, there is shortening of the villi and lymphocytosis. What is the most likely dx?

- a. Celiac disease
- b. Whipple's disease
- c. Crohn's disease
- d. Tropical sprue
- e. Giardiasis
- f. Cystic fibrosis

Ans. The key is A. Celiac disease. [diarrhea, abdominal bloating, blistering skin rash over elbow (Dermatitis herpetiformis), low serum albumin, calcium and folate conc. Supported by shortening of villi and lymphocytosis on jejuna biopsy is classic presentation of celiac disease].

626. A 19yo man presents for the 1st time with a firm and unshakable belief that he is being followed by terrorists who are plotting against him. What is the single best term for this man's condition?

- a. Delusion of persecution
- b. Delusion of grandeur
- c. Delusion of control
- d. Delusion of reference
- e. Delusion of nihilism

Ans. The key is A. Delusion of persecution. [Delusions of persecution refer to false beliefs or perceptions in which a person believes that they are being treated with malicious intent, hostility, or harassment – despite significant evidence to suggest otherwise].

627. A 19yo female is brought in by her parents. They are concerned about her BMI which is 12. She is satisfied with it. What is the next step?

- a. Psychiatric referral for admission
- b. Family counselling
- c. Social service
- d. Start antidepo
- e. Medical admission

Ans. The key is E. Medical admission. [The diagnosis is anorexia nervosa. At this critical low BMI medical admission is indicated to improve her deficiency states and proper nutrition. ((BMI <15kg/m², rapid weight loss + evidence of system failure) requires urgent referral to eating disorder unit (EDU), medical unit (MU) or paediatric medical wards].

628. A lady who works at a nursing home presents with itching. Exam: linear tracks on the wrist. She says that 2d ago she had come in contact with a nursing home inmate with similar symptoms. What is the mechanism of itching?

- a. Infection
- b. Destruction of keratinocytes
- c. Allergic reaction
- d. Immunosuppression
- e. None

Ans. The key is C. Allergic reaction. [The probable diagnosis is scabies in which there is itching due to allergic reaction to mites (*Sarcoptes scabii*) waste products].

629. A teacher had a respiratory infection for which she was prescribed antibiotics. After the antibiotic course when she rejoined school, she lost her voice completely. What is the single most appropriate dx?

- a. Recurrent laryngeal nerve palsy
- b. Angioedema
- c. Laryngeal obstruction by medication
- d. Laryngitis
- e. Functional dysphonia/vocal cords

Ans. The key is E. Functional dysphonia/vocal cords. [Functional dysphonia is poor voice quality without any obvious anatomical, neurological or other organic difficulties affecting the larynx or voice box. It is often secondary to viral infection].

630. A 43yo lady is admitted with pyrexia, arthropathy, breathlessness and syncope. She was recently dx with pulmonary emboli. There is an early diastolic sound and a mid-diastolic rumble. Her JVP is elevated with prominent a-waves. What is the most likely cause?

- a. Mitral regurgitation
- b. Ventricular ectopics
- c. Pulmonary regurgitation
- d. Atrial myxoma
- e. Complete heart block

Ans. The key is D. Atrial myxoma. [Pyrexia, arthropathy, breathlessness, syncope and early diastolic sound and a mid diastolic rumble are known features of atrial myxoma].

631. A 28yo man presents with a maculopapular rash over his trunk and palms. He also has numerous mouth ulcers. He had a penile ulcer which healed 2wks ago. What will you do to confirm the dx?

- a. PCR for treponemal and non-treponemal antibodies
- b. Dark ground microscopy from mouth ulcer
- c. Blood culture for treponema
- d. Dengue fever

Ans. The key is A. PCR for treponemal and non-treponemal antibodies. [Non treponemal antibody test if positive indicate that there may be syphilis and it is not confirmatory alone. That is why treponemal antibody test should also be done to confirm it. On the other hand resolved disease may show negative treponemal test which is confirmed by positive non-treponemal test].

632. A 34yo man complains of arthralgia, abdominal pain and vomiting, a facial rash that is worse in the summer and hematuria. Urea and creatinine are slightly elevated with urinalysis demonstrating red cell casts. PMH is remarkable for childhood eczema. Which inv is most likely to lead to a dx?

- a. US KUB
- b. Joint aspiration
- c. Auto antibodies
- d. IVU
- e. Renal biopsy

Ans. The key is C. Auto antibodies. [Likely diagnosis is SLE for which auto antibody (anti ds DNA antibody) should be done].

633. A 56yo woman has had severe abdominal pain for 24h radiating to her back and is accompanied by nausea and vomiting. She appears to be tachycardic and in shock. She was found to have gallstones, 2yrs ago. What is the most likely inv to confirm dx?

- a. US abdomen
- b. LFT
- c. Serum lipase
- d. Angiography
- e. CT abdomen

Ans. The key is C. Serum lipase. [The likely diagnosis is pancreatitis hence serum lipase].

634. A 32yo female with axillary freckles and café au lait spots wants to know the chances of her child also having similar condition.

- a. 1:2
- b. 1:4
- c. No genetic link
- d. 1:16
- e. Depends on the genetic make up of the partner

Ans. The key is E. Depends on genetic make up of the partner. [De-

pends on the make up of the partner, ideally it's 1:2 since it's autosomal dominant with complete penetrance but if the patient's spouse also has neurofibromatosis, it raises it to at least 75% with a possible 100%].

635. A 40yo man has pain, redness and swelling over the nasal end of his right lower eyelid. The eye is watery with some purulent discharge. The redness extends on to the nasal peri-orbital area and mucoid discharge can be expressed from the lacrimal punctum. What is the single most appropriate clinical dx?

- a. Acute conjunctivitis
- b. Acute dacrocystitis
- c. Acute iritis
- d. Retrobulbar neuritis
- e. Scleritis

Ans. The key is B. Acute dacrocystitis.

636. A 60yo lady has severe chest pain. ECG shows changes of inferior wall MI. ECG also shows progressive prolongation of PR interval until a QRS complex is dropped. What is the most probable dx?

- a. Atrial fibrillation
- b. VT
- c. SVT
- d. Mobitz type I 2nd degree heart block
- e. Mobitz type II 2nd degree heart block

Ans. The key is D. Mobitz type I 2nd degree heart block. [Inferior MI is frequently associated with conduction defect].

637. A 52yo woman speaks rapidly without any pause and ignores interruptions. She doesn't even pause to take enough breaths. What term best describes this kind of speech?

- a. Flight of ideas
- b. Broca's aphasia
- c. Wernicke's aphasia
- d. Pressure of speech
- e. Verbal dysphasia

Ans. The key is D. Pressure of speech.

638. A 30yo woman has been feeling low and having difficulty in concentrating since her mother passed away 2m ago. She feels lethargic and tends to have breathlessness and tremors from time to time. What is the most likely dx?

- a. Adjustment disorder
- b. PTSD
- c. Panic disorder
- d. GAD
- e. Bereavement

Ans. The key is A. Adjustment disorder. [When 2 months passed it is no more normal bereavement but major depression or adjustment disorder].

639. A 32yo man on psychiatric medications complains of inability to ejaculate. Which drug is most likely to cause these symptoms?

- a. Lithium
- b. Haloperidol
- c. Chlorpromazine
- d. Fluoxetine
- e. Clozapine

Ans. The key is D. Fluoxetine. [SSRIs are frequently associated with delayed ejaculation].

640. A 4yo boy is brought by his parents with complains of wetting his bed at night and whenever he gets excited. What would be the most appropriate management for this child?

- a. Desmopressin
- b. Oxybutanin
- c. Behavioural therapy
- d. Tamsulosin
- e. Restrict fluid intake

Ans. The key is C. Behavioural therapy. Probably this is wrong option! There is no correct option for this question. [The question is inappropriate. Child is of 4 yrs of age and before 5 yrs only reassurance, no treatment is indicated].

641. A 34yo DM pt is undergoing contrast radiography. What measure should be taken to prevent renal damage with contrast dye?

- a. Reduce contrast dye
- b. Plenty of fluids
- c. NSAIDS
- d. ACEi
- e. IV dextrose

Ans. The key is B. Plenty of fluids.

642. A 75yo woman presents to the breast clinic having noticed that she has had a blood stained discharge from the left nipple, together with dry skin over the left areola. Exam: blood stained discharge with dry flaky skin noted on the left areola. The nipple was noted to be ulcerated. What is the most appropriate inv?

- a. FNAC
- b. MRI
- c. Punch biopsy
- d. Open biopsy
- e. Stereotactic biopsy

Ans. The key is C. Punch biopsy. [As the lesion is on the surface punch biopsy can be well obtained].

643. A 50yo man presents with low mood, poor concentration, anhedonia and insomnia. He has had 2 episodes of increased activity, promiscuity and aggressive behavior in the past. He was arrested 8m ago for trying to rob a bank claiming it as his own. Which drug is most likely to benefit him?

- a. Haloperidol
- b. Citalopram
- c. Desipramine
- d. Carbamazepine
- e. Ethosuximide

Ans. The key is D. Carbamazepine. [It is a case of bipolar disorder. Mainstay of treatment is mood stabilizers such as i) Lithium carbonate ii) Anticonvulsant medicines iii) Antipsychotic medicines. So from the given options Carbamazepine is the most appropriate drug].

644. A 25yo woman complains of dizziness, nausea, vomiting, visual disturbances and anxiety which keep coming from time to time. Most of the attacks are a/w sudden change in posture. What is the most likely dx?

- a. Panic disorder
- b. Carotid sinus syncope
- c. BPPV
- d. Vertebrobasilar insufficiency
- e. Postural hypotension

Ans. The key is C. Benign paroxysmal positional vertigo (BPPV). [Dizziness, nausea, vomiting and nystagmus which keep coming from time to time are common features of BPPV].

645. A 56yo man was recently put on anti-HTN meds and recent biochemistry on 2 occasions showed: Na+=132, K+=7.6, Urea=11.3, Creat=112. Which of the following drugs is responsible for this result?

- a. Amlodipine
- b. Bendroflumethiazide
- c. Doxazosin
- d. Atenolol
- e. Ramipril

Ans. The key is E. Ramipril. [ACEI and ARB are known to raise the serum potassium level].

646. A 46yo woman has offensive yellow discharge from one nipple. She had a hx of breast abscess 3yrs ago. What is the possible dx?

- a. Duct papilloma
- b. Duct ectasia
- c. Duct fistula
- d. Breast cancer

Ans. The key is C. Duct fistula.

647. A 35yo woman undergoing tx for TB presents with malar rash, photosensitivity and hematuria. What is the single most likely positive antibody?

- a. Anti Ds DNA
- b. Anti Sm
- c. Anti Histone
- d. Anti La
- e. Anti centromere

Ans. The key is C. Antihistone antibody. [Anti histone antibody is present in 95% cases of drug induced lupus].

648. A 6wk child with profuse projectile vomiting. What is the first thing you will do?

- a. US
- b. Check serum K+ level
- c. ABC
- d. NG tube
- e. IV fluids

Ans. The key is B. Check serum K+ level. This is a wrong key! Correct key is E. IV fluid.

649. A 55yo woman who attends the clinic has recently been dx with a depressive episode. She complains of unintentionally waking early in the morning, a recent disinterest in sex and a loss of appetite, losing 5kg weight in the last month. She feels that her mood is worse at the beginning of the day. What is the most likely dx for this pt?

- a. Mild depression
- b. Moderate depression
- c. Severe depression
- d. Low mood
- e. Pseudo depression

Ans. The key is B. Moderate depression. [Sleep disturbance, disinterest in sex and loss of appetite points towards the diagnosis of moderate depression].

650. An employer sent his worker to the ED after having hit his head on a machine. Exam: normal. What is the single most likely inv you would do?

- a. Skull XR
- b. CT head
- c. MRI head
- d. Reassure

Ans. The key is A. Skull XR. This is a wrong key! Correct key should be D. Reassurance. [Indications for CT are not fulfilled by given criteria. NICE has mentioned X-ray skull is no more preferred over CT. Hence answer for this question is D. Reassurance].

651. A lady with fam hx of ovarian carcinoma has a pelvis US that fails to reveal any abnormality. What is the single most appropriate inv?

- a. Pelvic CT
- b. CA 125
- c. CA 153
- d. Laparoscopy
- e. MRI

Ans. The key is B. CA 125. [CA 125 is tumour marker for ovarian tumour].

652. A 10yo boy is taken to his GP by his parents with behavioural prbs. He attends a special school due to inappropriate behavior and during the interview with his parents the boy barks at infrequent episodes and shouts expletives. What is the most likely dx?

- a. Asperger syndrome
- b. Cotard syndrome
- c. Rett syndrome
- d. Ekblom syndrome
- e. Tourette's syndrome

Ans. The key is E. Tourette's syndrome. [Tourette's syndrome may have

motor tics like blinking, facial grimacing, shoulder shrugging. Other complex motor tics may be sniffing, touching objects, hopping, jumping, bending or twisting. It has vocal tics like throat clearing, sniffing, grunting or barking and more complex like coprolalia (uttering socially inappropriate words) or echolalia (repeating the word or phrase of others)].

653. A 52yo male presents with sudden complete loss of vision from right eye. He also had been complaining of right sided headaches which would come up more on chewing. On fundoscopy, the retina was pale and a cherry red spot could be seen in the macular region. What caused this vision loss?

- a. CRAO
- b. CRVO
- c. Branch RAO
- d. Branch RVO
- e. Circumciliary vein occlusion

Ans. The key is A. CRAO. [Pale retina with cherry red spot in macular region is seen in CRAO].

654. A 48yo woman presents with left-sided severe headache. She also has a red, watering eye and complains of seeing colored haloes in her vision. What is the most appropriate next step?

- a. Measure IOP
- b. Relieve pain with aspirin
- c. 100% oxygen
- d. CT
- e. Relieve pain with sumatriptan

Ans. The key is A. Measure IOP. [Probable case of angle closure glaucoma requiring measurement of IOP to establish the diagnosis].

655. A 31yo woman presents with 7-10days following childbirth, with loss of feeling for the child, loss of appetite, sleep disturbance and intrusive and unpleasant thoughts of harming the baby. What is the best tx for this pt?

- a. Fluoxetine
- b. Haloperidol
- c. CBT
- d. Reassurance
- e. ECT

Ans. The key is A. Fluoxetine. This is wrong key! Correct key should be B. Haloperidol. [Dx is postpartum psychosis. Patient.info, Wikipedia says antipsychotic and if needed additional mood stabilizer may be used as 1st line. NHS says antidepressant, antipsychotic and mood

stabilizer (any one or in combination) as 1st line treatment. As antipsychotic has given priority likely correct answer is C. IV haloperidol. 2nd line is CBT, and last resort is ECT].

656. A 56yo male pt presents with intermittent vertigo, tinnitus and hearing loss. What is the best drug tx for this pt?

- a. Buccal prochlorperazine
- b. Oral fluphenazine
- c. TCA
- d. Gentamicin patch on the round window
- e. No med tx available

Ans. The key is A. Buccal prochlorperazine. [Probable case of Menieres disease. Treated with prochlorperazine].

657. An 82yo woman has developed painful rash on one side of her forehead and ant scalp. Lesions have also affected her cornea. What is the single most appropriate option?

- a. Accessory nerve
- b. Facial nerve
- c. Olfactory nerve
- d. Optic nerve
- e. Trigeminal nerve

Ans. The key is E. Trigeminal nerve. [Probable herpes zoster ophthalmicus].

658. A 24yo woman presents with episodes of peri-oral tingling and carpo pedal spasms every time she has to give a public talk. This also happens to her before interviews, exams and after arguments. What is the best management strategy for this pt?

- a. Diazepam
- b. Breathe in a paper bag
- c. Desensitization
- d. Buspirone
- e. Propranolol

Ans. The key is B. Breathe in a paper bag. This is wrong key. More correct option is C. Desensitization. [Desensitization is the treatment of choice in long run. For prevention propranolol before expected exposure and if patient presents with an attack then rebreathing in a paperbag to subside her acute problems].

659. A 32yo woman P3 of 39wks gestation reports having spontaneous ROM 4days ago. She didn't attend the delivery suite as she knew that would happen and had already decided on a home birth. Today she feels very hot and sweaty. She thought that she was starting to have labour pains but she describes the pain as more constant. Exam: uterus is tender throughout. Blood tests show raised CRP and WBC. Select the most likely dx?

- a. Round ligament stretching
- b. Chorioamnionitis
- c. Uterine rupture
- d. Labor
- e. DIC

Ans. The key is B. Chorioamnionitis. [Prolonged rupture of membrane can lead to chorioamnionitis].

660. A 63yo man continues to experience chest pain and has a temp of 37.8C 2 days after an acute MI. His ECG shows widespread ST elevation with upward concavity. What is the single most likely explanation for the abnormal inv?

- a. Acute pericarditis
- b. Cardiac tamponade
- c. Atrial thrombus
- d. Left ventricular aneurysm
- e. Dressler syndrome

Ans. The key is A. Acute pericarditis. [Chest pain, raised temperature and ECG findings of widespread ST elevation with upwards concavity is diagnostic of acute pericarditis particularly after MI].

661. A 55yo man presents with an ulcer of the scrotum. Which of the following LN is involved?

- a. External iliac LN
- b. Pre-aortic LN
- c. Aortic LN
- d. Inguinal LN
- e. Iliac LN
- f. Submental LN
- g. Submandibular LN
- h. Deep cervical LN

Ans. The key is D. Inguinal LN.

662. A 35yo woman has butterfly rash on her face and she suffers symmetrical joint pains on knee and elbow, ESR is raised. What is the most discriminative inv for dx?

- a. Anti DNA antibodies
- b. Anti Jo1 antibodies
- c. Anti nuclear antibodies
- d. Anti centromere antibodies
- e. Anti la antibodies

Ans. The key is A. Anti DNA antibodies. [Anti DNA antibodies to diagnose SLE].

663. Pt had a fight following which he developed bleeding, ringing and hearing loss from one ear. What is the inv of choice?

- a. CT
 - b. XR skull
 - c. Otoscopy
 - d. MRI vestibule
 - e. Coagulation study
- Ans.** The key is A. CT. This is a wrong key! Correct key is Otoscopy.

664. A 35yo IVDA (Intra Venous Drug Abuser) on penicillin and flucloxacillin for cellulitis now presents with jaundice, pale stools and dark urine. What is the single most likely dx?

- a. Hep A
- b. Cholestatic jaundice
- c. Chronic active hepatitis
- d. Primary biliary cirrhosis
- e. Hep B

Ans. The key is B. Cholestatic jaundice. [Flucloxacillin can cause cholestatic jaundice].

665. A 79yo woman has been dx with T2DM. Her BMI=22. RBS are 8 and 10mmol/l. Her BP=130/80mmHg. Her fasting cholesterol=5.7mmol/l. She is currently symptom-free but has microalbuminuria. What is the single most appropriate drug management?

- a. ACEi and glibenclamide
- b. ACEi and metformin
- c. Statin and ACEi
- d. Statin and glibenclamide
- e. Statin and metformin

Ans. The key is C. Statin and ACEi. [Diabetic patients are advocated statin irrespective of cholesterol levels and diabetic microalbuminuria is best treated by ACEi. As initially we shall give lifestyle advice and no medicine for diabetes even then we shall start with statin and ACEi].

666. A 68yo woman is unable to extend the IP joint of her right thumb 7wks following a fx of the right radius. Other finger and thumb movements are normal. What is the single most likely tendon to be damaged?

- a. Abductor pollicis longus
- b. Extensor pollicis brevis
- c. Extensor pollicis longus
- d. Flexor digitorum profundus
- e. Flexor pollicis longus

Ans. The key is C. Extensor pollicis longus. [Full extension of right thumb is achieved by extensor pollicis longus].

667. A mother presents her 6m son who is vocalizing. She has noticed that he doesn't respond to loud noises. His motor milestones are normal. What is the best management strategy?

- a. Arrange hearing test
- b. Assess development milestones
- c. Reassure
- d. Refer to speech therapist
- e. MRI brain

Ans. The key is A. Arrange hearing test. [Normal motor milestones indicate normal development but unable to respond to loud noise at 6 months may indicate deafness].

668. A 39yo man presents to the ED with persistent cough, sputum and dyspnea. He gave a hx of smoking 20 cigarettes/d for the last 10 years. Pt was given oxygen in ambulance but he is not improving. What is the next step?

- a. Prednisolone
- b. Salbutamol
- c. Check ABG
- d. CXR
- e. ECG

Ans. The key is C. Check ABG. [The patient has COPD and as no improvement with oxygen, next step is to check ABG to give guidance for next treatment plan].

669. A 66yo woman has been brought to the hospital on a number of occasions with a hx of loss of memory. Her PMH is significant for an MI 6yrs ago. It is noted that she has a step wise decline of her cognitive functions. What is the most likely dx?

- a. Alzhemiers
- b. Vascular dementia
- c. Pick's dementia
- d. Huntington's disease
- e. Lewy body dementia

Ans. The key is B. Vascular dementia. [Age 65 yrs (vascular dementia is rare at age before 65), history of MI and stepwise decline of cognitive function indicates vasculopathy and hence vascular dementia].

670. A 55yo man returns for routine follow up 6wks after an MI. He gets breathless when walking uphill. His ECG shows ST elevation in leads V1, V2, V3 and V4. What is the single most likely explanation for the abnormal investigation?

- a. Heart block
- b. Right ventricular strain
- c. Atrial thrombus
- d. Left ventricular aneurysm
- e. Dressler's syndrome

Ans. The key is D. Left ventricular aneurysm. [Features of heart failure and persistent ST elevation suggests the dx of left ventricular aneurysm].

671. A 4m girl has severe FTT (Failure To Thrive) and increasing jaundice which was 1st noticed at 1wk of age. She has an enlarged liver and scratches on her skin. Her parents have been unable to seek medical care. What is the most likely dx?

- a. Biliary atresia
- b. G6PD deficiency
- c. Hep B
- d. Spherocytosis

Ans. The key is A. Biliary atresia. [Increasing jaundice at this age with failure to thrive, enlarged liver and scratches (itching) indicate cholestatic jaundice likely from biliary atresia].

672. A 76yo man suddenly collapsed and died. At post mortem exam, a retroperitoneal hematoma due to ruptured aortic aneurysm was noted. What is the most likely underlying cause of the aortic aneurysm?

- a. Atheroma
- b. Cystic medial necrosis
- c. Dissecting aneurysm
- d. Polyarteritis nodosa
- e. Syphilis

Ans. The key is A. Atheroma.

673. A 33yo male came to the hospital with complaint of occasional left sided chest pain that lasts <30mins, following exercise, which relieves upon taking rest. What is the most probable dx?

- a. Unstable angina
- b. Decubitus angina
- c. Stable angina
- d. Coronary spasm
- e. MI

Ans. The key is C. Stable angina.

674. A 42yo overweight smoker comes with heavy periods. A scan reveals a normal uterus. She would like a long term tx with minimal side effects that would offer tx for the menorrhagia and provide contraception. She is unsure whether she would like more children. She is adamant that she doesn't want surgery as she is terrified of the prospect. Select the best management for her menorrhagia?

- a. COCP
- b. GrH analogues
- c. IU/systemic progesterone
- d. NSAIDs
- e. Copper containing IUCD

Ans. The key is C. IU/systemic progesterone. [As patient is smoker, COCP should be avoided. In the given case option C. i.e. mirena is most suitable].

675. A 10yo male child was brought by his mother complaining that her child watches TV at very high volumes, doesn't like to play outside and instead has become more sincere with reading. She also says that her son doesn't respond to her. What do you expect to see on otoscopy?

- a. Flamingo pink tympanic membrane
- b. Attic perforation
- c. Bluish grey tympanic membrane with air fluid levels
- d. Inflamed tympanic membrane with cart wheel appearance of vessels
- e. Red and inflamed tympanic membrane

Ans. The key is C. Bluish grey tympanic membrane with air fluid levels. [In glue ear there occur conductive deafness so the child watch tv with high volume and does not respond to others for this deafness].

676. A lady underwent debulking surgery for ovarian carcinoma. Soon after the surgery she presents with signs of intestinal obstruction. What is the single most appropriate inv?

- a. Pelvic CT
- b. CA 125
- c. Laparotomy
- d. Laparoscopy
- e. Abdominal US

Ans. The key is C. Laparotomy. [In cancer patient obstruction does not respond to medical treatment and hence diagnostic and therapeutic laparotomy is the option of choice].

677. A 45yo woman undergoing tx for RA for the last 5yrs presents with dizziness, easy fatigability and lack of energy. A blood film shows MCV 106. What could be the most probable reason for her anemia?

- a. Steroids
- b. Chronic disease
- c. NSAIDs
- d. Methotrexate
- e. Sulfasalazine

Ans. The key is D. Methotrexate. [Methotrexate leads to folate deficiency anaemia].

678. A 62yo man who has recently had flu-like illness has woken to find his speech altered. Movement of his eyelids and lips are weak on the right side. Exam: normal. Which anatomical site is most likely to be affected?

- a. Facial nerve
- b. Hypoglossal nerve
- c. Oculomotor nerve
- d. Trigeminal nerve
- e. Glossopharyngeal nerve

Ans. The key is A. Facial nerve. [Viral infection is a common cause of facial nerve palsy].

679. A 5yo girl has had an URTI for 3 days and has been treated with paracetamol by her mother. For the last 12h she has been hot and irritable with severe pain in her right ear. What is the most likely dx?

- a. Herpes zoster infection
- b. Impacted ear wax
- c. Mumps
- d. OM
- e. Perforation of eardrum

Ans. The key is D. OM.

680. A 35yo man has a temp=39C, cough with purulent sputum and right sided chest pain on inspiration. He has herpes labialis. What is the single most likely causative organism?

- a. Coagulase +ve cocci in sputum
- b. Gram -ve diplococci in sputum
- c. Gram +ve diplococci in sputum
- d. Pneumocystis carinii in sputum
- e. Serology for legionella

Ans. The key is C. Gram +ve diplococci in sputum. [High temperature, cough with purulent sputum, pleuritic chest pain and herpes labialis are recognized feature of pneumococcal pneumonia (pneumococcus=Gram +ve diplococci)].

681. A 27yo female was brought to the ED by her friend from a movie theatre. She complains of sudden severe pain in the eye followed by vomiting and also was seeing colored halos. She gives a past hx of recurrent headaches which used to resolve spontaneously. Exam: fixed, dilated ovoid pupil seen. What is the first inv?

- a. CT head
- b. MRI orbits
- c. Blood culture and sensitivity
- d. Toxicology screen
- e. Applanation tonometry

Ans. The key is E. Applanation tonometry. [Darkness can cause

dilatation of pupil (which occurred in the darkness of theatre room) which (halfway dilatation) most often precipitate acute attack of angle closure glaucoma and the test to diagnose this is applanation tonometry].

682. An 82yo male suddenly becomes unconscious and fell down. He recovered completely within minutes. What is the best inv you do to dx the case?

- a. ECG
- b. EEG
- c. Blood glucose level
- d. CT
- e. CXR

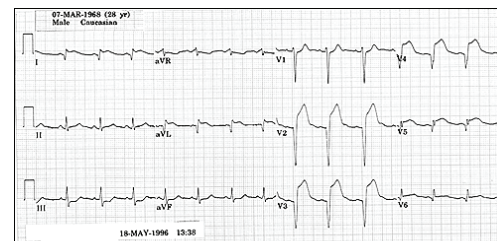
Ans. The key is A. ECG. [Here sudden unconsciousness without any provocation, which makes arrhythmia the most likely cause; hence we should do ECG].

683. A child admitted with progressive muscle weakness and frequent falls. What is the most probable dx?

- a. Duchenne's MD
- b. Becker's MD
- c. Polymyositis
- d. Dermatomyositis
- e. Polymyalgia rheumatic

Ans. The key is A. Duchenne's MD.

684. A 56yo man presents to the ED with chest pain. The following ECG was taken. What is the most likely dx?



- a. Anterior MI
- b. Inferior MI
- c. Lateral MI
- d. Posterior MI
- e. NSTEMI

Ans. The key is A. Anterior MI. [Here ST elevation in L1, aVL, v2,v3,v4 and v5. So the diagnosis is anterior MI (as L1 and aVL and v2-v5,

anterolateral would be more appropriate description)].

685. A schizophrenic says: life is unfair. I like fairs. Fairs have food. It must be good. What term describes this pt's speech?

- a. Neologism
- b. Flight of ideas
- c. Broca's aphasia
- d. Wernicke's aphasia
- e. Clang association

Ans. The key is E. Clang association. [The rhymic use of words as described is known as clanging or clang association often seen in schizophrenia].

686. A man comes to the ED with hx of pulsatile swelling in the abdomen, he has hx of HTN and exam: pulse=120bpm, BP=70/40mmHg. He is restless and in shock. What emergency management should be done on priority basis?

- a. Urgent abdominal CT
- b. Urgent abdominal US
- c. IV fluids 0.9% NS crystalloids to bring SBP to 90mmHg
- d. IV fluids 0.9% NS crystalloids to bring SBP to 120mmHg
- e. Dopamine inj

Ans. The key is C. IV fluids 0.9% NS crystalloids to bring SBP to 90mmHg [Probable ruptured aortic aneurism. Immediate IV normal saline to raise the BP to 90 mmHg to keep the vital organs perfused till definitive measures are taken].

687. A 5yo boy has cough and swelling at the knee after falling on the ground with rashes on the buttocks which are non-blanching. PT=13, APTT=71, Hgb=11, WBC=8, Plt=200. Choose the most likely dx?

- a. NAI
- b. Hemophilia
- c. HSP
- d. Osler weber reindu syndrome
- e. Von-Willebrand disease

Ans. The key is B. Hemophilia. This is a controversial key! Correct key should be E. Von-Willebrand disease. [Likely D/D may be B or C! in von willebrands disease usually there is no hemarthrosis (except in type 3) and in hemophilia no nonblanching rash (there may be bruising). isolated rise in APTT is highly suggestive of hemophilia (given case). This is an ill defined question and only likely diagnosis may be type 3 von willebrands disease (in HPS- APTT is not raised and there may be thrombocytosis, so this is not a case of HSP)].

688. A 45yo woman presents with discharge from the left nipple. The discharge is brownish-green and foul smelling. What is the most likely dx?

- a. Duct papilloma
- b. Intra-ductal papilloma
- c. Duct ectasia
- d. Mammary duct fistula
- e. Breast abscess

Ans. The key is C. Duct ectasia. [Women near menopause are more affected by duct ectasia characterized by brown, green or cheesy discharge. This condition is harmless and tends to clear up without treatment].

689. A 10yo boy presents with generalized swelling. This has been present for 4days and included swollen ankles and puffiness of the face. It started a few days after he had a mild cold with runny nose. His only PMH was eczema. Urine analysis: hematuria, proteinuria 10g/24h, creat 60umol/l and albumin=15g/l. What is the single most likely dx?

- a. IgA nephropathy
- b. HSP
- c. Minimal change nephropathy
- d. Wilson's disease
- e. Cardiac failure

Ans. The key is A. IgA nephropathy. [10 yr old boy, history of URTI and hematuria points towards the diagnosis of IgA nephropathy. It may be present with proteinuria and generalized swelling. The important differentiating point from rapidly progressive GN is duration. IgA nephropathy <10 days (usually 4/5 days history of infection but in rapidly progressive GN history of infection for >10 days].

690. A 28yo man complains of vertigo, nausea and vomiting for more than 30 mins and tinnitus, hearing loss in the left ear. What is the tx for this pt?

- a. Buccal prochlorperazine (2nd line)
- b. Metachlorpromide
- c. Cyclazine (1st line)
- d. Cotrimazole
- e. Ondansetron

Ans. The key is C. Cyclazine. More appropriate is A. Buccal prochlorperazine (patient.info). [Both prochlorperazine and cyclazine can be used in Meniere's disease].

691. A 16yo girl has been unwell for 5days with malaise, headache and dry cough. She has a few crackles in her chest. Her CXR shows patchy consolidation in the lower lobes. What is the single most likely causative organism?

- a. Cold agglutinins
- b. Gram -ve diplococci in sputum
- c. Gram +ve diplococci in sputum
- d. Serology for legionella
- e. Sputum staining for mycobacterium TB

Ans. The key is A. Cold agglutinins. [Mycoplasma pneumonia, a form of atypical bacterial pneumonia related to cold agglutinin disease].

692. A child with increasing jaundice and pale stools. Choose the appropriate test:

- a. Endomyseal antibodies
- b. Sweat test
- c. TFT
- d. LFT
- e. US

Ans. The key is E. US. [This is obstructive jaundice where US may show dilatation of common bile duct or stones].

693. A 73yo woman with RA is unable to extend the fingers of her right hand at the MCP joint and IP joints following a fall. What is the single most likely tendon to have been damaged?

- a. Extensor carpi radialis
- b. Extensor carpi ulnaris
- c. Extensor digitorum
- d. Extensor indicis
- e. Flexor digitorum profundum

Ans. The key is C. Extensor digitorum. [The extensor digitorum extends the phalanges, then the wrist, and finally the elbow. It acts principally on the proximal phalanges].

694. You are called to see a 20yo woman 2h post-LSCS. She has not passed urine since her operation. She denied any urinary symptoms preoperatively. Exam: appears unwell, temp=37.5C, BP=94/73mmHg, pulse=116bpm, sat=97%. Her abdomen is distended with tenderness in the left flank and suprapubic region. Bowel sounds are not audible. Choose the most appropriate post Csection complication for this lady?

- a. UTI
- b. Urinary tract injury
- c. Pleurisy
- d. Acute pyelonephritis
- e. Paralytic ileus

Ans. The key is B. Urinary tract injury.

695. A 58yo man has a headache and confusion of 3 days after slipping and hitting his head in the garden. What is the most appropriate initial inv?

- a. XR skull
- b. XR face
- c. CT brain
- d. MRI brain
- e. EEG

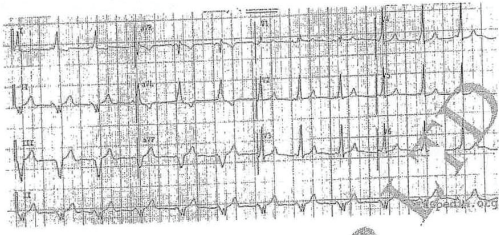
Ans. The key is C. CT brain. [The likely diagnosis is subdural haematoma for which appropriate initial investigation is CT scan of brain].

696. A 4yo boy has a cough and arthritis followed by rash on legs which are non-blanching on glass test. No hx of fever. PT=13, APTT=31, Hgb=12, WBC=6.5, Plt=300. What's the most likely dx?

- a. Meningitis septicemia
- b. Hemophilia
- c. HSP
- d. ITP
- e. TTP

Ans. The key is C. HSP. [Usually occurs below 10 yrs of age. The characteristic rash and lab findings matches with HSP].

697. A 72yo man presents to the ED with chest pain. The following ECG was taken. What is the most likely dx?



- a. Anterior MI
- b. Inferior MI
- c. Lateral MI
- d. Posterior MI
- e. NSTEMI

Ans. The key is B. Inferior MI. [There is pathological Q wave and mild ST elevation in leads II, III and aVF].

698. A young man has diarrhea, loss of weight and flatulence for 3 days. What is the most imp tx?

- a. Metronidazole
- b. Fluconazole
- c. Vancomycin
- d. Amoxicillin

Ans. The key is A. Metronidazole.

699. A 6yo child presented with drooling of saliva and severe stridor. He is febrile and sick looking. XR Neck in extension shows a thumb sign. Choose the single most likely dx.

- a. Croup
- b. URTI
- c. Diphtheria
- d. Acute epiglottitis

Ans. The key is D. Acute epiglottitis. [Drooling of saliva and stridor along with thumb sign in neck X-ray are features of acute epiglottitis].

700. A mother presents with her 3yo son who has indistinct nasal speech. He snores at night and has restless sleep. He is tired by day. What is the best management strategy?

- a. Arrange hearing test
- b. Assess development milestones
- c. Refer to ENT surgeon
- d. Refer to speech therapist
- e. MRI brain

Ans. The key is C. Refer to ENT surgeon. [Probable enlarged adenoid].

701. A 17yo boy while playing football got a kick and now he is complaining of severe pain and swelling of the left side of his scrotum. What inv is the most appropriate to dx?

- a. Needle aspiration of scrotum
- b. US scrotum
- c. MSU
- d. Surgical exploration of scrotum
- e. Urine test for hematuria

Ans. The key is D. Surgcal exploration of scrotum. [This is a case of testicular torsion which needs urgent diagnostic and therapeutic surgical exploration of the scrotum].

702. A 50yo man has had hoarseness of voice and drooping eyelid for 2m. a mass is palpable in the right supraclavicular fossa. He smokes 20 cigarettes/day for the last 30yrs. What is the most likely dx?

- a. Carcinoma larynx
- b. Carcinoma thyroid
- c. Carcinoma right bronchus
- d. Mesothelioma
- e. Pancoast tumor

Ans. The key is E. Pancoast tumour. [Hoarseness of voice is due to compression of the recurrent laryngeal nerve, ptosis due to compression of the sympathetic ganglion, palpable mass in right supraclavicular fossa due to involvement of the supraclavicular lymph node. History of smoking and given picture indicates the diagnosis of Pancoast tumour].

703. An 84yo man got surgical pain which is well controlled by oral morphine 60mg BD. However, now this pt is unable to swallow. What is the most appropriate next step?

- a. Morphine 60mg state
- b. Morphine 60mg TDS
- c. Oxycodone 10mg OD
- d. Morphine 60mg IV
- e. Fentanyl patches

Ans. The key is E. Fentanyl patches. [When dose of oral morphine is known and rout should be changed Phentanyl patch is adviced as the fixed dose is known and patch can release the required dose for a given period (when we use patch we can not change the dose). But if the pain control is not optimal we should follow the next step (i.e. parenteral morphine) as per pain ladder. But as no correct dose of parenteral morphine is in the options (iv morphine dose is one-third of oral morphine) we have to go for fentanyl patches].

704. A 19yo man has exercise induced asthma. This has prv been controlled using a salbutamol inhaler as req, but he now gets attacks with exercise. What is the single most appropriate tx?

- a. Regular salbutamol
- b. Regular salbutamol and budesonide
- c. Sodium cromoglycate
- d. Oral steroid
- e. Inhaled steroid

Ans. The key is C. Sodium chromoglycate. This is wrong key! Correct key should be B. Regular salbutamol and budesonide. [Chrommoglycate should be used in exercise induced asthma if salbutamol and steroids fail]. [This question is not appropriate as single most appropriate treatment to add or to chose from given options is not clear].

705. A 3yo boy has a sudden onset of fever, vomiting and bilateral face swelling. Few days earlier the GP saw him for bilateral parotid pain and gave analgesics. What is the most appropriate next step?

- a. Analgesic
- b. Antibiotic
- c. Biopsy
- d. Immediate surgery
- e. Reassurance

Ans. The key is E. Reassurance. [A case of mumps. Self limiting condition].

706. A 75yo man with adenocarcinoma of the prostate which has spread outside the capsule of the gland has ARF. What is the most appropriate next inv?

- a. MRI spine
- b. Radionuclide bone scan
- c. Trans rectal US
- d. US pelvis
- e. US KUB

Ans. The key is E. US KUB. [extension beyond capsule may cause obstruction of ureters, causing loin pain, anuria, symptoms of acute kidney injury or chronic kidney disease (here ARF) ref: patient.info].

707. A 57yo male presents with sudden onset severe abdominal pain and rigidity against a 4d background of LIF pain and pyrexia. He has no PM/SHx of note and isn't on any meds. What is the most likely dx?

- a. Intussusception
- b. Ischemic colon
- c. Sigmoid volvulus
- d. Perforated diverticulum
- e. Perforated Meckel's diverticulum

Ans. The key is D. Perforated diverticulum. [Sudden onset, severe abdominal pain, rigidity, left iliac fossa pain and fever are in favour of perforated diverticulum].

708. A 46yo woman has weight gain, sensitivity to cold, pulse=50bpm, heart is enlarged with murmur. What is the single most likely dx?

- a. Hypothyroidism
- b. Hyperthyroidism
- c. Cushing's syndrome
- d. Addison's disease
- e. Pheochromocytoma

Ans. The key is A. Hypothyroidism. [The given symptoms are classic presentation of hypothyroidism (cardiac murmur though is not that common)].

709. An alcoholic who has completely given up drinking hears voices. What is the most appropriate tx?

- a. Olanzapine
- b. Diazepam
- c. Acamprosate
- d. Disulfiram
- e. Haloperidol

Ans. The key is A. Olanzapine. This is wrong key. Correct key is B. Diazepam. [A case of delirium tremens. Treated with benzodiazepines like chlordiazepoxide or diazepam].

710. A 6yo boy has completed an induction course of chemo for ALL. He has an enlarged left scrotum. What is the most appropriate next step?

- a. Herniotomy
- b. CT abdomen
- c. Biopsy
- d. Immediate surgery
- e. Reassurance

Ans. The key is B. CT abdomen. This is wrong key. Correct key is C. Biopsy. [Relapse may directly involve testis and excisional biopsy is done to confirm recurrence of leukemia].

Ref: Link: <http://ascopubs.org/doi/full/10.1200/jco.2009.23.8014>

711. A 32yo miner is rescued after being trapped under a fallen rock for 4h. After applying a bladder catheter, 15-20ml of reddish brown urine was obtained. HR=120bpm, SBP=100mmHg. What would be the next appropriate step?

- a. Dopamine IV
- b. Fluid challenge
- c. Furosemide IV
- d. 20% Mannitol IV
- e. Antibiotics

Ans. The key is B. Fluid challenge. [The diagnosis is rhabdomyolysis. So IV fluid is the next appropriate step].

712. A 60yo man has had spontaneous painful swelling of his right knee for 3days. 5days prv he had an inguinal hernia repaired as a day case. He takes bendroflumethiazide 2.5mg daily. He is apyrexial. What is the single most appropriate diagnostic inv?

- a. Blood culture
- b. CRP
- c. D-dimer
- d. XR knee
- e. Serum uric acid

Ans. The key is E. Serum uric acid. [Thiazide diuretics causes hyperuricemia which can precipitate acute attack of gout].

713. A 27yo woman with anxiety and weight loss has tachycardia, tremor and mild proptosis. What single mechanism accounts for her weight loss?

- a. Deficiency in thyroid hormone
- b. Increased level of calcitonin
- c. Increased metabolic rate
- d. Insulin resistance
- e. Reduced caloric intake

Ans. The key is C. Increased metabolic rate. [The given features are of thyrotoxicosis in which increased metabolism causes loss of patients weight].

714. A man with carcinoma and multiple metastasis presents with intractable nausea and vomiting. He has become drowsy and confused. What is the most appropriate management?

- a. Dexamethasone IM
- b. Dexamethasone PO
- c. Ondansetron IM
- d. Ondansetron PO
- e. Morphine oral

Ans. The key is C. Ondansetron IM. [For cancer or chemotherapy induced vomiting ondansetron is the drug of choice. As here vomiting is intractable IM ondansetron should be given not oral].

715. A 19yo man presents with weight loss, increasing thirst and increasing frequency of going to the washroom. His father, grandfather and 2 sisters have been dx with DM. What is the most likely type of DM this pt suffers from?

- a. IDDM
- b. NIDDM
- c. LADA
- d. MODY
- e. DKA

Ans. The key is D. MODY. [Key features of MODY are: Being diagnosed with diabetes under the age of 25 and having a parent with diabetes, with diabetes in two or more generations].

716. A 42yo woman with a PMH of severe headache treated in the ED presents with signs and symptoms of renal failure. She has been seen by her GP for HTN and abdominal pain with OP inv pending. Which inv is most likely to lead to a dx?

- a. US KUB
- b. CT brain
- c. IVU
- d. Renal artery Doppler
- e. Renal biopsy

Ans. The key is A. US KUB. [Hypertension, abdominal pain and features of renal failure indicates the diagnosis of ADPKD for which the diagnosis is best made by US KUB].

717. In perforation of a post gastric ulcer, where will the fluid accumulate in the peritoneal cavity?

- a. Left paracolic gutter
- b. Pelvic cavity
- c. Lesser sac
- d. Under the diaphragm
- e. Right paracolic gutter

Ans. The key is C. Lesser sac.

718. A 62yo male is brought to the ED by his daughter because of his persistent lying. He is a known alcoholic and has been admitted recently with delirium tremens. On questioning, he denies any problem with memory. He knows his name and address and states that he was at the betting shop this morning, but his daughter interjects calling him a liar explaining that he was at her home. What is the most likely dx?

- a. Ganser syndrome
- b. Cotard syndrome
- c. Wernicke's encephalopathy
- d. Korsakoff psychosis
- e. Alcohol withdrawal

Ans. The key is D. Korsakoff psychosis. [In Korsakoff psychosis there is confabulation (a memory disturbance, defined as the production of fabricated, distorted or misinterpreted memories about oneself or the world, without the conscious intention to deceive) which may present like this].

719. A 70yo man presented with muscle weakness and inability to climb the stairs. Inv: CPK raised, ESR 15. What is the most likely dx?

- a. Polymyositis
- b. Polymyalgia rheumatic
- c. Reactive arthritis
- d. RS
- e. Duchenne's MD

Ans. The key is A. Polymyositis. [Proximal muscle weakness (inability to climb the stairs) and raised CPK points towards polymyositis].

720. A 65yo known alcoholic is brought into the hospital with confusion, aggressiveness and ophthalmoplegia. He is treated with diazepam. What other drug would you like to prescribe?

- a. Antibiotics
- b. Glucose
- c. IV fluids
- d. Disulfiram
- e. Vit B complex

Ans. The key is E. Vit B complex. [This is a case of Wernicke's encephalopathy which is treated with Vit B complex].

721. A pt suffering from schizophrenia laughs while talking about his father's death. Which term best describes his condition?

- a. Depression
- b. Flat affect
- c. Emotional lability
- d. Incongruent affect
- e. Clang association

Ans. The key is D. Incongruent affect. [Incongruent affect means inappropriate emotional response like laughing hearing a sad news or crying hearing a good news].

722. A 72yo man has been on warfarin for 2yrs because of past TIAs and strokes. What is the most imp complication the pt should be careful with?

- a. Headache
- b. Osteoporosis
- c. Ear infection
- d. Limb ischemia
- e. Diarrhea

Ans. The key is B. Osteoporosis. It is a wrong key. The correct option is A. Headache. [Headache from intracranial hemorrhage is more important complication about which patient should be careful with (it is more important than osteoporosis)].

723. A 24yo woman is afraid to leave her house as whenever she goes out, she tends to have SOB and sweating. She has stopped going out except with her husband. What is the most likely dx?

- a. Social phobia
- b. Claustrophobia
- c. Depression
- d. Panic disorder
- e. Agoraphobia

Ans. The key is E. Agoraphobia. [Agoraphobia: Extreme or irrational fear of open or public places].

724. A pt on HTN drugs develops hyperkalemia. Which anti-HTN is likely to cause it?

- a. Ramipril
- b. Losartan
- c. Thiazide
- d. Nifedipine
- e. Furosemide

Ans. The key is A. Ramipril. [Both ramipril and losartan can cause hyperkalemia].

725. A young man develops itching worse at night and following bathing. Exam: greysish white linear rash can be seen on the wrist and periumbilical area. What is the dx?

- a. Scabies
- b. Polycythemia
- c. Urticarial
- d. Atopic eczema
- e. Lichen planus

Ans. The key is A. Scabies.

726. A 40yo lady who has been a smoker since she was a teenager has the following blood result: Hgb=19. What hormone should you check?

- a. Aldosterone
- b. Cortisol
- c. Erythropoietin
- d. T4
- e. TSH

Ans. The key is C. Erythropoietin. [Smoking causes raised carboxyhemoglobin level causing hypoxemia and raised erythropoietin which leads to raised hemoglobin level (secondary polycythemia)].

727. A 25yo man presents with hoarseness of voice. He has swollen vocal cords. His BMI=32 and he smokes 20-25 cigarettes/day. What would you advise him?

- a. Stop smoking
- b. Lose weight

Ans. The key is A. Stop smoking.

728. A 64yo male was admitted to the medical ward with complaint of diarrhea, abdominal pain and weight loss for few months. Exam: clubbing, perianal skin tags and abdominal tenderness. Colonoscopy reveals transmural granulomatous inflammation involving ileocecal junction. He was dx with what?

- a. CD
- b. UC
- c. Bowel cancer
- d. Gastric cancer
- e. IBD

Ans. The key is A. CD. [The given picture is typical of Crohn's disease].

729. A pt presents with hemoptysis 7d after tonsillectomy. What is the next step?

- a. Packing
- b. Oral antibiotics and discharge
- c. Admit and IV antibiotics
- d. Return to OT and explore
- e. Ice cream and cold fluids

Ans. The key is C. Admit and IV antibiotics. [Secondary hemorrhage can occur from sloughing of tissue from surgical wound following infection].

730. A 55yo man presents with HTN. He complains of headache and visual disturbances. He also reports itching after a hot bath and burning sensation in finger and toes. His face is flushed red. PE: mild splenomegaly. Inv: Hgb=20g/dl, WBC=20, plt=500, EPO normal. What is the likely dx?

- a. Myelofibrosis
- b. Polycythemia rubra vera
- c. Essential thrombocythemia
- d. CML
- e. CLL

Ans. The key is B. Polycythemia rubra vera. [Raised hemoglobin, raised cell counts and normal erythropoietin along with symptoms of hyperviscosity like headache and associated hypertension are diagnostic of polycythemia rubra vera].

731. An old man having T2DM with increased skin tanning, heart failure and having high ferritin (hemochromatosis) level is refusing tx. Where is the first site of cancer?

- a. Testes
- b. Adrenal
- c. Liver
- d. Pancreas

Ans. The key is C. Liver.

732. A 60yo DM lady presents with severe peri-anal pain and swelling. What's the cause?

- a. Anal carcinoma
- b. Anal fissure
- c. Hemorrhoid
- d. Anal abscess

Ans. The key is D. Anal abscess. [Diabetes predisposes infection to occur easily].

733. A woman is sad, fatigued and she is eating more and also has sleeping disturbance and hears the voice of her husband who died 3yrs ago. What is the dx?

- a. OCD
- b. Psychotic depression
- c. Grieving
- d. Severe depression

Ans. The key is B. Psychotic depression. [Here features of atypical depression along with hallucination makes the likely diagnosis to be psychotic depression].

734. A 40yo teetotaler woman is recovering from a hysterectomy 2days ago. At night she becomes agitated and complains of seeing animals and children walking around the ward. What is the most likely dx?

- a. Delirium tremens
- b. Toxic confusional state
- c. Hysteria
- d. Mania
- e. Drug induced personality disorder

Ans. The key is B. Toxic confusional state. [This is not delirium tremens as the woman is teetotaler].

735. A woman with a hx of drug abuse and increased alcohol intake, now comes for help and she is concerned about her problem. What is the most appropriate management option?

- a. Voluntary admission
- b. Psychiatry team
- c. Mental health team
- d. Psychiatry voluntary admission

Ans. The key is B. Psychiatry team.

736. A 28yo woman who is 32 wks pregnant in her 3rd pregnancy is diagnosed as a case of placental abruption. After all the effective measures, she is still bleeding. What is the underlying pathology?

- a. Clotting factor problem
- b. Claustr's syndrome
- c. Platelet problem
- d. Succituate lobe
- e. Villamentous insertion of placenta

Ans. The key is A. Clotting factor problem.

737. An old woman having decreased vision can't see properly at night. She has changed her glasses quite a few times but with no effect. She has normal pupils and cornea. What is the most likely dx?

- a. Cataract
- b. Glaucoma
- c. Retinal detachment
- d. Iritis
- e. GCA

Ans. The key is A. Cataract. [glaucoma may have dilated oval pupil].

738. A 53yo man was admitted to the hospital for inv of hemoptysis. 3 days after admission he developed alternating state of consciousness, ataxic gait and some visual problems. What is the most appropriate management of this pt?

- a. Acamprosate
- b. Chlordiazepoxide
- c. Diazepam
- d. High potent vitamins
- e. Disulfiram

Ans. The key is D. High potent vitamins. [This is a case of Wernicke's encephalopathy (as hospital admission prevented him from consuming alcohol) and the treatment for this is high potent vitamins].

739. A pt underwent hip surgery. Later he presents with SOB and chest pain. What is the dx?

- a. Pulmonary embolism
- b. MI
- c. Tension pneumothorax
- d. Fat embolism
- e. None

Ans. The key is A. Pulmonary embolism.

740. A 25yo man presents with hx of breathlessness. A transthoracic echo reveals a patent foramen ovale. What diagnostic inv would you do for a patent foramen ovale?

- a. Transesophageal echo
- b. Bubble echo
- c. Transthoracic echo
- d. ECG

Ans. The key is B. Bubble echo. [Bubble echo is actually extension of transoesophageal echo in that here additional bubbles are added during transoesophageal echo to get better visualization of foramen ovale].

741. A 25yo woman with a hx of several episodes of depression is brought to the ED after she was found with several empty bottles of her meds. She complains of coarse tremor, nausea and vomiting. Which of the following drugs is likely to have caused her symptoms?

- a. Fluoxetine
- b. Amitryptilline
- c. Lithium
- d. Phenelzine
- e. Olanzapine

Ans. The key is C. Lithium. [Side effect of lithium is fine tremor (in therapeutic dose) but lithium toxicity or lithium poisoning causes coarse tremor. Coarse tremor, nausea and vomiting are well known feature of lithium overdose].

742. A 23yo man feels anxious and agitated when faced with stress. He has an interview in 3days and would like some help in relieving his symptoms. What is the most appropriate management?

- a. SSRI
- b. CBT
- c. Propranolol
- d. Diazepam

Ans. The key is C. Propranolol. [Inappropriate anxiety during interview is performance phobia which is better helped by propranolol when help needed for short term like here as 3 days].

743. An 8yo boy dx with asthma is on salbutamol and beclomethasone. However, he wakes up at night due to his symptoms. What is the next appropriate management?

- a. LABA
- b. High dose steroid
- c. Aminophylline
- d. Oral prednisolone
- e. Sodium cromoglycate

Ans. The key is A. LABA. [Patient is in step2 with poor control. So next step is to add LABA and if still not controlled give high dose inhaled corticosteroids].

744. A woman presents with a hx of poisoning 10x with different substances. There are no obvious signs of depression or suicidal behavior. What is the best preventive step?

- a. Open access to ED
- b. 24h help line
- c. CBT
- d. Anti-depressants
- e. Insight into problem

Ans. The key is E. Insight into problem. [Patient is not depressed and there is no suicidal behaviour. Despite repeated poisoning may indicate she is facing some stress and so insight into her problem should be sought for].

745. A boy was rushed to the ED unconscious after he had taken methadone belonging to the sister. He was given naloxone and he regained consciousness. After a while he started getting drowsy again. What is responsible for his present drop in level of consciousness?

- a. Naloxone is absorbed faster than methadone
- b. Methadone is absorbed faster than naloxone
- c. He has also taken another substance apart from methadone
- d. The methadone had already caused some brain damage
- e. Naloxone is eliminated faster than methadone

Ans. The key is E. Naloxone is eliminated faster than methadone.

746. A 24yo male on remand in prison for murder is referred by the prison doctor. He is noted to be behaving oddly whilst in prison and complains of seeing things. He has a prv hx of IV drug abuse. On questioning he provides inappropriate but approximate answers to all questions stating that Bill Clinton is the prime minister of England. What is the prisoner suffering from?

- a. Capgras syndrome
- b. Cotard syndrome
- c. Ganser syndrome
- d. Ekbom syndrome
- e. Tourette's syndrome

Ans. The key is C. Ganser syndrome. [Ganser syndrome is characterized by nonsensical or wrong answers to questions or doing things incorrectly often with visual pseudohallucinations and a decreased state of consciousness. It is also sometimes called prison psychosis, because the syndrome occurs most frequently in prison inmates, where it may represent an attempt to gain leniency from prison or court officials].

747. A 32yo lady has recently become more active, sleeps less and bought a house and 2 new cars. What is the most likely dx?

- a. Bipolar disorder
- b. Mania
- c. Hypomania
- d. Schizophrenia

Ans. The key is C. Hypomania. [Individuals in a hypomanic state have a decreased need for sleep, are extremely outgoing and competitive, have a great deal of energy and are otherwise often fully functioning (unlike full mania where unlike fully functioning there is **a.** obvious difficulties at work or in social relationships and activities **b.** requires admission to hospital to protect the person or others, or **c.** the person is suffering psychosis)].

748. The body of a 65yo man who was treated for TB and bronchitis was seen at autopsy. His legs were swollen and his liver showed signs of a transudate fluid. What was the cause of the transudate?

- a. Liver cirrhosis
- b. Alcoholic liver disease
- c. Cardiac failure
- d. Budd-chiari syndrome
- e. TB

Ans. The key is C. Cardiac failure.

749. A 60yo woman has tiredness. She has noticed that her skin looks permanently tanned and she describes dizziness on standing up. What is the single most likely electrolyte pattern to be found?

- a. Na+=120mmol/L, K+=5.9mmol/L
- b. Na+=125mmol/L, K+=2.9mmol/L
- c. Na+=140mmol/L, K+=4.5mmol/L
- d. Na+=150mmol/L, K+=3.5mmol/L
- e. Na+=150mmol/L, K+=5.9mmol/L

Ans. The key is A. Na+=120mmol/L, K+=5.9mmol/L. [Tanned skin (hyperpigmentation) and postural hypotension in a tired women points towards Addison's disease where hyponatremia and hyperkalemia is seen].

750. A 20yo girl with amenorrhea and BMI of 14 still thinks she has to lose weight. What is the most likely dx?

- a. Anorexia nervosa
- b. Bulimia nervosa
- c. OCD
- d. Depression
- e. Body dysmorphic disorder

Ans. The key is A. Anorexia nervosa.

751. A guy who has several convictions and has been imprisoned several times, breaks up with his family and doesn't contact his children. What type of personality disorder is this?

- a. Borderline
- b. Antisocial
- c. Schizotypal
- d. Schizoid
- e. Criminal

Ans. The key is B. Antisocial. [Antisocial personality disorder is characterized by a pervasive pattern of disregard for, or violation of, the rights of others. There may be an impoverished moral sense or conscience and a history of crime, legal problems, and impulsive and aggressive behavior].

752. A 17yo lady presents with a worm in her ear. She is very agitated and anxious. What is the next step?

- a. Remove under GA
- b. Suction
- c. Alcohol drops
- d. Forceps

Ans. The key is C. Alcohol drops. [It is a living object. So it should be killed first and so alcohol drop is the correct option].

753. A 20yo male smoker is noted to have intense rubor of the feet and absent foot pulse. Exam: amputated right 2nd toe. What is the most probable dx?

- a. Intermittent claudication
- b. Cardiovascular syphilis
- c. Buerger's disease
- d. Embolism
- e. Acute limb ischemia

Ans. The key is C. Buerger's disease. [The traditional diagnosis of Buerger's disease is based on 5 criteria (smoking history, onset before the age of 50 years, infrapopliteal arterial occlusive disease, either upper limb involvement or phlebitis migrans, and absence of atherosclerotic risk factors other than smoking). As there is no specific diagnostic test and an absence of positive serologic markers, confident clinical diagnosis should be made only when all these 5 criteria have been fulfilled].

754. A young lady after a heavy bout of drinking last night comes to the ED with dizziness, abdominal pain, vomiting blood with cool peripheries. After initial resuscitation, oxygen and fluids, she still continues to bleed with pulse=130bpm and BP=85/58mmHg. What would be your next best management?

- a. Clotting screen
- b. US
- c. CT
- d. Endoscopy
- e. Omeprazole

Ans. The key is D. Endoscopy. [In young it is unlikely to get oesophageal varices rather than the bleeding is from probable gastric erosion and endoscopy should be done (diagnostic and therapeutic-like sclerotherapy)].

755. A 12yo boy complains of acute development of purpura on the dependent areas of his body 2wks after a URTI. The purpura doesn't blanch on pressure, tests reveal: Hgb=12, plts=50, WBC=5. Bleeding time=10mins, APTT=40s, PT=1.02. What is the most likely dx?

- a. ITP
- b. TTP
- c. Von Willebrand's disease
- d. Hemophilia A
- e. Hemophilia B

Ans. The key is A. ITP. [Isolated thrombocytopenia and H/O prior URTI with development of purpura on the dependent areas of the body favours the diagnosis of ITP. (In ITP BT is prolonged which is present here.)].

756. A woman presents with hx of falls, becomes pale and clumsy. She is hypertensive and takes atenolol, bendroflumethiazide and amlodipine. What inv is needed?

- a. 24h ECG
- b. 24h BP monitoring
- c. ECG
- d. Echo
- e. CT head

Ans. The key is B. 24h BP monitoring. [All these drugs (particularly prolonged use of thiazide and amlodipine) are well established cause of postural hypotension. So 24 hour BP monitoring should be done].

757. A 43yo woman has been feeling lethargic and tired. Her BP=160/90mmHg. Bloods: Na+=140mmol/L, K+=3.1mmol/L. What is the most likely dx?

- a. Cushing's syndrome
- b. Conn's syndrome
- c. Hyperparathyroidism
- d. Renal disease
- e. Pheochromocytoma

Ans. The key is B. Conn's syndrome. [Here potassium is < 3.5, sodium is at its high normal and hypertension is present so no confusion that it is conn's syndrome. Cushing's syndrome is a D/D but it has typical clinical feature which is usually described if the question is for Cushing's syndrome. Below is picture reference of Conn's syndrome from patient.info. It can also be Cushing's syndrome! So if we like to be sure we have to know aldosterone and rennin level. i) Renin low, aldosterone high- Conn's syndrome (primary hyperaldosteronism) ii) Renin low, aldosterone low- Cushing's syndrome iii) Renin high, aldosterone high- Renovascular disease (secondary hyperaldosteronism)].

Presentation

Classic features include:

- Hypertension.
- Hypokalaemia (usually <3.5 mmol/L, **although 70% of patients may be normokalaemic**).
- Metabolic alkalosis.
- Sodium may be normal or at the high end of normal.

Reference: patient.info

758. A 2yo child aspirated a foreign object which was removed at the hosp. the parents are now asking how to remove it if that ever happens at home. What do you advise?

- a. Hemlich maneuver
- b. Bring to the hospital
- c. Turn the child on his back and give thumps
- d. CPR
- e. Remove manually by fingers

Ans. The key is C. Turn the child on his back and give thumps.

759. A 28yo pregnant lady presents with severe lower abdominal pain with excessive per vaginal bleeding at 34wks gestation. What should be the initial inv of choice?

- a. Coagulation profile
- b. US abdomen
- c. CT pelvis
- d. D-dimer
- e. Kleiuber test

Ans. The key is B. US abdomen. [Likely case of abruption placenta (as excessive bleeding probably revealed type) for which initial investigation of choice is US abdomen. Other features that will favour abruption is hard uterus and evidence of fetal distress. It will be difficult to feel the fetal parts].

760. A 3yo child with severe diarrhea and vomiting, looks lethargic, has sunken eyes and a feeble cry. What is the choice of fluids?

- a. 0.9%NS
- b. 0.9%NS + 5%Dextrose
- c. 0.45%NS + 5%Dextrose
- d. 0.45%NS

Ans. The key is A. 0.9% NS. [Patient has features of severe dehydration and should be resuscitated first and for resuscitation fluid of choice is 0.9% NS].

761. A lady with depression has a bag full of meds. She now presents with coarse tremors. Which drug caused her symptoms?

- a. Lithium
- b. Thyroxine
- c. Amitriptyline
- d. Sodium valproate
- e. Tetrabenazine

Ans. The key is A. Lithium. It is a wrong key! Right key is D. Sodium valproate. [Side effect of lithium in therapeutic range is fine tremor. Sodium valproate (a well known mood stabilizer) can cause coarse tremor in therapeutic range].

762. A 38yo man has had a liver biopsy as part of inv for abnormal LFTs. The pathologist report states: special stains demonstrate the presence of a very large amount of iron pigment within the hepatocytes. What single condition is identified by the pathologists report?

- a. Alpha 1 antitrypsin deficiency
- b. Hemangioma
- c. Hemochromatosis
- d. Hemosiderosis
- e. Wilson's disease

Ans. The key is D. Hemosiderosis. It is a wrong key! The correct key

should be C. Hemochromatosis. [In hemochromatosis distribution pattern of iron in liver biopsy by pearl's stain is more prominent iron granules in periportal hepatocyte and relative sparing of kupffer cells and decreased intensity near the central vein. By contrast iron overload in hemosiderosis causes to accumulation of iron granules predominantly in kupffer cells and more in central area rather than peripheral hepatocyte. In given case there are large amount of iron pigment in hepatocyte which is diagnostic of hemochromatosis].

763. A 27yo man presents to the ED after an RTA where his foot was stuck under a truck for several hours. He now has swelling on the foot. Exam: foot tenderness, loss of sense in the space between the 3rd metatarsal and big toe and his dorsalis pedis is not felt. What is the most likely dx?

- a. Compartment syndrome
- b. Arterial rupture
- c. Arterial embolus
- d. DVT
- e. Fibular fx

Ans. The key is A. Compartment syndrome. [Acute compartment syndrome occurs after a traumatic injury such as a car crash. The trauma causes a severe high pressure in the compartment which results in insufficient blood supply to muscles and nerves. Acute compartment syndrome is a medical emergency that requires surgery to correct. If untreated, the lack of blood supply leads to permanent muscle and nerve damage and can result in the loss of function of the limb].

764. You are a FY doctor in the ED when a mother brings her 2yo son to you with a 1h hx of noisy breathing. She state that although he had mild coryza over the last week, he was improving and so they had gone to a children's picnic with nursery friends. Another parent had found him coughing and spluttering, and ever since his breathing has remained noisy. Though he appears well in the ED, his current observations demonstrate a raised RR and sat=91% on air. What is the most likely dx?

- a. Anaplyaxis
- b. Croup
- c. Foreign body aspiration
- d. Epiglottitis

Ans. The key is C. Foreign body aspiration.

765. A pt taking doxycycline complains of nausea, indigestion, abdominal pain and vomiting. What will you advise?

- a. Take it after meals
- b. Take it before meals
- c. Stop the drug
- d. Take antacids
- e. Take antiemetic

Ans. The key is A. Take it after meal.

766. A 52yo man with hx of ant MI 3 wks ago developed sudden onset of dyspnea. Exam: BP=100/60mmHg, pulse=100bpm, SaO2=88%, chest=bilateral crackles. Which inv would you do to find the underlying cause?

- a. CXR
- b. Echo
- c. D-dimer
- d. Radionucleotide lung scan
- e. Troponin

Ans. The key is A. CXR. It is wrong key. Correct key should be B. Echo. [The question does not want to know the features of pulmonary oedema rather it is clearly mentioned "which investigation would you do to find out the UNDERLYING CAUSE". As in this patient sudden papillary muscle rupture or VSD may be the likely cause (ventricular aneurism may take a more slower course) so echo seems to be more logical approach].

767. A 49yo man lost his job and now is homeless. He was found wandering in the park. He is muttering that some people are after him. Alcohol was tested and it was negative. What will your next step be?

- a. Thiamine
- b. Neuropsych analysis
- c. Mini mental state
- d. CT head
- e. MRI head

Ans. The key is B. Neuropsychanalysis. [As the patient has persecutory delusion he is likely suffering from psychosis for which neuropsychanalysis is the logical approach].

768. A pt with SNHL and loss of corneal reflex on the left side. What is the most definitive inv?

- a. CT of internal auditory meatus
- b. Nuclear imaging of brain
- c. MRI of internal auditory meatus
- d. Radio isotope scan
- e. XR skull

Ans. The key is C. MRI of internal auditory meatus. [The likely cause is acoustic neuroma for which appropriate investigation is MRI internal acoustic meatus].

769. A middle aged man complains of a node which has been growing on his nose for several months. Now it's firm with central depression. It is 0.6cm in size. What is the single most likely dx?

- a. Basal cell carcinoma
- b. Squamous cell carcinoma
- c. LN
- d. Melanoma
- e. Kaposi's sarcoma
- f. Keratoacanthoma
- g. Molluscum contagiosum

Ans. The key is A. Basal cell carcinoma. [A pearly white umbilicated ulcer (with central depression) any where in the face with rolled edges / inverted edge is basal cell carcinoma. Any ulcer which is located above the neck is always basal cell carcinoma until proven otherwise. (Samson note)].

770. A 45yo woman presents with rotational vertigo, nausea and vomiting, especially on moving her head. She also had a similar episode 2yrs back. These episodes typically follow an event of runny nose, cold, cough and fever. What is the most probable dx?

- a. Acoustic neuroma
- b. Meniere's disease
- c. Labyrinthitis
- d. BPPV
- e. Vestibular neuronitis

Ans. The key is E. Vestibular neuronitis. [Here no sensoryneural hearing loss (SNHL) present in acoustic neuroma, Meniere's disease and labyrinthitis). Runny nose, cold, cough and fever are recognized trigger of vestibular neuronitis but not BPPV].

771. A 65yo man with cancer of middle 1/3 of the esophagus presents with dysphagia. What is the most immediate management?

- a. Chemotherapy
- b. Radiotherapy
- c. Stenting
- d. Gastrostomy
- e. TPN

Ans. The key is C. Stenting.

772. A 1yo child is brought to ED. He woke up in the middle of the night crying severely. What initial measure should be taken for this child?

- a. Refer to surgeon
- b. Discharge with advice
- c. Analgesia
- d. Antibiotic

Ans. The key is C. Analgesia.

773. A 30yo lady was playing volleyball when her hand got injured with the ball. The right hand is not swollen and there is tenderness under the root of the thumb. XR is normal. What is the most appropriate next management?

- a. Arm sling for 1 wk
- b. Raise hand for 2d
- c. Repeat XR
- d. Full arm cast

Ans. The key is C. Repeat XR. [Likely diagnosis is scaphoid fracture where X-ray may not show the fracture right away. In such case put her hand in a below elbow cast and repeat X-ray in a week or two to see if the fracture become visible. Usually it becomes visible as a healing fracture line].

774. A 33yo female presents with sudden severe colicky abdominal pain in her RIF. A mobile mass is felt on examination. What is the most likely dx?

- a. PID
- b. Appendicitis
- c. Ovarian torsion
- d. Constipation

Ans. The key is C. Ovarian torsion.

775. A middle aged male is feeling unwell after a recent MI. The recent ECG shows prolonged QRS complex and tented T wave. Na+=136mmol/l, K+=6.2mmol/l, urea=5mmol/l. What is the most appropriate management?

- a. Calcium gluconate
- b. Calcium resonium
- c. Calcium with vit D supplement
- d. Vit D
- e. Calcium

Ans. A. Calcium gluconate. [ECG change of prolonged QRS complex and tented T wave are suggestive of hyperkalaemia which is further supported by K+ level of 6.2 mmol/l. So to protect the heart from arrhythmia calcium gluconate should be given].

776. A 68yo man with DM and HTN was noted to have cholesterol level of 3.4mmol/l. he was also noted to have microalbuminuria. What is the best drug to add to his regimen?

- a. ACEi
- b. Statin
- c. Amlodipine
- d. Biguanides

Ans. The key is A. ACEI. [ACEI is renoprotective and prevents progress in albuminuria].

777. A child playing with toys suddenly develops breathlessness and stridor. Which inv will lead to the dx?

- a. Laryngoscopy
- b. CXR
- c. Peak flow meter
- d. ABG

Ans. The key is A. Laryngoscopy. [Breathlessness and stridor in a child playing with toy is most likely due to aspiration of foreign body (toy or part of toy) for which laryngoscopy should be done].

778. Anxious parents ask you for resus technique for their 3yo. What do you tell them?

- a. 5 compression: 1 breath
- b. 5 compression: 2 breaths
- c. 15 compression: 2 breaths with nose pinched
- d. 15 compression: 2 breaths without nose pinched
- e. 30 breaths: 2 compressions

Ans. The key is C. 15 compression:2 breaths with nose pinched.

779. A 56yo man complains of increased vol of sputum with specks of blood and chest pain. He has a hx of DVT. Exam: clubbing. What is the cause of blood in his sputum?

- a. Pulmonary thrombosis
- b. Bronchial carcinoma
- c. Bronchiectasis
- d. Pulmonary TB

Ans. The key is C. Bronchiectasis. [Increased volume of blood streaked sputum and clubbing points towards bronchiectasis].

780. A 32yo female has a hx of SOB and fever. Pre-broncho-dilation test was done and it was 2/3.5 and post-bronchodilator was 3/3.7. The pt was dx of eczema and TB. What is the possible dx?

- a. COPD
- b. Asthma
- c. Pneumonia
- d. Bronchiectasis

Ans. The key is B. Asthma. This is probably wrong key. Correct key is D. Bronchiectasis. [History of fever and prior TB are more suggestive of bronchiectasis and in bronchiectasis spirometry is variable (either restrictive, obstructive or normal)].

781. A 2yo male pt was brought by his mother with a swelling in the right side of his neck extending from the angle of the mouth to the middle 1/3 of the sternocleidomastoid muscle. The swelling was on the anterolateral side of the sternocleidomastoid and was brilliantly transilluminant. What is the likely dx?

- a. Lymphangioma
- b. Branchial cyst
- c. Thyroglossal cyst
- d. Ranula
- e. Thyroid swelling

Ans. The key is B. Branchial cyst. It is a wrong key. Correct key is A. Lymphangioma. [Both lymphangioma and branchial cyst are lateral neck mass. 90% of lymphangioma occur in children less than 2 yrs. Branchial cyst usually does not transilluminate whereas lymphangioma usually transilluminate brilliantly].

782. A 50yo newly dx with HTN complains of urinary freq and dysuria. The urinalysis reveals presence of white cells and protein. Choose the single most appropriate tx?

- a. Imipramine
- b. Adjust diuretics
- c. Vaginal estrogen
- d. Trimethoprim

Ans. The key is D. Trimethoprim. [Symptoms (urinary frequency and

dysuria) along with white cells and protein in urine suggest UTI. Treatment is with triethoprim].

783. A boy injured his ear during a rugby match. He reported it being painful. Exam: red and tender pinna. Tympanic membrane was normal. What would be the next appropriate step?

- a. Topical gentamicin
- b. Oral flucloxacillin
- c. IV flucloxacillin
- d. Refer to ENT specialist
- e. No further intervention needed.

Ans. The key is E. No further intervention needed. [As tympanic membrane is normal so this transient inflammation of pinna from injury during rugby match is self limiting which needs no further intervention].

784. A 2yo girl prv well presents with a hx of vomiting and diarrhea for 4hrs. What is the most suitable indication for IV fluid administration?

- a. Capillary refill time >4s
- b. HR >90bpm
- c. Increased RR
- d. Stool >10x/d
- e. Weight of child = 10kgs

Ans. The key is A. Capillary refill time >4s. [Capillary refill time >4s is sign of severe dehydration indicating need for IV fluid administration. Features of severe dehydration: i) abnormally sleepy or lethargic ii) sunken eyes iii) drinking poorly or not at all iv) reduced skin turgor > 2 seconds v) dry tongue and mucous membrane vi) absent tears vii) oliguria viii) hypotension ix) tachycardia x) prolonged capillary refill time xi) depressed anterior fontanelle].

785. A 44yo woman with breast cancer had an extensive removal and LN clearance. She needs an adjunctive tx. Her mother had cancer when she was 65. Which of the following factors will be against the tx?

- a. Fam hx
- b. Tumor grading
- c. LN involvement
- d. Her age

Ans. The key is D. Her age. Probably wrong key. Correct key should be B. Tumour grading. [What ever the age oestrogen receptor positive patient will take tamoxifen as adjuvant therapy. But tumour grading in some instance may influence the need of adjuvant therapy. Though the given key is D it is probably a wrong key and correct key should be B. Tumour grading].

Summary points

- Adjuvant tamoxifen citrate benefits all women who have hormone-sensitive breast cancer
- Adjuvant chemotherapy benefits all women who have breast cancer, but the proportional benefits are greater in women younger than 50 years
- The proportional reduction in recurrence and mortality as a result of adjuvant treatment is the same for each patient, but the absolute benefits depend on a patient's risk
- Women with smaller-than-1 cm, node-negative, estrogen receptor-positive breast cancer of low histologic grade have an excellent prognosis without further therapy
- Treatment decisions should be individualized, taking into consideration the clinical evidence and a patient's overall health treatment preferences

786. A 45yo man presents with hearing loss and tinnitus in the right ear. Exam: weber test lateralizes to the left. Audiometry: AC > BC in both ears. What is the next best inv?

- a. CT
- b. MRI brain
- c. Angiogram
- d. Otoscopy

Ans. The key is B. MRI brain. [AC>BC indicate Rinne positive; i.e. The deafness is not conductive. Again hearing loss is on right side. Weber lateralized to left. We know weber lateralized to same side if conductive deafness and to opposite if there is sensoryneural deafness. So it is now obvious that the deafness of right ear is sensoryneural deafness for which MRI brain is the next best investigation].

787. A 74yo lady called an ambulance for an acute chest pain. She has a hx of DM and HTN, and is a heavy smoker. Paramedics mentioned that she was overweight and recently immobile because of a hip pain. She collapsed and died in the ambulance. What is the most likely cause of death?

- a. Pulmonary embolism
- b. MI
- c. Stroke
- d. Cardiac arrhythmia
- e. Cardiac failure

Ans. The key is A. Pulmonary embolism. This is wrong key! Correct key is MI.

788. A 77yo woman suffered diarrhea 4d ago. What would be her blood gas result?

- a. pH =7.2, PaCO2 =8
- b. pH =7.4, PaCO2 =1.5
- c. pH =7.4, PaCO2 =2.6
- d. pH =7.4, PaCO2 =2.8

Ans. The key is B. pH = 7.4, PaCO2 = 1.5 [Diarrhoea causes metabolic acidosis and in response there occurs respiratory compensation [hyperventilation] leading to respiratory alkalosis and low PaCO2 (due

to CO2 washout)).

789. A man presents with abdominal pain, vomiting, pulse=120bpm, BP=90/60mmHg and a rigid abdomen. His chest is clear. What is the immediate management?

- a. Call radiology
- b. Admit to medical ward
- c. Urgent admission to ITU (Intensive Therapy Unit)

Ans. The key is C. Urgent admission to ITU.

790. A 60yo man presents with weight loss and Hgb=6. Hx reveals that he has abdominal pain and diarrhea for the past 6m. What is the most appropriate inv?

- a. Barium enema
- b. Colonoscopy
- c. Sigmoidoscopy

Ans. The key is B. Colonoscopy. [Likely diagnosis is IBD. So Colonoscopy should be done].

791. A 35yo primigravida post C-section complains of inability to void. She denies dysuria but complains of fullness. She was treated with an epidural for analgesia. What is the single most appropriate inv?

- a. MSU
- b. US abdomen
- c. US KUB
- d. Serum calcium

Ans. The key is B. US abdomen. [C. US KUB. Is also correct! This is a case of POUR (post operative urinary retention). We should do US to know the urinary volume (urine volume in bladder). If <400ml we shall observe. When volume is >600ml we should do catheterization].

792. A female pt with HTN and serum K+=2.7mmol/l. which hormone would you be looking for?

- a. Aldosterone
- b. Cortisol
- c. Thyroxine
- d. Renin
- e. Testosterone

Ans. The key is A. Aldosterone. [Hpt and hypokalemia is seen in hyperaldosteronism. So we should look for aldosterone].

793. A 25yo male with a hx of frequent binge drinking presents 4h after having had a take away meal following a nights heavy drinking. He complains of nausea and has vomited on several occasions. After the last vomiting episode, he vomited approximately a cupful of blood. On admission, he smells of alcohol, pulse=100bpm, BP=140/80mmHg. He has some tenderness in the epigastrium. What is your dx?

- a. Gastric carcinoma
- b. Mallory-weiss tear
- c. Esophageal carcinoma
- d. Esophageal varices
- e. Peptic ulceration

Ans. The key is Mallory-weiss tear. [Repeated retching and vomiting is a recognized cause of Mallory-weiss tear which is supported here by vomiting a cupful of blood].

794. A young boy presented with bilateral periorbital edema, ankle swelling and increase in body weight. What is the most likely dx?

- a. Chronic heart failure
- b. Nephrotic syndrome
- c. Renal failure
- d. Acute heart failure
- e. Glomerulonephritis

Ans. The key is B. Nephrotic syndrome.

795. A 53yo man with prv hx of COPD presents with breathlessness and purulent sputum. O2 sat=85% on air. ABG: PaO2=7.6, PaCO2=7. What is the appropriate management for his condition?

- a. 24% oxygen
- b. Mechanical ventilation
- c. 100% oxygen
- d. Nebulized salbutamol

Ans. The key is A. 24% oxygen. [Patient has hypoxemia and hypercapnea (type2 respiratory failure). Hence he should be put on 24% oxygen. 100% oxygen will abolish hypoxic drive and worsen hypercapnea].

796. A 34yo man was involved in a RTA and whilst in the ambulance his GCS deteriorated and RR increased from 30-48. What is the most appropriate management for this pt?

- a. IV fluid
- b. Needle thoracocentesis
- c. 100% oxygen
- d. Portable XR

Ans. The key is 100% oxygen.

797. A 44yo lady who has PCKD is concerned because her 38yo brother has just died of an intracranial insult. She knows he was not hypertensive. What was the most likely cause of her brother's death?

- a. Subdural hematoma
- b. Subarachnoid hemorrhage
- c. Cerebral infarct
- d. Epidural hematoma

Ans. The key is B. Subarachnoid hemorrhage. [Cerebral aneurisms are recognized association of PCKD which may lead to subarachnoid hemorrhage].

798. A 36yo male dx with glioblastoma since last 5m has cerebral edema and is on dexamethasone. He has diarrhea and vomiting for the last 3days. He has been suffering from repeated falls today. What could be the possible cause for his falls?

- a. Adrenal insufficiency
- b. Dehydration
- c. Dexamethasone therapy
- d. Raised ICP

Ans. The key is A. Adrenal insufficiency. [Prolonged dexamethason use suppresses adrenal axis and intercurrent illness can lead to adrenal insufficiency (addisonian crisis) in such cases].

799. A 2yo child is brought by his mother. The mother had hearing impairment in her early childhood and is now concerned about the child. What inv would you do?

- a. Audiometry
- b. Distraction testing
- c. Scratch test
- d. Tuning fork

Ans. The key is A. Audiometry. [Conditioned response audiometry 2-4 years, pure tone audio gram for greater than 5 years, less than 6 months otoacoustic emission or brainstem evoked response, distraction test for 6-18 months, OHCS ENT].

800. An 8yo child presents with recurrent abdominal pain, occasional headaches but maintains a good appetite. Exam: normal. CBC, BUE, etc are normal. What would you do for her next?

- a. US abdomen
- b. CT head
- c. Reassure
- d. Analgesics

Ans. The key is C. Reassure. [Recurrent abdominal pain and headaches with no abnormal finding on examination and investigation points to Abdominal Migraine. Management is reassurance and prescribe analgesics].

801. A 78yo gentleman suddenly collapsed. His HR=120bpm, BP=70/40mmHg. Exam: pulsatile mass in abdomen. What is the most appropriate dx?

- a. Aortic aneurysm
- b. Mesenteric cyst
- c. Umbilical hernia

Ans. The key is A. Aortic aneurism. [There is features of shock with pulse 120bpm and bp 70/40mmHg and sudden collapse of the patient with pulsatile mass in abdomen makes the likely diagnosis of ruptured aortic aneurism].

802. A woman prv in good health presents with sudden onset of severe occipital headache and vomiting. Her only physical sign on exam is a stiff neck. Choose the most likely dx.

- a. Subarachnoid hemorrhage
- b. Subdural hematoma
- c. Cerebellar hemorrhage
- d. Migraine
- e. Cerebral embolus

Ans. The key is A. Subarachnoid hemorrhage. [Sudden onset severe occipital headache and vomiting with stiffness makes the likely diagnosis to be subarachnoid hemorrhage].

803. A 34yo housemaid presents with headaches in the back of her head for several days and pain on flexing her neck. What is the most likely cause?

- a. Subdural hemorrhage
- b. Cervical spondylosis
- c. Subarachnoid hemorrhage
- d. Meningitis
- e. Cluster headache

Ans. The key is B. Cervical spondylosis. [Headache in the back of head and pain on flexing neck is early feature of cervical spondylosis which gradually progress to later symptoms like radiculopathies due to root compression in arms and hands].

804. A 40yo man complains of thirst and lethargy. His BP=140/90mmHg, corrected Ca^{2+} =3.7mmol/l. What is the most appropriate management at this stage?

- a. IV fluids
- b. Prednisolone
- c. IV hydrocortisone
- d. Calcium prep

Ans. The key is A. IV fluids. [Hypercalcemia is treated by IV fluids].

805. A 75yo man on digoxin develops weakness in the right upper and lower limbs which resolves within a few hours. What is the most definitive inv for this condition?

- a. Carotid Doppler
- b. Angiography
- c. CT head
- d. Digoxin level

Ans. The key is B. Angiography. Probably wrong key! Correct key is C. CT head.

[Patient on digoxin means he is being treated for atrial fibrillation with heart failure and the cause of tia is cardiac in origin! So carotid doppler or carotid angiography is not the answer. Again for tia investigation of choice is MRI (if not available CT) NICE guideline. So for this question definitive investigation is CT scan.].

806. A 35yo man presents with balance problems, headache, SNHL and loss of corneal reflex on the left side. What is the most definitive inv?

- a. CT scan of internal auditory meatus
- b. Nuclear image of the brain
- c. MRI of internal auditory meatus
- d. MRI brain

Ans. The key is D. MRI brain. Wrong key! "Most definitive" is MRI internal auditory meatus. [Probable diagnosis is left sided acoustic neuroma. For this most definitive investigation is MRI internal auditory meatus].

807. A 52yo man has a painful, red, photophobic right eye with slightly blurred vision and watering for 3days. He has had no such episodes in the past. On slit lamp examination there are cells and flare in the ant chamber and pupil is sluggish to react. What is the single most appropriate clinical dx?

- a. Acute close-angle glaucoma
- b. Acute conjunctivitis
- c. Acute dacryocystitis
- d. Acute iritis
- e. Corneal foreign body

Ans. The key is D. acute iritis. [In iritis there is flares and cells in anterior chamber. In iritis pupil may be irregular but in angle closure glaucoma pupil is slightly dilated and oval in shape. In iritis there is no halo around light but in glaucoma there is halo around light].

808. A 55yo lady with swelling on the abdomen below the umbilicus on the right side. What is the single most appropriate lymph node?

- a. External iliac LN
- b. Pre-aortic LN
- c. Aortic LN
- d. Inguinal LN
- e. Iliac LN
- f. Submental LN
- g. Submandibular LN
- h. Deep cervical LN

Ans. The key is D. Inguinal LN.

809. A 66yo male presents with painful swallowing. What is the most likely dx?

- a. Nisseria meningitidis
- b. Cryptococcus neoformans
- c. Candida albicans
- d. Isospora belli
- e. Mycobacterium avium

Ans. The key is C. Candida albicans. [Oesophageal candidiasis].

810. A 45yo lady complains of expressible galactorrhea, decreased libido and amenorrhea, weight gain and easy fatigue. Her serum prolactin levels are 1100uIU/l. What is the likely cause of hyperprolactinemia?

- a. Hypothyroidism
- b. Stress
- c. Pregnancy
- d. Prolactin secreting pituitary tumor
- e. PCOS

Ans. The key is D. Wrong key. Correct key should be A. Hypothyroidism. [It is likely to be hypothyroidism because prolactin level in hypothyroidism may be 30-200ng/ml which means 630-4200 mIU/L. Though weight gain can occur but fatigue is not a feature of prolactinoma unless it is a macroadenoma causing suppression of other pituitary hormone! given prolactin level of 1100 IU/L is definitely from a microadenoma (in macroadenoma prolactin level is > 10,000 MU/L) which does not cause fatigue. So the case most likely seems to be hypothyroidism].

811. A 42yo female had sudden severe headache and vomiting. She took paracetamol and then collapsed. What is the most likely dx?

- a. SAH
- b. Viral encephalitis
- c. Meningitis
- d. Anaphylaxis

Ans. The key is A. SAH. [Sudden headache, vomiting, collapse are suggestive of SAH].

812. Parents of a 3m baby are worried about cot death. What advice would you give?

- a. Lay on the back with feet towards head end
- b. Lay on the back with feet towards feet end
- c. Lay on side
- d. Lay on stomach

Ans. The key is B. Lay on the back with feet towards feet end.

813. A child born at 36wks developed difficulty in breathing with intercoastal recession and nasal flaring. His temp is normal but his mother had PROM 48h ago. What is the most likely inv that will lead to tx?

- a. Blood culture
- b. CXR
- c. Stool culture
- d. Sputum culture

Ans. B. CXR. This is wrong key! Correct key is A. Blood culture. [In neonates investigations of pneumonia is for sepsis as pneumonia at this age is always secondary to sepsis or a part of sepsis. Probable diagnosis is Neonatal Pneumonia as there is respiratory signs and history of PROM. In extremes of age pneumonia or sepsis may be with normal temperature or even there may be hypothermia. Here pneumonia is a part of sepsis and investigation is not CXR but blood culture!].

814. A 68yo man has had increasing dysphagia for solid food for 3m and has lost 5kgs in weight. What single inv is most likely to lead to a def dx?

- a. Barium swallow
- b. CXR
- c. CT chest
- d. Endoscopy and biopsy
- e. Video-fluoroscopy

Ans. The key is D. Endoscopy and biopsy. [Likely cause is malignant stricture for which endoscopic biopsy is the definitive investigation].

815. A 24yo male was trying to move his wardrobe but it fell on his thigh. It was there for a very long time before someone was able to remove it. When he was seen in ED he had casts in his urine but no RBCs. Other inv showed hypocalcemia and high serum creatinine. What is the cause for his renal failure?

- a. Acetylcholine
- b. Myoglobin
- c. Myotroponin
- d. Acetyl acetate

Ans. The key is B. Myoglobin. [The likely diagnosis is Rhabdomyolysis where renal failure occurs due to myoglobin (myoglobins are released after breakdown of skeletal muscles)].

816. Anatomical structure to be pierced during surgery midline port during gallstone removal.

- a. External iliac muscle
- b. Cricoid cartilage
- c. Linea alba
- d. Rectus sheath muscle
- e. Duramater
- f. 1st tracheal cartilage
- g. Conjoined tendon
- h. Intercostal muscles

Ans. The key is C. Linea alba.

817. A 48yo man has continuous ant chest pain which is worse on inspiration and has temp of 37.5C since 4wks after a MI. His ESR=45mm/h. What is the single most likely explanation for the abnormal inv?

- a. Acute pericarditis
- b. Cardiac tamponade
- c. Atrial thrombus
- d. Left ventricular aneurysm
- e. Dressler syndrome

Ans. The key is E. Dressler syndrome. [Dressler syndrome usually occurring two to five weeks after the initial event but it can be delayed for as long as three months. It is characterised by pleuritic chest pain, low-grade fever and pericarditis].

818. An 8yo child swallowed 12 tablets of paracetamol 4h ago. Serum paracetamol levels when tested were at critical level. What would you do next?

- a. Activated charcoal
- b. IV N-acetylcysteine
- c. Gastric lavage
- d. Observation only

Ans. The key is B. IV N-acetylcysteine. [As 4 hour paracetamol level is at critical level start IV N-acetyltine at once].

Management of paracetamol poisoning:

GI decontamination is recommended in those presenting <4h after OD. Activated charcoal 1g/kg (max 50g) is the treatment of choice, reducing serum levels more than gastric lavage and limiting liver injury.

• Glucose, U&E, LFT, INR, ABG, FBC, HCO₃

–; blood paracetamol level at 4h post-ingestion.

• If <10–12h since overdose, not vomiting, and plasma paracetamol is above the line

on the graph, start N-acetylcysteine.

• If >8–24h and suspicion of large overdose (>7.5g) err on the side of caution and

start N-acetylcysteine, stopping it if level below treatment line and INR/ALT normal. OHCM, 9th edition, page 856].

819. A pt dx with DVT is taking warfarin. What is his cut off INR limit?

- a. <1
- b. 1-2
- c. 2-3
- d. 3-4

Ans. The key is C. 2-3. [This range is appropriate for the prophylaxis or treatment of venous thromboembolism and reduction of the risk of systemic embolism for people with atrial fibrillation and valvular heart disease].

820. Inserting a drain in the mid-axillary line. What is the single most appropriate anatomical structure?

- a. External iliac muscle
- b. Linea alba
- c. Rectus sheath muscle
- d. Conjoined tendon
- e. Intercostal muscles

Ans. The key is E. Intercostal muscles.

821. A 29yo man presents with hx of cough, weight loss and night sweats. Exam: pansystolic murmur. What is the most appropriate dx of underlying cause?

- a. Malaria
- b. HSP
- c. HIV
- d. Dengue fever

Ans. The key is C. HIV. [Though not mentioned IV drug abusers may have tricuspid regurgitation causing pansystolic murmur and HIV also very common in this group].

822. A 15yo boy presents with recurrent breathlessness and wheeze especially after exercise. What is the most diagnostic inv?

- a. CXR
- b. Lung function test
- c. PEFR
- d. CT scan

Ans. The key is B. Lung function test. [Assessment of severity of airflow obstruction can diagnose asthma and COPD].

823. A 34yo man was walking along the country side when an insect bit him. After which he started to complain of an annular rash spreading upwards.

- a. Penicillin PO
- b. Doxycycline PO
- c. Flucloxacillin PO
- d. Gentamicin PO
- e. Ciprofloxacin PO
- f. Antihistamine PO
- g. Antihistamine IV
- h. Corticosteroid IV
- i. Corticosteroid IM
- j. Adrenaline IM
- k. Adrenaline IV
- l. Atropine IV
- m. Reassurance

Ans. The key is B. Doxycycline PO. [Described rash is erythema migrans which is characteristic skin lesion seen in Lyme disease. Lyme disease is treated with Doxycycline].

824. A 60yo man was brought in by his wife complaining of ataxia, urinary incontinence and erectile dysfunction. He also complains of rigidity and slowing of movement with a pill rolling tremor of the hands. What is the likely dx?

- a. Parkinson's disease
- b. Idiopathic parkinson's disease
- c. Shy-drager syndrome
- d. Huntington's disease

Ans. The key is C. Shy-drager syndrome. [Shy-drager syndrome is characterized by parkinsonism (rigidity, slowing of movement with hand tremors) plus a more pronounced failure of the autonomic nervous system (urinary incontinence and erectile dysfunction) and there may also cerebellar sign like ataxia be present]. [Please note the discrepancy of this question (may be a bad recall) that classic pill rolling movement is not a feature of multiple system atrophy (shy-drager syndrome)].

825. A 67yo man being managed for a malignancy develops neutropenic fever. He has been commenced on Ticarcillin, Tazobactam and Gentamicin. He has also recently commenced on Meropenem but on the 3rd day his temp still remains >39C. 2 blood tests and urine cultures show no organism. Inv: Hgb=104g/dl, WBC=<0.5, Plt=15. What will you do next?

- a. Continue IV antibiotics and add oral antifungals
- b. Continue antibiotics and add IV antifungals
- c. Stop antibiotics
- d. Continue only present antibiotics

Ans. The key is B. Continue antibiotics and add IV antifungals. [If judicial antibiotic fail to control fever next step is to add antifungal agents].

826. A young girl who is known to have T1DM presented with drowsiness and deep breathing. Her sugar level=20. Her BP=120/80mmHg and her mucous membranes are dry. What would be the next appropriate step?

- a. Serum urea
- b. Blood culture
- c. CT
- d. HbA1c
- e. ABG

Ans. The key is E ABG. [Likely diagnosis is DKA where ABG is done to demonstrate acidosis].

827. Removal of a glioma, which single most appropriate anatomical structure will be pierced?

- a. Cricoid cartilage
- b. Rectus sheath muscle
- c. Duramater
- d. Conjoined tendon
- e. Intercostal muscles

Ans. The key is C. Duramater.

828. A child is not breathing and intubation failed. At what anatomical site should the incision be made?

- a. External iliac muscle
- b. Cricoid cartilage
- c. Linea alba
- d. Rectus sheath muscle
- e. Duramater
- f. 1st tracheal cartilage
- g. Conjoined tendon
- h. Intercostal muscles

Ans. The key is B. Cricoid cartilage. [Incision for tracheostomy is done which goes down from cricoids cartilage].

829. A 10yo child who presented with fx of the radius which was treated with a plaster cast, complains of pain. Exam: limb is swollen but warm and well perfused, pulses are present. What should you do next?

- a. Send for repeat XR
- b. Remove cast
- c. Replace cast with more padding
- d. Give analgesic

Ans. Key is D. Give analgesic.

830. A 32yo man has been to Thailand and returned with cervical lymphadenopathy and fever. What is he most likely suffering from?

- a. HIV
- b. EBV
- c. Typhoid
- d. Measles

Ans. The key is B. EBV. [Cervical lymphadenopathy mentioned in question which occurs in EBV infection. In ARS (acute retroviral syndrome) or primary HIV infection there is generalized lymphadenopathy].

831. A 6yo child presents with edema and mild proteinuria. No hematuria. What is the most likely dx?

- a. PSGN
- b. Membranous GN
- c. Minimal change GN
- d. RPGN

Ans. The key is C. Minimal change GN. [Minimal change GN is usually seen in young children. It presents as edema and proteinuria].

832. An 80yo woman suffering from RA presents with severe epigastric pain and vomiting. She also complains of shoulder tip pain. What is the single most discriminatory inv?

- a. US Abdomen
- b. Sigmoidoscopy
- c. Colonoscopy
- d. Barium meal
- e. Upper GI endoscopy
- f. Erect CXR

Ans. The key is F. Erect CXR. [Elderly patient with RA is usually on NSAIDs which may lead to perforated peptic ulcer which presents as severe epigastric pain, vomiting and shoulder tip pain. Diagnosis is made by seeing free gas shadow under the diaphragm on erect CXR].

833. A 44yo man went on holiday to Sudan 5wks ago. He now presents with red urine and fever. Exam: hepatomegaly. What is the most likely dx?

- a. Malaria
- b. Brucellosis
- c. Leptospirosis
- d. Schistosomiasis

Ans. The key is D. Schistosomiasis. [Holiday in Sudan, hematuria, fever and hepatomegaly suggest Schistosomiasis].

834. A 32yo homosexual comes with hx of weight loss. Fundoscopy reveals retinal hemorrhages. What is the single most appropriate option?

- a. Mycobacterium avium
- b. CMV
- c. Hemophilus influenzae
- d. NHL
- e. Pneumocystic jirovecii

Ans. The key is B. CMV. [Weight loss in a homosexual is likely to be due to AIDS and CMV retinopathy with retinal hemorrhage is a recognized association].

835. A 30yo man comes with hx of early morning back pain and stiffness. Exam: red eyes. What is the single most appropriate option?

- a. Iris
- b. Ciliary body
- c. Cornea
- d. Conjunctivitis
- e. Sclera

Ans. The key is A. Iris. [Young man with early morning back pain and stiffness is suggestive of seronegative arthritis likely ankylosing spondylitis where iritis is a common association].

836. A 70yo woman with longstanding anxiety is seen in the OPD. She complains of her heart skipping a beat quite often. This particularly occurs when she is trying to get to sleep. The palpitations are never sustained. What is the most likely rhythm disturbance?

- a. SVT
- b. VF
- c. VT
- d. V-ectopics
- e. A-fib

Ans. The key is D. V-ectopics. [V-ectopics If occurs in a normal heart though symptomatic it is benign in nature but if it is secondary to heart disease like MI it may precipitate to more life threatening arrhythmia like ventricular fibrillation].

837. A 17yo has acute pain around his right eye, pain on one side of his face and ear ache too. What is the single most dx?

- a. Ear wax
- b. Ear foreign body
- c. Dental abscess
- d. Cellulitis
- e. Herpes zoster

Ans. The key is E. Herpes zoster. [It seems to be herpes zoster of the trigeminal nerve. Onset is acute, unilateral distribution favours herpes zoster].

838. A 12yo boy presented with itching in his hands. Exam: skin is dry and red. His mother is asthmatic and older brother has hay fever. What is the single most likely causative factor?

- a. Dermatitis herpetiformis
- b. Scabies
- c. Eczema
- d. Uremia
- e. Drug induced

Ans. The key is C. Eczema. [Itchy lesion and family history of asthma and hay fever in 1st degree relatives favours the diagnosis of eczema].

839. A 45yo man presented with pruritic purple papules on the flexor surface of his wrist and some white lacy markings on his buccal mucosa. What is the single most likely causative factor?

- a. ALL
- b. Lymphoma
- c. Polycythemia
- d. IDA
- e. Lichen planus

Ans. The key is E. Lichen planus. [White lacy pattern of lesion is characteristic of lichen planus].

840. A known DM was admitted with sudden LOC. What is the initial inv?

- a. CT scan
- b. RBS
- c. MRI
- d. ECG
- e. ABC

Ans. The key is B. RBS. [In unconsciousness in diabetics, first glycemic change should be excluded by doing RBS].

841. A 36yo lady comes with hx of early morning stiffness of her small joints and with red and painful eye. What is the single most appropriate option?

- a. Iris
- b. Ciliary body
- c. Cornea
- d. Conjunctivitis
- e. Sclera
- f. Lichen planus

Ans. The key is E. Sclera. [Ocular manifestation of rheumatoid arthritis is scleritis (red, painful eye)].

842. A 23yo man comes with 2d hx of sticky greenish discharge from the eyes with redness. What is the single most appropriate option?

- a. Iris
- b. Ciliary body
- c. Cornea
- d. Conjunctivitis
- e. Sclera

Ans. The key is D. conjunctivitis. [Bacterial conjunctivitis can cause sticky greenish discharge].

843. A pt was admitted with erectile dysfunction, reduced facial hair and galactorrhea. What is the most probable dx?

- a. Hyperprolactinemia
- b. Cushing's syndrome
- c. Pheochromocytoma
- d. Hyperthyroidism
- e. Hypoparathyroidism

Ans. The key is A. Hyperprolactinemia.

844. A 32yo man has been repeatedly admitted to hospital for what was described as anxiety or panic attacks and palpitations. On occasions he is found to be tremulous and hypertensive. A persistent weight loss is noted. What is the most probable dx?

- a. Hyperthyroidism
- b. Panic attacks
- c. Pheochromocytoma
- d. Cushing's disease
- e. GAD

Ans. The key is C. Pheochromocytoma.

845. A 35yo man with T1DM is dehydrated with BP of 90/50mmHg. What is the single most appropriate initial inv?

- a. ABG
- b. CBC
- c. HbA1c
- d. LFT
- e. Serum Urea

Ans. The key is A. ABG. [Dehydration with low BP points towards probable DKA. So from the given options ABG is the best response].

846. In OGTT what is the glucose venous plasma level 2h after glucose intake which indicates impaired glucose tolerance?

- a. >11.1mmol/l
- b. Between 7.8-11.0mmol/l
- c. Between 8.0-10.9mmol/l
- d. Between 10.0-11.0mmol/l
- e. Between 7.1-11.0mmol/l

Ans. The key is B. Between 7.8-11.0mmol/l.

847. A young man who has no PMH presented with jaundice, low Hgb, retics 8% and other indices WNL but occasional spherocytes were seen on blood film. What is the single most appropriate inv?

- a. G6PD enzyme assay
- b. Direct coombs test
- c. Repeat blood film
- d. Indirect coombs test
- e. BMA

Ans. The key is B. Direct Coombs test. [The direct Coombs test, is used to determine whether the cause of [hemolytic anemia](#), is due to [antibodies](#) attached to RBCs which are seen in autoimmune-related hemolytic anemia].

848. A 22yo man came to the hosp after an injury in his hand while playing basketball. Exam: avulsion of extensor tendon from the distal phalanx. What is the single most probable deformity?

- a. Dinner fork deformity
- b. Game keeper thumb
- c. Mallet finger
- d. Gun-stock deformity
- e. Garden spade deformity

Ans. The key is C. Mallet finger. [A finger that bends down at the end joint and cannot be straightened is called a mallet finger. It is caused by an injury to the extensor tendon that straightens (extends) the finger. A splint worn day and night for 6-8 weeks will cure the problem in most cases].

849. A 28yo man is inv for recurrent lower back pain. A dx of AS is suspected. Which of the following inv is most useful?

- a. ESR
- b. XR sacro-iliac joints
- c. HLA B27
- d. XR thoracic spine
- e. CT lumbar spine

Ans. The key is B. XR sacro-iliac joints. [x-ray sacroiliac joint shows fusion of both SI joints and thin, symmetrical syndesmophytes bridging the intervertebral disc spaces].

850. A 4yo girl is taken by her mother to the ED and complains of feeling unwell, urinary urgency and temp=39C. What is the single next best inv?

- a. Catheter catch of urine
- b. Clean catch of urine
- c. US
- d. IVU
- e. Suprapubic catch of urine

Ans. The key is B. Clean catch of urine. [The clinical features described are consistent with urinary tract infection for which clean catch of urine is the next best investigation].

851. A 2yo girl presents with a 4d hx of fever that started with a cough. Her RR=45bpm, sat=94%, temp=38.9C, capillary refill time=1s. There are crepitations at the left base on auscultation. Urine shows negative dipstick. What is the single inv most likely to lead to dx?

- a. Blood for C&S
- b. ESR
- c. CXR
- d. Urine for C&S
- e. CSF analysis

Ans. The key is C. CXR. [The features are consistent with RTI (probable pneumonia) for which CXR is the investigation of choice].

852. A 3yo girl presents with fever for 2d. She is drowsy and had a seizure causing twitching of the right side of the body for 4mins. Her RR=30bpm, sat=90%, temp=38.9C, capillary refill time=2s. Urine negative on dipstick. What is the single inv most likely to lead to dx?

- a. Blood for C&S
- b. ESR
- c. CXR
- d. Urine for C&S
- e. CSF analysis

Ans. The key is E. CSF analysis. [It is really very difficult to differentiate between encephalitis and meningitis. Encephalitis is mostly viral and in UK herpes simplex virus is the main cause. Meningitis also has a viral predominance though less than encephalitis. Because encephalitis involves infection of the brain itself, symptoms of altered brain function--like confusion or decreased alertness--are usually present, while in cases of meningitis the patient is initially alert and, though understandably distracted by pain and misery, still in command of their mental processes. As CSF can not differentiate between meningitis and encephalitis we have to take help of imaging like MRI. In herpes simplex encephalitis there is characteristic hyperintensity in fronto-temporal region. In the given case there are features of raised intracranial pressure like drowsiness and seizure and so we cannot proceed for LP unless guided by CT (or MRI). On the other hand there is no other option that can be diagnostic of the given condition. So we have to happy with CSF analysis as the key though at this moment we have to withheld this procedure].

853. A 6m boy is admitted with persistent irritability. He is lethargic and is not feeding as well as usual. His RR=30bpm, sat=97%, temp=38.0C, capillary refill time=2s. Urine reveals leucocytes on dipstick. What is the single inv most likely to lead to dx?

- a. Blood for C&S
- b. ESR
- c. CXR
- d. Urine for C&S
- e. CSF analysis

Ans. The key is D. Urine for culture and sensitivity. [Dipstick test if show leucocytes or nitrites is suggestive of UTI. So to confirm it we should do urine C&S].

854. A 3yo boy presents with a 1d hx of being unwell. He appears shocked and has 3h old rash made up of urticarial and purpurial spots. His RR=30bpm, sat=94%, temp=39C, capillary refill time=1s. Urine is clean on dipstick. What is the single inv most likely to lead to dx?

- a. Blood for C&S
- b. ESR
- c. CXR
- d. Urine for C&S
- e. CSF analysis

Ans. The key is A. Blood for C&S. [Likely diagnosis is septicemia for which Blood culture is the investigation of choice].

855. A child is dx with VUR. What would you tell his parents?

- a. Requires antibiotic prophylaxis
- b. Most will require surgery
- c. Most will have kidney scarring by 5yo
- d. Nothing can be done
- e. Reassure

Ans. The key is B. Most will require surgery. This is wrong key! Correct key is A. Require antibiotic prophylaxis. [Practically it is established that majority of VUR will cure with time with prophylactic antibiotics and need no surgery! Only a minority needs surgery].

856. A 2yo child presents with severe vomiting. Exam: mass felt in abdomen. What inv is most appropriate?

- a. US
- b. XR
- c. CT
- d. CBC

Ans. The key is A. US. [The question is incomplete and is not suitable

for further discussion with such little info].

857. A 13yo girl complains of a 2d hx of hoarseness of voice a/w dry cough. She feels feverish. On direct laryngoscopy, her vocal cords are grossly edematous. What is the single most appropriate inv?

- a. None req
- b. Sputum for AFB
- c. Laryngoscopy
- d. Bronchoscopy
- e. XR cervical spine

Ans. The key is A. None required. [Dx is laryngitis].

858. A 7yo girl is brought by her mother with bright red staining of her underpants. She also gives a hx that her daughter recently started taking horse riding lessons. What is the single most appropriate next action?

- a. Local exam
- b. Exam under GA
- c. Continue regular child care
- d. Inform child protection services
- e. Coag profile

Ans. The key is B. Exam under GA. This is wrong key. Correct key is A. Local exam. [If child refuse local exam then exam under GA].

859. A 7d baby whose birth weight was 3.5kg and now is 3kg. What is the most appropriate next step?

- a. Check child protection register
- b. Nutritional assessment
- c. Skeletal survey
- d. Continue regular child care
- e. Inform police

Ans. The key is D. Continue regular child care. [In 1st week the baby loose some weight then start gain weight again. It is normal. So the option is continue regular child care].

860. A 6yo child fell on his nose 2d ago. His parents have now brought him with difficulty in breathing. Exam: fever, nasal bones are straight. What is the single most likely dx?

- a. Nasal polyp
- b. Septal hematoma
- c. Septal abscess
- d. Deviated nasal septum
- e. Fx nose

Ans. The key is C. Septal abscess. This is wrong key! Correct key is B. septal hematoma. [Septal abscess takes a bit more time and a considerable portion of case of septal hematoma is associated with fever].

861. A 12yo pt came to the OPD with complains of fever, malaise, weight loss, anorexia and productive cough. Exam: temp=39C, pulse=100bpm. His mother says that he has a hx of recurrent chest infections and he is not thriving well. What is the single most likely causative organism?

- a. Pneumococcal pneumonia
- b. Staphylococcus
- c. Mycobacterium TB
- d. Pseudomonas
- e. PCP

Ans. The key is D. Pseudomonas. This is wrong key! Correct key is B. Staphylococcus. [In younger age Staphylococcus and by 18 years of age, 80% of patients with classic CF harbor P. aeruginosa, and 3.5% harbor B. cepacia].

862. A 3yo child brought by his mother. Exam: bruises on the buttocks. Mother also gives hx of runny nose 2wks ago. What is the single most appropriate next action?

- a. Check child protection register
- b. Coag profile
- c. Skeletal survey
- d. Continue regular child care
- e. Inform police

Ans. The key is B. Coagulation profile. [Henoch schonlein purpura occurs mostly in the winter months. About 50-90% of patients have a preceding upper respiratory tract infection (URTI). There is a symmetrical, erythematous macular rash, especially on the back of the legs, buttocks and ulnar side of the arms. Within 24 hours, the macules evolve into purpuric lesions, which may coalesce and resemble bruises. Plasma D-dimer - May be substantially increased. PT and aPTT - May be reduced (eg, hypoprothrombinemia)].

863. A 4yo is brought to the ED by ambulance. His mother reports that he has been unwell with a sore throat for 8h. He is sitting on his mother's knee and is tolerating an oxygen mask but looks unwell. He has constant noisy breathing and he is drooling saliva. His temp=39C. What is the most imp dx?

- a. Acute asthma
- b. Bronchiolitis
- c. Croup
- d. Epiglottitis
- e. Tonsillitis

Ans. The key is D. Epiglottitis.

864. A pt with terminal cancer is being treated with chemo develops tingling and numbness of the fingertips of both arms. What is the single most likely cause of the symptoms?

- a. Bone mets to cervical vertebrae
- b. Post-chemo neuropathy
- c. Hyponatremia
- d. Hypocalcemia

Ans. The key is B. Post-chemo neuropathy.

865. An 80yo man has a permanent catheter. Catheter specimen urine found lots of e-coli. What is the single most appropriate management as he wants to attend his daughter's wedding next week?

- a. Change the catheter
- b. Prolonged antibiotics
- c. Bladder wash
- d. Repeat MSU after wedding
- e. Reassure

Ans. The key is A. Change the catheter.

866. A 35yo male typist who suffered a scaphoid fx was treated with a scaphoid cast. After 2wks when the cast was removed for a review XR, it was found that he had problems in moving the thumb, index and middle fingers. What would you suggest as the management for the recent prb?

- a. Release of flexor retinaculum
- b. Release of common flexor sheath
- c. Release of palmar sheath
- d. Ulnar nerve release
- e. Fasciotomy

Ans. The key is A. Release of flexor retinaculum. [Now case of carpal tunnel syndrome (median nerve compression)].

867. A pt on insulin is booked in for a hernia operation. What is the most appropriate management of insulin?

- a. Give insulin and saline pre-op
- b. Stop insulin for the duration of the op
- c. Give IV insulin + dextrose + saline pre-op
- d. Give insulin as usual pre-op
- e. None

Ans. The key is C. Give IV insulin + dextrose + saline pre-op.

868. A 35yo male who recently had an appendicectomy has got severe pain in his right big toe. Joint is red and swollen. He consumes 30 units of alcohol/week. What is the most probable dx?

- a. Rhabdomyosarcoma
- b. Osteoarthritis
- c. Gout
- d. Pseudogout
- e. Arthritis

Ans. The key is C. Gout. [Alcoholic drinks can raise the level of uric acid in the blood].

869. A 25yo male who recently noticed change in his shoe size, he is also constipated, has a preference to hot weather, his skin is dry, has severe pain in wrist joint. Joint is red and swollen. What is the most probable dx?

- a. Chondro-sarcoma
- b. Lipo-sarcoma
- c. Gout
- d. Pseudogout
- e. Ankylosing spondylitis

Ans. The key is D. Pseudogout. [Hypothyroidism (change of shoe size due to myxedema (or pedal oedema can be seen in hypothyroidism) , other features of constipation, cold intolerance, dry skin are well known features of hypothyroidism.) has well recognized association with pseudogout].

870. A 45yo woman had her visual acuity checked at her local optician. 12h later she presents to the ED with severe pain and redness in her eye. What is the single most appropriate option?

- a. Iris
- b. Ciliary body
- c. Ant chamber
- d. Post chamber
- e. Cornea

Ans. The key is C. [In acute angle closure glaucoma half-dilated pupil is the most likely position which precipitates an acute attack as the trabecular meshworks are mostly closed by peripheral anterior synechia of peripheral iris in this position. And mild illuminated darkened room like of an optician (also use of mydriatics accelerates this) or opera (cinema hall) are culprit to make this! As the block occurs in anterior chamber it is the likely option here].

871. A 75yo man who has DM and HTN experiences acute monocular blindness which resolves after. What is the most likely dx?

- a. GCA
- b. Optic neuritis
- c. Lacunar infarct
- d. Pontine hemorrhage
- e. Amaurosis fugax

Ans. The key is E. Amaurosis fugax.

872. A 26yo presents with prolonged constipation, blood on side of stool and very painful defecation. PR exam: very painful. What is the single most likely dx?

- a. Ca Colon
- b. UC
- c. CD
- d. Anal fissure
- e. Constipation

Ans. The key is D. Anal fissure.

873. A 35yo man with painless left testicular enlargement for the past 6m which is increasing in size and 3x larger than the right side. There is no tenderness or redness. What is the most likely dx?

- a. Testicular tumor
- b. Hydrocele
- c. Epididymal cyst
- d. Epididymo-orchitis
- e. Reassure

Ans. The key is A. Testicular tumour.

874. A middle aged man who has had a hx of chronic sinusitis, nasal obstruction and blood stained nasal discharge. He now presents with cheek swelling, epiphora, ptosis, diplopia, maxillary pain. What is the single most likely dx?

- a. Nasopharyngeal ca
- b. Pharyngeal ca
- c. Sinus squamous cell ca
- d. Squamous cell laryngeal ca
- e. Hypopharyngeal tumor

Ans. The key is C. Sinus squamous cell ca.

875. A 60yo man with a long hx of smoking and alcohol presents with nasal obstruction, epistaxis, diplopia, otalgia and conductive deafness. What is the single most likely dx?

- a. Nasopharyngeal ca
- b. Pharyngeal ca
- c. Sinus squamous cell ca
- d. Squamous cell laryngeal ca
- e. Hypopharyngeal tumor

Ans. The key is A. Nasopharyngeal ca. [Nasal obstruction, epistaxis are features of nasopharyngeal carcinoma; with cranial nerve palsy, diplopia due to 6th nerve, (also 5th and 12th cranial nerves are frequently affected) otalgia and conductive deafness from local extension as mentioned can occur].

876. A 60yo is on tx for IHD, HTN and hyperlipidemia. During the night he complains of wheeze and SOB. Which of the following meds is responsible for that?

- a. Amlodipine
- b. Atenolol
- c. Ramipril
- d. Simvastatin
- e. Bendroflumethiazide

Ans. The key is B. Atenolol. [Asthma can be precipitated by beta blockers].

877. A 15yo boy who complains of pain in his leg which has settled with aspirin. What is the most probable dx?

- a. Leomyosarcoma
- b. Liposarcoma
- c. Painful hip
- d. Exostosis
- e. Osteoid osteoma

Ans. The key is E. Osteoid osteoma. [Younger age of onset and relieved with aspirin favours the diagnosis of osteoid osteoma].

878. A 20yo fit man suddenly developed severe lower back pain as getting up from bed. What is the single most probable dx?

- a. Paget's disease
- b. Multiple myeloma
- c. PID
- d. AS
- e. Spondylosis

Ans. The key is C. PID [Prolapsed Intervertebral Disc]. [Sudden onset of lower back pain and felt more during forward bending or similar movement like getting up from bed favours the diagnosis of PID].

879. A 60yo man brought to the ED with fx hip, he is deaf and has bilateral pedal edema. What is the single most probable dx?

- a. Paget's disease
- b. Osteoporotic fx vertebra
- c. Secondary
- d. Multiple myeloma
- e. Spondylosis

Ans. The key is A. Paget's disease. [H/O deafness and evidence of heart failure like pedal edema favours the diagnosis of Paget's disease].

880. An 80yo lady presents with pain on left 6th rib for a week. It is non-tender on examination. What is your most likely dx?

- a. Herpes zoster
- b. Costochondritis
- c. Bone degeneration
- d. Thoracic vertebra compression

Ans. The key is C. Bone degeneration.

881. A 68yo DM, HTN with a 45pack/year smoking hx, has left sided chest pain increased with breathing. Exam: myosis on left side and wasting of small muscles of left hand. What is the single most appropriate dx?

- a. Costochondritis
- b. Lung cancer
- c. Good pasture's syndrome
- d. MND
- e. Progressive massive fibrosis

Ans. The key is B. Lung cancer. [Smoking history, chest sign and Horner's syndrome points towards lung cancer (probable pancoast tumour)].

882. A 34yo man had a cold 2d back. He now presents with right sided facial pain. What is the single most likely dx?

- a. Maxillary sinus
- b. Ethmoid sinus
- c. Septal hematoma
- d. Septal abscess
- e. Allergic rhinitis

Ans. The key is A. Maxillary sinus. [Maxillary sinusitis].

883. A 29yo man with hx of asthma comes with post nasal discharge and bilateral painless nasal blockage. What is the single most likely dx?

- a. Nasal polyp
- b. Septal hematoma
- c. Septal abscess
- d. Atopic rhinitis
- e. Allergic rhinitis

Ans. The key is A. Nasal polyp.

884. A 24yo man has been found unconscious in an alleyway with a RR=6bpm and HR=60bpm. His pupils are constricted. What is the best tx?

- a. Methadone
- b. Naloxone
- c. Naltrexone
- d. Thiamine
- e. Glucose

Ans. The key is B. Naloxone. [Respiratory depression and miosis points towards opiates poisoning for which antidote naloxone is given].

885. A 23yo female presents with back pain and early morning stiffness, also complaining of eye problem and her sister has a similar condition. What is the single most probable dx?

- a. Paget's disease
- b. PID
- c. Myofascial pain
- d. AS
- e. Spondylosis

Ans. The key is D. AS [Back pain with early morning stiffness and uveitis points towards the diagnosis of ankylosing spondylitis].

886. A 63yo female with a hx of osteoporosis suddenly falls on her outstretched hand while shopping. XR shows fx at distal radius with backward shift of the distal fragment. What is the single most probable deformity?

- a. Dinner fork deformity
- b. Coxavara
- c. Mallet finger
- d. Cubitus valgus
- e. Garden spade deformity

Ans. The key is A. Dinner fork deformity.

887. A 60yo man presents with severe colicky pain from his right flank radiating to his groin. His urinalysis reveals trace blood cells. What is the single most discriminatory inv?

- a. US abdomen
- b. XR KUB
- c. Colonoscopy
- d. Upper GI endoscopy
- e. Laparoscopy

Ans. The key is A. US abdomen. [Features are of ureteric colic. X-ray KUB may miss radiolucent stones so US abdomen is the discriminatory inv].

888. A 45yo man has been admitted for an elective hernia surgery. 3d later he presents with agitation, sweating, aggressiveness, and complains of seeing snakes on the hosp wall. Chlordiazepoxide has been started for this pt. What is the most appropriate next step?

- a. Diazepam
- b. Acamprosate
- c. Disulfiram
- d. Thiamine

Ans. The key is D. Thiamine. [Dx is delirium tremens. So following chlordiazepoxide thiamine is the appropriate next step].

889. A woman with a prv hx of pain at the left wrist following a fall 4m ago for which she didn't seek any tx now presented with pain in the same wrist below the thumb and the pain is aggravated whenever she holds her baby. What is the cause?

- a. Fx radial head
- b. Scaphoid fx
- c. Carpal tunnel syndrome
- d. Colles fx
- e. Ulnar fx

Ans. The key is B. Scaphoid fracture.

890. A 29yo man was involved in an RTA. He presents with distended neck veins, clear breath sounds and a trachea which is in the midline. His RR=34bpm, BP=60/0mmHg. What is the most likely dx?

- a. Simple pneumothorax
- b. Tension pneumothorax
- c. Cardiac tamponade
- d. Pericarditis

Ans. The key is C. Cardiac tamponade. [Distended neck vein, clear breath sound and no tracheal shift and BP of 60/0 points towards cardiac tamponade].

891. An elderly woman is found anemic. As part of her exam, she had a barium enema which reveals a mass lesion in the ascending colon. What is the single most appropriate dx?

- a. Sigmoid volvulus
- b. Anal fissure
- c. Sigmoid carcinoma
- d. Cecal carcinoma
- e. Diverticular disease

Ans. The key is D. Cecal carcinoma. [Mass in ascending colon and anaemia makes cecal carcinoma the likely diagnosis from the given options].

892. A 55yo male after gastrectomy developed anemia. His MCV=106fl. Exam: loss of proprioception and vibration sense. What is the most likely dx?

- a. IDA
- b. Folate def
- c. Vit B12 def
- d. Anemia of chronic disease

Ans. The key is C. Vit B12 def. [gastrectomy → deficiency of intrinsic factor → Vitamin B12 def. leading to macrocytic anemia and resulting subacute combined degeneration of cord causing loss of proprioception and loss of vibration sense].

893. A 26yo male has been operated for abdominal trauma and splenectomy was done. On the 3rd post-op day the pt developed acute abdominal pain and distention in the upper abdominal area with hypotension. On insertion of ryles tubes, 2L of coffee ground fluid was aspirated. What is the most probable dx?

- a. Acute gastric dilatation
- b. Reactionary hemorrhage
- c. Subphrenic abscess
- d. DVT
- e. Left lower lobe atelectasis

Ans. The key is A. Acute gastric dilatation. [Acute gastric dilatation may be caused by:

Hyperglycaemia, childbirth, abdominal injury, application of a spinal cast, rarely, after abdominal surgery when the stomach is in ileus and drink has been taken too soon. The abdomen is distended and tender. The patient complains of epigastric fullness, nausea, heaviness and heartburn. There is a succussion splash. The accumulation of fluid

in the stomach may induce hypovolaemic shock. Reflux of gastric contents may cause an aspiration pneumonia].

894. A 50yo man presented with increased breathlessness at rest. He is currently on furosemide, digoxin and isosorbide mononitrate. What drug is going to help him?

- a. Ramipril
- b. Bendroflumethiazide
- c. Atenolol
- d. Amlodipine
- e. Diltiazem

Ans. The key is B. Bendroflumethiazide. [This is a case of diuretic resistance. Heart failure represents the most common clinical situation in which diuretic resistance is observed. In mild CHF, diuretic resistance is not commonly encountered, as long as renal function is preserved. However, in moderate and severe CHF patients, diuretic resistance occurs more frequently and often becomes a clinical problem. In diuretic resistance another diuretic is added to get optimal or desirable result. As patient is still in heart failure and pulmonary edema with the usage of loop diuretic...a thiazide diuretic could be added with loop when response is inadequate. This will reduce the volume overload and improve breathing].

895. A 31yo man underwent an operation where his hand was hanging outside the table. After the operation he had wrist drop and sensory loss over the dorsum of his hand. Which nerve was injured?

- a. Radial
- b. Ulnar
- c. Median
- d. Axillary
- e. Brachial

Ans. The key is A. Radial. [As the man's hand was hanging outside the table there was pressure on radial nerve at arm level which is similar lesion of Saturday night palsy].

896. What is the mode of spread of chicken pox?

- a. Airborne
- b. Close contact
- c. Fecal-oral
- d. Blood
- e. Vector

Ans. The key is A. Airborne.

897. A 64yo man presents with ipsilateral vertigo, tinnitus and left side hearing loss. Exam: Renne test +ve and Weber's lateralizes to the right ear. What is the most appropriate inv?

- a. CT
- b. MRI brain
- c. XR
- d. Audiometry
- e. None
- f. Caloric testing

Ans. The key is B. MRI brain. [Rinne positive, so it is not conductive deafness. Again we know if weber lateralize to deaf ear it is conductive and lateralized away from deaf ear then it is sensoryneural. So here there is sensoryneural hearing loss in left ear. So the most appropriate investigation is MRI brain. Why not CT? As auditory involvement including acoustic neuroma is better visualized by MRI].

898. A 67yo man presents to the ED with pain in his left groin. He suddenly collapses and he is not able to move or lift his leg. He is on alendronate. What is the dx?

- a. Fx of neck of femur
- b. Post hip dislocation
- c. Fx of shaft of femur
- d. Pelvic base fx
- e. Peripheral vascular disease

Ans. The key is A. Fx neck of femur. [Use of alendronate indicates osteoporosis where fracture neck of femur is more common].

899. A young male met with an RTA and is suspected to have a femur fx. His BP is 90/60mmHg. What is the next immediate action?

- a. XR
- b. IV fluids
- c. Put leg splint
- d. Send bloods for inv
- e. US

Ans. The key is C. Put leg splint. This is a wrong key. Correct key is B. IV fluids.

900. A 70yo pt presents with cough and SOB. He stopped smoking cigarettes 2yrs ago but has a 50yr smoking hx before quitting. CXR=consolidation and bilateral hilar lymphadenopathy. What is the best inv for this pt?

- a. LN biopsy
- b. Pleural fluid cytology
- c. CT
- d. MRI
- e. US

Ans. The key is A. LN biopsy. [likely diagnosis is lung cancer, so best investigation for this is LN biopsy].

901. A 27yo pt met with a RTA. While the NGT is passing, bowel sounds are heard in the chest. CXR shows NGT curled. What is the dx?

- a. Diaphragm rupture
- b. Aortic rupture
- c. Splenic rupture
- d. Bowel rupture
- e. Liver rupture

Ans. The key is A. Diaphragmatic rupture.

902. A 62yo man dx with T2DM with BMI=33. Lifestyle modifications have failed to control blood sugar. Labs: urea=3.6mmol/l, creatinine=89mmol/l. what is the next appropriate management?

- a. Biguanide
- b. Sulfonylurea
- c. Insulin
- d. Glitazone
- e. Sulfonylurea receptor binder

Ans. The key is A. Biguanide. [Patient is obese type 2 diabetic. So biguanide is the tx of choice].

903. A pt presents with progressive dyspnea. He complains of cough, wheeze and a table spoonful of mucopurulent sputum for the last 18m. Spirometry has been done. FEV1/FVC=2.3/3.6. After taking salbutamol, the ratio=2.4/3.7. What is the most likely dx?

- a. Chronic bronchitis
- b. Asthma
- c. Bronchiectasis
- d. Lung fibrosis
- e. Sarcoidosis

Ans. The key is A. Chronic bronchitis. [Progressive dyspnoea, wheeze productive cough and the result of spirometry (prebronchodilator FEV1/FVC ratio of 64% and postbronchodilator FEV1/FVC ratio of 65%] points towards the diagnosis of chronic bronchitis. Some may

think of bronchiectasis! But in bronchiectasis there is copious purulent sputums (as cup full of sputum not table spoon full!)).

904. A 62yo man presents with cough, breathlessness and wheeze. 24% O2, salbutamol and hydrocortisone were given. The symptoms haven't improved and so nebulized bronchodilator was repeated and IV aminophylline was given. ABG: pH=7.31, RR=32. What is the next appropriate management?

- a. Nasal IPPV
- b. Intubation and ventilation
- c. LABA
- d. Toxapram
- e. Amoxicillin PO

Ans. The key is A. Nasal IPPV. [Here given case is COPD has following indications of Nasal IPPV i) Tachypnea (>24 breaths/min) and ii) Hypercapnic respiratory acidosis (pH range 7.10-7.35)].

905. A young girl returns from holidays in Spain. She complains of discharge from her ear and complains of tragal tenderness. Exam: tympanic membrane normal. Aural toilet has been done. What is the next appropriate med?

- a. Antibiotic PO
- b. Antibiotic IV
- c. Steroid PO
- d. Steroid drop
- e. Antibiotic drop with steroid

Ans. The key is E. Antibiotic drop with steroid. [Discharge from ear and tragal tenderness are features of otitis externa. Key treatment is aural toileting. Drop advised is Sofradex (Framycetin + dexamethasone) OHCS, 9th edition, page 542].

906. A 23yo man sprained his right ankle 6wks ago while playing football. He was tx with a below knee walking cast. On removal of the cast, the pt noted to have right foot drop. He has weakness of extensors of the ankle and toes and diminished pin prick sensation over the dorsum of the foot. The ankle jerk is present and plantar reflex is flexor. What is the most likely cause of the foot drop?

- a. Compression of common peroneal nerve
- b. Compression of the tibial nerve
- c. Compression of the S1 nerve root
- d. Rupture of Achilles tendon
- e. Tx of the medial collateral lig of the ankle

Ans. The key is A. Compression of common peroneal nerve. [Foot drop, weakness of extensors of the ankle and toes and diminished pin prick sensation over the dorsum is suggestive of compression of common peroneal nerve].

907. A young man was knocked down during a fight in the waiting room of the ED. He is now unconscious and unresponsive. What is the 1st thing you would do?

- a. Turn pt and put in recovery position
- b. Put airway
- c. Endotracheal intubation
- d. Assess GCS
- e. Start CPR

Ans. The key is B. Put airway. [ABC protocol].

908. A 52yo man underwent a hemicolectomy. After a few days he complains of left ventricular pain and fever. ECHO has been done and shows a systolic murmur. What is the next appropriate inv?

- a. CT
- b. US
- c. CXR
- d. Blood culture
- e. LFT

Ans. The key is D. Blood culture. [Dx a case of infective endocarditis. Therefore the next appropriate investigation is blood culture].

909. A 19yo man has exercised induced asthma and is using a salbutamol inhaler as req and beclamethasone 400ug BD. He complains that he has to wake up at night for his inhaler. What is the single most appropriate tx?

- a. Beclo
- b. Regular salbutamol and budesonide
- c. Sodium cromoglycate
- d. Oral steroid
- e. Inhaled steroid

Ans. The key is C. Sodium cromoglycate. [According to protocol next step is addition of LABA (Long Acting Beta2 Agonist). And if it fails then Sodium chromoglycate. This is an inappropriate question or bad recall!].

910. Pt with a long hx of smoking is now suffering from bronchial ca. histology reveals there are sheets of large polygonal or giant MNC. What is the most likely dx?

- a. Squamous cell ca
- b. Small cell ca
- c. Adenocarcinoma
- d. Large cell ca
- e. Oat cell ca

Ans. No key is given!! Correct answer is D. Large cell ca. [Large cell

carcinoma is, by definition, a poorly differentiated malignant epithelial tumor. It consists of sheets or nests of large polygonal or giant multinuclear cells and probably represents SCC.".]

911. A 27yo man presents with chest pain and respiratory distress. Exam: tachycardia, hypotension and neck vein distension. Trachea is deviated to the left side, breathing sounds on right side are absent and diminished on left side. What is the next appropriate management?

- a. CXR
- b. Right side aspiration (16G)
- c. Left side aspiration (16G)
- d. Right side drain with a small tube (12F)
- e. Left side drain with a small tube (12F)

Ans. The key is B. Right side aspiration (16G). This is a wrong key. Correct key is D. d. Right side drain with a small tube (12F). [Life threatening pneumothorax with hemodynamic instability = immediate tube thoracostomy].

//emedicine.medscape.com/article/424547-treatment#d7

Welcome to Facebook
Bookmarks

Patient presentation

The following are possible presentations of patients with pneumothorax:

- Asymptomatic (incidental finding) - Treatment decisions are guided by estimate of long-term recurrence risk.
- Symptomatic but clinically stable - Treatment is guided by local resources and conventions for the site of care; the British Thoracic Society (BTS) advocates for simple aspiration and deferring hospitalization in primary spontaneous pneumothorax (PSP) as initial management if the patient is stable^[56]; a small-bore catheter or chest tube placement is recommended by the American College of Chest Physicians (ACCP) Delphi consensus statement^[39]
- Clinically fragile - Treatment is guided by local practice patterns for air evacuation and observation; comorbid conditions may preclude observation because of decreased cardiopulmonary reserve
- Life-threatening - Pneumothorax that causes hemodynamic instability is life-threatening and must be treated immediately with tube thoracostomy; all documents and recommendations call for intervention if a patient is unstable

912. A 16wk pregnant pt who was exposed to a child with chicken pox came to GP for help. She wastested -ve for varicella antibody. What is the next most imp step in management?

- a. Reassurance
- b. Ig
- c. Ig + vaccine
- d. Vaccine only
- e. Acyclovir

Ans. The key is B. Ig. [If you are pregnant, come contact with chicken pox case, found antibody negative on blood test you have to take injection Ig. Ref: patient.info].

913. A 68yo woman dx with T2DM and BMI=33. Lab: GFR=29, urea=13, creatinine=390mmol/L. what is the next appropriate management?

- a. Biguanide
- b. Sulfonylurea
- c. Insulin
- d. Glitazone
- e. Sulfonylurea receptor binder

Ans. The key is C. insulin. [Insulin is devoid of significant side effect than Glitazones (like fluid retention). In renal failure there is reduced GFR and some fluid retention. It is not desirable that glitazone to cause more fluid retention by causing oedema. The oral agents that are thought to be relatively safe in patients with nondialysis CKD include short-acting sulfonylureas (eg, glipizide) and repaglinide. If an oral agent is used, the short-acting sulfonylurea, glipizide, is the preferred agent among nondialysis CKD patients who have an estimated glomerular filtration rate (eGFR) <30 mL/min/1.73. The dose for glipizide is 2.5 to 10 mg/day. Glyburide and other long-acting sulfonylureas are generally not recommended in any CKD patient with type 2 diabetes, because of the risk of hypoglycemia. Some clinicians recommend the use of the meglitinide repaglinide (starting with a dose of 0.5 mg) for nondialysis CKD patients since these agents are not renally cleared. Nondialysis CKD patients with type 2 diabetes may be treated with an oral agent, although many patients end up on insulin therapy because it is more effective. So it may be that we can go for insulin as the answer!!].

914. A 5yo boy was brought to GP with high temp and many vesicles on his back. What is the most appropriate management?

- a. Topic acyclovir
- b. Oral acyclovir
- c. Oral antibiotics
- d. Topical steroids
- e. None

Ans. The key is E. None. [A case of chickenpox. None of the given treatment is used in chickenpox. Symptomatic treatment like, acetaminophen if fever, antihistamine and calamine lotions are given].

915. A woman came with the complaint of pain in her right arm when she abducts it. She has recently moved to a new house. There is no hx of trauma. What is the likely cause of her pain?

- a. Rupture of the long head of biceps
- b. Sprain of the acromio-clavicular ligament
- c. Tendinitis of the abductor sheath
- d. Supraspinatus tendinitis
- e. Shoulder dislocation

Ans. The key is D. Supraspinatus tendinitis. [Tendinitis and partial

tears in the supraspinatus tendon causes a 'painful arc' since as the person elevates his arm sideways, the tendon begins to impinge under the acromion through the middle part of the arc, and this is usually relieved as the arm reaches 180 degrees (vertical)].

916. An 83yo man with longstanding COPD has become progressively breathless over the last 2yrs. He is on salbutamol, ipratropium, salmeterol, beclomethasone and theophylline. His FEV1<30%. What is the next appropriate management?

- a. Lung transplant
- b. Trial of CPAP
- c. Trial of non-invasive ventilation
- d. Assessment for long term O2 therapy
- e. Short course of O2 therapy

Ans. The key is D. Assessment for long term O2 therapy. [Patient is progressively breathless with present FEV1 of <30%. So his respiratory deterioration indicates progressive respiratory failure for which he should be assessed for long term O2 therapy. Long-term oxygen therapy (LTOT) for more than 15 h/day improved mortality and morbidity in a well-defined group of patients with chronic obstructive pulmonary disease. Requirement of condition to proceed to LTOT is patient should be stable and on appropriate optimum therapy (as in given case) and having stopped smoking tobacco. Patient should be shown to have a PaO2 less than 7.3 kPa and/or a PaCO2 greater than 6 kPa on two occasions at least 3 weeks apart. FEV1 should be less than 1.5 litres, and there should be a less than 15% improvement in FEV1 after bronchodilators. Patients with a PaO2 between 7.3 and 8 kPa who have polycythaemia, right heart failure or pulmonary hypertension may gain benefit from LTOT].

917. A 49yo man complains of fullness in his left ear, recurrent vomiting and tinnitus. What is the most appropriate med?

- a. Buccal prochlorperazine
- b. Oral chlorpheniramine
- c. Oral fluphenazine
- d. Buccal midazolam
- e. IV rantidine

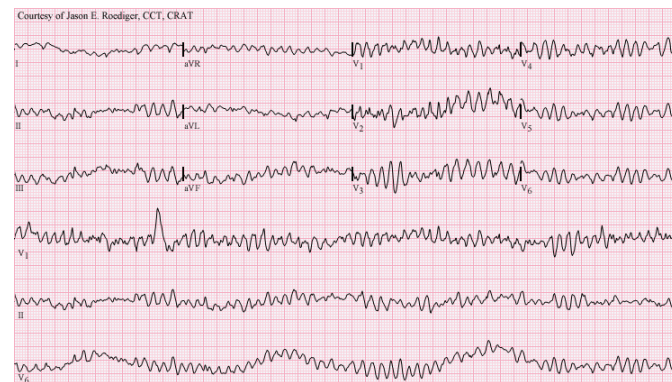Ans. The key is A. Buccal prochlorperazine. [Meniere's disease Dilatation of the endolymphatic spaces of the membranous labyrinth causes vertigo for ~12h with prostration, nausea/vomiting, a feeling of fullness in the ear; uni- or bilateral tinnitus, sensorineural deafness (eg fluctuating). Attacks occur in clusters (<20/month). Cause: A mystery! Electrocochleography; endolymphatic space MRI. Prochlorperazine as BuccastemR 3mg/8h PO (1st-line if vomiting) or betahistine 16mg/8h PO or chlorthalidone may help. Ref: OHCS, 9th edition, page 554].

918. A man had a soft mass on his mandible. Mass is freely mobile and has started growing progressively over the past 6m. The mass still moves freely. What is the best inv for this pt?

- a. FNAC
- b. CT
- c. XR
- d. MRI
- e. ESR

Ans. The key is A. FNAC.

919. A 63yo man has been brought to the hosp after collapsing during a wedding. His ECG is below. What is the most likely dx?



- a. VT
- b. A-fib
- c. VF
- d. A-flutter
- e. SVT

Ans. The key is C. VF. [QRS complex is chaotic, wide, bizarre and irregular which is characteristic of ventricular fibrillation].

920. A 75yo war veteran complains of loss of appetite and says he has lost weight over the past few months. He says that he has passed some blood in his urine, however, he had no pain. A recent report shows that PSA >5.5ng/ml. how will you manage this pt?

- a. Radical prostatectomy
- b. TURP
- c. Cryosurgery
- d. Brachytherapy
- e. Irradiation

Ans. The key is A. Radical prostatectomy. This answer is controversial.

[Though PSA is a bit higher than normal it is not confirmatory of carcinoma! But loss of appetite and weight loss are highly suggestive of cancer in this 75yrs old man. Active Surveillance is offered first for Low Gleason score. esp at age of 75. and any other treatment depending on extension of tumor will be offered after excluding mets].

921. A 19yo boy comes to the ED with pain, swelling and tenderness 2cm distal to Lister's tubercle of radius. Exam: proximal pressure on the extended thumb and index finger is painful. XR: no fx. What is the next appropriate management for the pt?

- a. Immobilization with cast
- b. Repeat XR
- c. MRI
- d. Surgery
- e. None

Ans. The key is A. Immobilization with cast. This is wrong key! Correct key is C. MRI. [Imaging: Request a dedicated 'scaphoid' series. If -ve, and fracture is suspected MRI has been shown to be sensitive and cost-effective. CT is an alternative. If neither is available, cast and re-x-ray in 2 weeks. Ref: OHCS, 9th edition, page-744].

922. A 71yo man with a hx of 50yrs of smoking presents with cough, hemoptysis, dyspnea and chest pain. He also has anorexia and weight loss. The dx of lung cancer has been stabilized. Which electrolyte abnormality can be seen?

- a. Hyperkalemia
- b. Hypocalcemia
- c. Hyponatremia
- d. Hypernatremia
- e. Hypomagnesemia

Ans. The key is C. Hyponatremia. [Likely diagnosis is squamous cell lung cancer (as the patient is smoker) causing SIADH and resulting hyponatremia].

923. A 56yo man who is hypertensive recently underwent a change in meds. 2days later he developed wheezing. Which drug can cause this?

- a. Atenolol
- b. Ramipril
- c. Bendroflumethiazide
- d. Verapamil
- e. Furosemide

Ans. The key is A. Atenolol. [Beta blockers can precipitate asthma attacks].

924. A 33yo man has a temp=38.5C, cough and chest pain on the right side on inspiration. He also has purulent sputum. What is the most likely organism to cause pneumonia in this pt?

- a. Gram +ve diplococcic
- b. Coagulase +ve cocci
- c. PCP cold agglutinins
- d. AFB
- e. Gram -ve diplococcic

Ans. The key is C. PCP cold agglutinins. It is wrong key! Correct key should be A. Gram +ve diplococci. [It is a case of community acquired pneumonia caused by streptococcus pneumoniae].

925. A young man's arm was caught in a machine. XR showed no fx but arm is very swollen. What is the best tx?

- a. Plaster cast
- b. Wide splint with upward position
- c. Analgesics
- d. Antibiotics
- e. Tetanus prophylaxis

Ans. The key is B. Wide splint with upward position. [If the limb is kept hanging it will aggravate the swelling as fluid shifts to dependant part. Here wide splint with upward position will help the accumulated blood or fluid to move down and will improve the swelling].

926. A child was brought in to ED by his parents for taking his granddad's meds. There is an extra systole in the ECG. Which drug was taken?

- a. Digoxin
- b. Amitryptiline
- c. Atenolol
- d. Ramipril
- e. Bendroflumethiazide

Ans. The key is A. Digoxin. [Both digoxin and amitryptiline can cause extrasystole].

927. A 5yo child came from Ghana 6wks ago. 2d ago he developed fever, vomiting and neck stiffness. He had taken malaria prophylaxis and had no rash. What is the dx?

- a. Cerebral abscess
- b. Cerebral malaria
- c. Meningococcal meningitis
- d. SAH
- e. Cerebral tumor
- f. Pneumonia

Ans. The key is B. Cerebral malaria. [Incubation period of malaria is 7 – 30 days. Malaria prophylaxis cannot give confirmed protection and there is often failure of prophylaxis. Fever, vomiting, neck stiffness are consistent with cerebral malaria].

928. A HTN pt on bendroflumethiazide 2.5mg/d has come for his routine checkup. Exam: BP=145/85mmHg. Lab: K+=5.9, Na+=137. What is the most appropriate management for this pt?

- a. Stop meds
- b. Continue same dose
- c. Increase the dose
- d. Decrease the dose
- e. Repeat the blood test

Ans. The key is E. Repeat the blood test. [Bendroflumethiazide causes hyponatremia and hypokalemia. But the findings are opposite which is probably error of test. Hence blood test should be repeated to confirm the level of potassium and sodium].

929. A 65yo man presents with significant weight loss and complains of cough, SOB and chest pain. Exam: left pupil constricted, drooping of left eyelid. What is the most likely dx?

- a. Pancoast tumor
- b. Thoracic outlet syndrome
- c. Cervical rib
- d. Pneumonia
- e. Bronchogenic ca

Ans. The key is A. Pancoast tumor. [Pancoast tumour is the apical lung cancer that is associated with destructive lesions of the thoracic inlet and involvement of the brachial plexus and cervical sympathetic nerves (the stellate ganglion) leading to horner's syndrome].

930. A 4yo boy presents with fever, sore throat and lymphadenopathy. The dx of tonsillitis has been made. He had 3 episodes last yr. What is the most appropriate management for this pt?

- a. Tonsillectomy
- b. Paracetamol/ibuprofen
- c. Oral penicillin V
- d. IV penicillin
- e. None

Ans. The key is B. Paracetamol/ibuprofen. This is wrong key! Correct key is C. Oral penicillin V. [One of the indications of antibiotics is presence of three or more centor criteria and as the patient fulfilled three centor criteria he should be given antibiotics. patient has the following three centor criteria: 1. history of fever 2. lymphadenopathy and 3. absence of cough.

Management of tonsillitis according to NICE guidelines are as follows:

- Antipyretic analgesics such as paracetamol and ibuprofen are of value.

- For most patients, antibiotics have little effect on the duration of the condition or the severity of symptoms. The National Institute for Health and Care Excellence (NICE) suggests that indications for antibiotics include:[1]

Features of marked systemic upset secondary to the acute sore throat.

Unilateral peritonsillitis.

A history of rheumatic fever.

An increased risk from acute infection (such as a child with diabetes mellitus or immunodeficiency).

Acute tonsillitis with three or more of the following Centor criteria present:

History of fever

Tonsillar exudates

No cough

Tender anterior cervical lymphadenopathy. [Source: patient.info].

Indications for tonsillectomy:

- The child has five or more episodes of acute sore throat per year, documented by the parent or clinician.

- Symptoms have been occurring for at least a year.

- The episodes of sore throat have been severe enough to disrupt the child's normal behaviour or day-to-day functioning.

931. A pt had passed a 4mm stone in his urine. He has a 3mm stone in the renal pelvis found on US. What is the management?

- a. ESWL
- b. None
- c. Dormier basket
- d. Surgery
- e. PCNL

Ans. The key is B. None.

[Stones less than 5 mm in diameter pass spontaneously in up to 80% of people.

Stones between 5 mm and 10 mm in diameter pass spontaneously in about 50% of people.

Stones larger than 1 cm in diameter usually require intervention (urgent intervention is required if complete obstruction or infection is present).

Two thirds of stones that pass spontaneously will do so within four weeks of onset of symptoms]. Ref: patient.info

932. A 4yo boy presents with fever, severe ear ache, vomiting and anorexia. He also has mod tonsillitis. Exam: tympanic membrane bulging. He came to the GP a few days ago and was dx with URTI. What is the most appropriate dx?

- a. OE
- b. Acute OM
- c. Serous otitis
- d. Chronic suppurative OM
- e. Mastoiditis

Ans. The key is B. Acute OM. [High fever, severe earache, vomiting, bulging tympanic membrane and H/O associated URTI is highly suggestive of acute OM].

933. A 3yo girl presents with complains of sudden right facial weakness and numbness and pain around her ear. There are no symptoms. What is the most appropriate dx?

- a. SAH
- b. Bell's palsy
- c. Stroke
- d. TIA
- e. Subdural hemorrhage

Ans. The key is B. Bell's palsy.

934. A 6yo boy fell in the playground and has been holding his forearm complaining of pain. Exam: no sign of deformity or swelling. However, there is minimal tenderness on exam. What is the dx?

- a. Fx mid radius
- b. Fx mid ulnar
- c. Fx neck of humerus
- d. Fx shaft of humerus
- e. Green stick fx of distal radius

Ans. The key is E. Green stick fx of distal radius.

935. A 62yo man has been smoking about 15 cigarettes/day for 45yrs, and has been working as a builder since he was 24yo. He presents with chest pain, SOB, weight loss. CXR shows bilateral fibrosis and left side pleural effusion. What is the best inv that will lead to dx?

- a. CXR
- b. Pleural fluid aspiration of cytology
- c. MRI
- d. Pleural biopsy
- e. CT

Ans. The key is D. Pleural biopsy. [There is asbestos exposure in builders and associated smoking greatly increases the possibility of developing mesothelioma and the given presentations are typical of mesothelioma. Best investigation is pleural biopsy].

936. During a basketball match, one of the players suddenly collapsed to the ground with coughing and SOB. What is the inv of choice?

- a. CXR
- b. CT
- c. MRI
- d. V/Q scan
- e. CTPA

Ans. The key is A. CXR. [Likely diagnosis is pneumothorax. So investigation of choice is CXR].

937. A 57yo man having HTN on oral anti-HTN. However, he is finding it difficult to mobilize as he feels dizzy whenever he tries to get up. What is the most appropriate inv for him?

- a. Ambulatory BP
- b. ECG
- c. MRI
- d. CXR
- e. CT

Ans. The key is A. Ambulatory BP. [Ambulatory BP to document low BP as cause of presenting symptom. The case seems to be of postural hypotension and low BP as a result of given anti hypertensive].

938. A 33yo female complains of diplopia on upright gaze. Exam: ptosis can be seen. There are no other complains or any significant PMH. What is the most appropriate inv for him?

- a. Ophthalmoscopy
- b. Visual field test
- c. TFT
- d. CT
- e. Checking red reflex

Ans. The key is E. Checking red reflex. This is a wrong key. Right key should be D. CT. [A case of 3rd nerve palsy. So to delineate the cause CT should be done].

939. A tall rugby player was hit in the chest by a player of the opponent team. He developed breathlessness and his face went blue and purple. You have been called to look at him, how will you manage him?

- a. Insert a needle in the 2nd ICS in the mid-clavicular line
- b. Insert a needle in the 5th ICS in the mid-axillary line
- c. Intubate the pt
- d. Start CPR
- e. Give oxygen

Ans. The key is E. give oxygen. [1. The patient went blue and purple!! It is due to catch up of breath and it is not cyanosis of pneumothorax as cyanosis of pneumothorax takes time to develop and considered as a late feature. Immediate feature is chest pain, tachycardia, tachypnea etc.

There are no immediate feature mentioned according to which we can say pneumothorax is the diagnosis.

Collapse in sport's trauma treatment is ABC.

Even if pneumothorax as treatment modality 1st comes oxygen.

patient.info/doctor/pneumothorax-pro

P+ Clinical Reference Related Content Forums

Tension pneumothorax

Tension pneumothorax is a life-threatening emergency that requires instant action. Severe symptoms and signs of respiratory distress suggest the presence of tension pneumothorax [1].

- Treatment is with oxygen and emergency needle decompression.
- Insert a large-bore needle into the pleural space through the second or third anterior intercostal space. A gush of air confirms the diagnosis. A standard cannula may be insufficiently long if used in the second intercostal space.

First oxygen mask is put and it takes few seconds!! Why oxygen? It helps absorb air from pleural space (nitrogen) and speeds up the absorption of air 4 times as room air. Then make the diagnosis on clinical ground and proceed for needle aspiration.

940. A young woman fell and hit her knee. Exam: valgus test +ve. What ligament was most probably injured?

- a. Ant cruciate
- b. Medial collateral
- c. Lateral collateral
- d. Post cruciate
- e. Meniscus

Ans. The key is B. Medial collateral. [The valgus stress test involves

placing the leg into extension, with one hand placed as a pivot on the knee. With the other hand placed upon the foot applying an abducting force, an attempt is then made to force the leg at the knee into valgus. If the knee is seen to open up on the medial side, this is indicative of medial collateral ligament damage].

941. A 75yo man comes in complaining of difficulty in passing urine, poor stream and dribbling at the end of voiding and anorexia. US shows bilateral hydronephrosis. What is the cause of these findings?

- a. BPH
- b. Renal stones
- c. Bladder stones
- d. Prostatic ca
- e. UTI

Ans. The key is D. Prostatic ca. [Elderly patient of 75yrs with obstructive symptoms of lower urinary tract, bilateral hydronephrosis all can occur in BPH or ca prostate. Anorexia is clincher here. It is a feature of carcinoma rather than BPH].

942. 2h after an appendectomy, a pt complains of a rapid HR and fever. He says there is also abdominal pain and pain in the shoulder area. What is happening to this pt?

- a. Intra-abdominal bleeding
- b. Anastomotic leak
- c. Sepsis
- d. Intestinal obstruction

Ans. The key is A. Intra-abdominal bleeding.

943. A 50yo man presents with the complaints of recurrent UTI and occasional blood in the urine. Some unusual cells have been seen in urine on routine exam. Which of the following inv would you like to carry out now?

- a. Cystoscopy
- b. Urine C&S
- c. XR KUB
- d. US
- e. CBC

Ans. The key is D. US. It is wrong key! Correct key is A. Cystoscopy. [Likely diagnosis is bladder cancer. Occasional blood in urine and unusual cells (suggestive of malignant cells) suggests the diagnosis. It is also true that in bladder cancer there occurs frequent uti like symptoms].

944. A 28yo drug user presents to ED collapsed and anuria. His serum K+=7.5mmol/l. CXR shows early pulmonary edema. What is the next appropriate management for this pt?

- a. Urgent hemodialysis
- b. IV calcium gluconate
- c. IV insulin + dextrose
- d. Furosemide
- e. IV 0.9% NS

Ans. The key is B. IV calcium gluconate. [In severe hyperkalemia IV calcium gluconate is given to protect the heart from cardiac arrest or life-threatening arrhythmias till definitive treatments are arranged].

945. DM man feels hot, painful lump near the anal region. What is the most probable dx?

- a. Anal fissure
- b. Abscess
- c. Hematoma
- d. Wart
- e. External hemorrhoids

Ans. The key is B. Abscess. [DM patients are much prone to infection].

946. A 65yo lady with T1DM for the last 20y comes with a tender lump near the anal opening. She says she also has a fever. What tx should she get?

- a. I&D + antibiotics
- b. IV antibiotics
- c. C&S of aspirate from swelling
- d. Painkillers
- e. Cautery of swelling

Ans. The key is A. I&D + antibiotics. [D/D 1. Perianal abscess 2. Perianal hematoma 3. Thrombosed piles. As infection is common in DM likely case is perianal abscess].

947. An 80yo DM lady presents with redness and swelling over her right foot. It is tender to touch, warm and glossy. What are the complications this pt might develop?

- a. Meningitis
- b. Sepsis
- c. Ulcer
- d. Gangrene

Ans. The key is D. Gangrene. [This is cellulitis which may progress to gangrene in a diabetic].

948. After surgery a pt's left leg has become swollen and tender. The diameter of the calf has increased and passive movements cause pain. What is the most probable dx?

- a. DVT
- b. Lymphedema
- c. Peripheral vascular disease
- d. Hematoma
- e. Superficial thrombophlebitis

Ans. The key is A. DVT. [Swelling, tenderness and enlarged calf diameter are features of DVT supported by positive Homan's test (pain on passive movement)].

949. 2h after an appendectomy, a pt complains of a rapid HR and fever. He says there is also abdominal pain and pain in the shoulder area. What is the first step in the management?

- a. Maintain IV access and give IV fluids
- b. Start IV antibiotics
- c. Insert NGT for intestinal decompression
- d. Cross match blood
- e. Emergency exploratory laparotomy

Ans. The key is A. Maintain IV access and give IV fluids. [Probable leakage from stump. FIRST STEP is maintain IV access and give IV fluid].

950. A pregnant woman presents with knee pain on movements. The pain becomes worse at the end of the day. Radiology shows decreased joint space. Labs: CRP=12. What is the 1st line med?

- a. Paracetamol
- b. NSAIDs
- c. Oral steroid
- d. Intra articular steroid
- e. DMARDs

Ans. The key is A. Paracetamol. [Pain on movement, pain worse at end of day and decreased joint space are characteristic of osteoarthritis supported by no significant raise in inflammatory marker (CRP=12). 1st line medicine is paracetamol].

951. A 68yo man presents with muscle weakness. He is not able to climb stairs. He also complains of mild breathlessness. He says that he sometimes feels difficulty in swallowing food. Labs: ALP=216, AST=49, ALT=43, CK=417, ESR=16. What is the most likely dx?

- a. Polymyositis
- b. Polymyalgia rheumatic
- c. Muscular dystrophy
- d. Esophageal carcinoma
- e. Osteoarthritis

Ans. The key is A. Polymyositis. [Proximal myopathy (not able to climb stairs), mild breathlessness (involvement of thoracic muscles or interstitial lung disease), dysphagia due to involvement of the oropharyngeal striated muscles and upper oesophagus) and raised CK suggests the diagnosis of Polymyositis].

952. A 67yo builder presents with a persistent nodular lesion on upper part of pinna with some telangiectasia around the lesion. What is the dx?

- a. Basal cell
- b. Squamous cell
- c. Keratocanthoma
- d. Actinic keratosis
- e. Bowens disease

Ans. The key is A. Basal cell **ca.** [Any ulcer which is located above the neck is always basal cell carcinoma until proven otherwise. Source: SAMSON notes].

953. A 68yo pt wakes up with slurred speech and right sided weakness. CT shows cerebral infarct. What is the most appropriate tx?

- a. Aspirin
- b. Alteplase
- c. Warfarin
- d. Clopidogrel
- e. Dipyridamole

Ans. The key is B. Alteplase. It is a wrong key! The correct key is A. Aspirin. [The window period to administer alteplase is 4.5 hours. If we cannot certain (here patient was in sleep, so time period is not possible to establish) this period we cannot proceed for alteplase].

954. A 73yo man who is recovering from surgery on the left carotid artery in his neck. He has slurred speech. On protrusion of his tongue, the tip deviated to the left. What is the single most appropriate option?

- a. Accessory nerve
- b. Facial nerve
- c. Glossopharyngeal nerve
- d. Hypoglossal nerve
- e. Vagus nerve

Ans. The key is D. Hypoglossal nerve. [Testing function of the nerve is performed by asked the subject to stick their tongue straight out. If there is a loss of innervation to one side, the tongue will curve toward the affected side, due to unopposed action of the opposite genioglossus muscle. If this is the result of a lower motor neuron lesion, the tongue will be curved toward the damaged side, combined with the presence of fasciculations or atrophy. However, if the deficit is caused by an upper motor neuron lesion, the tongue will be curved away from the side of the cortical damage, without the presence of fasciculations or atrophy].

955. A 24yo woman known to be suffering from panic disorder presents to the hospital with tingling and numbness in her fingers. ABG: pH=7.52, PCO2=2.2kPa, PO2=11kPa, Bicarb=20. What is the most likely condition?

- a. Acute metabolic alkalosis
- b. Acute resp alkalosis
- c. Compensated resp alkalosis
- d. Compensated metabolic acidosis
- e. Acute metabolic acidosis

Ans. The key is B. Acute respiratory alkalosis. [In panic attack there occurs hyperventilation which causes washout of CO2 and leads to acute respiratory alkalosis resulting in raised pH >7.45 (here 7.52), low PCO2 (here 2.2 kPa) with compensatory decrease in HCO3 (here 20meq/l)].

956. A 65yo man on dexamethasone underwent surgery. During and after the surgery, his blood glucose was around 17-19mmol/l. What will you give the pt?

- a. Insulin
- b. Oral hypoglycemic
- c. Remove dexamethasone
- d. IV Saline
- e. IX dextrose

Ans. The key is D. IV saline. [It is estimated that adults secrete 75-

150mg of cortisol in response to major surgery and 50mg a day for minor surgery, and secretion parallels duration and extent of surgery

Patients undergoing a surgical procedure or responding to stress, trauma, or an acute illness will exhibit an increase in adrenal cortisol production up to 6-fold normal levels. However, in patients on chronic exogenous steroid therapy, atrophy of the hypothalamic-pituitary-adrenal (HPA) axis may occur through feedback inhibition, leading to an inability to respond to stress. It has historically been believed that patients receiving long-term corticosteroids require supplemental, perioperative doses, and that failure to provide such coverage in secondary adrenal insufficiency may lead to an adrenal crisis characterized by hypotension and cardiovascular collapse.

*** So who are telling remove dexamethasone are wrong!!!***

patients receiving "physiologic replacement" doses (<10 mg/ day) do not need additional steroids perioperatively beyond their standard regimen. Patients receiving doses exceeding the normal expected stress response for their surgery (>150 mg/ day of hydrocortisone equivalent for moderate/major surgery, or >50 mg/ day of hydrocortisone equivalent for minor surgery) also do not need additional coverage beyond their current therapy, because acute immunosuppressive doses are more than sufficient to maintain cardiovascular stability during the operation.

Regular daily dose of more than 10 mg prednisolone within the last three months:

Minor surgery:	25 mg hydrocortisone at induction
Moderate surgery (Hysterectomy)	Usual pre-operative steroids + 25 mg hydrocortisone at induction
+ 100 mg hydrocortisone/day	
Major surgery	Usual pre-operative steroids
Major trauma, prolonged surgery	+ 25 mg hydrocortisone at induction
	+ 100 mg hydrocortisone/day for 2 – 3 days

Surgical patients commonly develop hyperglycemia related to the hypermetabolic stress response, which increases glucose production and causes insulin resistance. Although hyperglycemia is associated with worse outcomes, the treatment of hyperglycemia with insulin infusions has not provided consistent benefits. Despite early results, which suggested decreased mortality and other advantages of "tight" glucose control, later investigations found no benefit or increased mortality when hyperglycemia was aggressively treated with insulin. Because of these conflicting data, the optimal glucose concentration to improve outcomes in critically ill patients is unknown. There is agreement, however, that hypoglycemia is an undesirable complication of intensive insulin therapy and should be avoided.

So, "FOR PERIOPERATIVE HYPERGLYCEMIA NO NEED OF INSULIN" just IV saline!!!].

957. A 61yo man who had stroke 2y ago is on aspirin. He has RA but suffers from pain and can't tolerate it. He is taking senna for constipation. What is the best med to relieve his pain?

- a. DMARDs
- b. Ibuprofen
- c. Co-codamol
- d. Paracetamol

Ans. The key is B. Ibuprofen. [DMARDs are not painkillers but prevents disease progression in long term. Paracetamol is not enough to control severe pain. Co-codamol will cause constipation. Patient is already taking laxative! So Co-codamol is not the option. Excluding other Ibuprofen seems to be the best option].

958. A young child was brought by his mother to the OPD complaining that he raised the vol of the TV and didn't respond to her when she called him. Exam: tympanic membrane was dull greyish and no shadow of handle of malleus. What is the most probable dx?

- a. Chronic OM
- b. Acute OM
- c. Secretory OM
- d. Otitis externa
- e. Cholesteatoma

Ans. The key is C. Secretory OM.

959. A 48yo woman always socially withdrawn has stopped going out of the house. She is afraid to socialize because she fears that people will criticize her. What is the most probable dx?

- a. Agoraphobia
- b. PTSD
- c. Social anxiety
- d. OCD
- e. GAD

Ans. The key is C. Social anxiety. [Social anxiety disorder is a type of complex phobia. This type of phobia has a disruptive or disabling impact on a person's life. It can severely affect a person's confidence and self-esteem, interfere with relationships and impair performance at work or school].

960. Post gastric ulcer got perforated leading to bleeding involving the gastro-duodenal artery. Where would fluid accumulate in the cavity?

- a. Left paracolic gutter
- b. Pelvic cavity
- c. First part of duodenum
- d. Under the diaphragm
- e. Retroperitoneal

Ans. The key is D. Under the diaphragm.

961. A 4yo boy presents with recurrent episodes of self limiting spontaneous bleeding. Coag test: PT normal, bleeding time normal, APTT prolonged, Factor VIII decreased. His father and uncle suffer from a similar illness. What is the most likely dx?

- a. Hemophilia A
- b. Hemophilia B
- c. Von willebrand's disease
- d. ITP
- e. TTP

Ans. The key is A. Hemophilia A. [Prolonged APTT and decreased factor VIII points towards the diagnosis of Hemophilia A].

962. A 53yo lady presents with hot flash and night sweats. Her LMP was last year. She had MI recently. What is the most appropriate management for her?

- a. Raloxifene
- b. Estrogen
- c. COCP
- d. Evening primrose
- e. Clonidine

Ans. The key is C. COCP. This is wrong key! Correct key is E. Clonidine. [COCP is absolutely contraindicated in recent MI patients].

963. A 73yo man who was a smoker has quit smoking for the past 3yrs. He now presents with hoarseness of voice and cough since past 3wks. XR: mass is visible in the mediastinum. What is the best inv to confirm the dx?

- a. Bronchoscopy
- b. Thoracoscopy
- c. US
- d. CT thorax
- e. LN biopsy

Ans. The key is E. LN biopsy.

964. A 52yo man known DM presents to ED with sudden onset of pain in the left loin and hematuria. Inv: 8mm stone in left lower ureter. Nifedipine with steroids was prescribed as initial tx with supportive therapy. He returned complaining of worsening pain, vomiting with passing of 2 stones. Renal function tests indicate impending ARF. How will you manage this pt?

- a. Continue same tx
- b. Start alpha blocker
- c. ESWL
- d. Percutaneous nephrolithotomy
- e. Percutaneous nephrostomy
- f. Open surgery

Ans. The key is E. Percutaneous nephrostomy. [Percutaneous nephrostomy, or nephropylotomy, is an interventional procedure that is used mainly in the decompression of the renal collecting system. Percutaneous nephrostomy catheter placement has been the primary option for the temporary drainage of an obstructed collecting system. Here impending ARF indicates obstructive uropathy].

965. A lady who is alcohol dependent wants to quit but wants someone to encourage her. What would you do?

- a. Medication
- b. Refer to social services
- c. Refer to psychology
- d. CBT

Ans. The key is B. Refer to social services.

966. A young girl presented to OBGYN assessment unit with lower abdominal pain and per vaginal bleeding after a hx of hysterosalpingograph as a part of her infertility tx. Observation: BP=90/50mmHg, pulse=120bpm, exam revealed rigid abdomen. What is the most appropriate next inv?

- a. CT
- b. XR erect and supine
- c. US abdomen
- d. Coag profile
- e. CXR

Ans. The key is C. US abdomen. [Likely cause of bleeding and shock is ruptured fallopian tube for which appropriate next investigation is US abdomen].

967. A 21yo woman who is on COCP had to take azithromycin. What should be advised for her contraception?

- a. Using 7d condoms after antibiotics and avoid pill free break
- b. Using 14d condoms after antibiotics and avoid pill free break
- c. Using 7d condoms after antibiotics
- d. No extra precaution
- e. Using 14d condoms after antibiotics

Ans. The key is D. No extra precaution. [Before it was thought that antibiotics like azithromycin inhibits the enzyme and reduce the efficacy of COCP. But later it was established that practically no significant changes occur and so no need of any extra precaution].

968. A 60yo woman presented with radial fx and had a colle's fx and supracondylar fx in the past. What inv is req to detect her possibility of having the same prb later?

- a. DEXA scan
- b. MRI
- c. Nuclear bone scan
- d. CT
- e. Bone biopsy

Ans. The key is A. DEXA scan. [The likely cause of these multiple fracture is osteoporosis (post menopausal women) for which we should do DEXA scan to establish the diagnosis].

969. A 43yo woman presents with low mood, loss of libido, sleep disturbance, tiredness, palpitation, chest discomfort, irritability and recurrent worries. What is the most likely dx?

- a. Seasonal Affective Disorder
- b. Mod depression
- c. Dysthymia
- d. GAD
- e. Bipolar disorder

Ans. The key is B. Moderate depression. [Mild depression: i) Low mood ii) Anhedonia iii) Guilt iv) Hopelessness v) Worthlessness vi) Inability to concentrate. Tx CBT

Moderate depression: Features of mild + vii) Poor sleep viii) Poor Appetite ix) Poor libido x) Easy fatigability. Tx Antidepressants

Severe depression: Features of moderate + xi) Suicidal intentions. Tx ECT].

970. Which of the following is true for tamoxifen?

- a. Increased incidence of endometrial carcinoma
- b. Increased risk of breast ca
- c. Increased risk of osteoporosis
- d. Increased risk of ovarian ca

Ans. The key is A. Increased incidence of endometrial carcinoma.

971. A 45yo male complains of tremors in hands. Exam: tremors are absent at rest but present when arms are held outstretched and persist on movement. What is the most probable dx?

- a. Parkinsonism
- b. Benign essential tremor
- c. Cerebellar disease
- d. Liver failure
- e. Stroke

Ans. The key is B. Benign essential tremor. [Tremors absent at rest and present on outstretched hand and persist on movement are benign essential tremor].

972. Pregnant lady had her antenatal screening for HIV and Hep B. what more antenatal inf should she be screened for?

- a. Rubella and syphilis
- b. Toxoplasma and rubella
- c. Syphilis toxoplasma
- d. Hep C & E
- e. Hep A & C

Ans. The key is A. Rubella and syphilis.

973. A young man has been found in the park, drunk and brought to the ED by ambulance. He recently lost his job and got divorced. He thinks nurses are plotting against him. What is the most likely dx?

- a. Schizoid personality
- b. Borderline personality
- c. Schizophrenia
- d. Psychotic depression
- e. Paranoid

Ans. The key is E. Paranoid personality disorder. [Patient's disease (Paranoid personality disorder) is responsible for his divorce and loss of job. Suspiciousness to wife is reason for divorce].

Paranoid personality disorder: DSM v. Berstein	
DSM-IV criteria (summarised)	Primary traits identified by Berstein (2007)
Extreme distrust of others from an early age	Mistrust/suspiciousness
Bearing persistent grudges	Antagonism/aggressiveness
Preoccupation with suspicions that others want to harm or deceive them	Introversion/excessive autonomy
Belief that sexual partners are unfaithful	Hypersensitivity
Reluctance to confide for fear of malicious use of information given	Hypervigilance
Perception of innocent incidents as threatening	Rigidity

974. An elderly man who used to work in the shipyard industry presented with cough and SOB few weeks to months. He was given salbutamol nebulization and antibiotics and admitted to the ward. He died 3d later. CT: patchy infiltrates, pleural thickening and pleural effusion. Why is this a coroner's case?

- a. Pt got wrong dx or management
- b. Pt died soon after admission
- c. Death could be due to occupational illness

Ans. The key is C. Death could be due to occupational illness.

975. A 26yo lady came with abdominal pain, vaginal discharge and low grade fever. What is the most likely dx?

- a. HELLP syndrome
- b. Acute PID
- c. Ectopic pregnancy
- d. Appendicitis

Ans. The key is B. Acute PID.

976. A new screening test has been devised to detect early stages of prostate ca. However, the test tends to dx a lot of ppl with no cancer, although they do have cancer as dx by other standard tests. What is this flaw called?

- a. False +ve
- b. True +ve
- c. False -ve
- d. True -ve
- e. Poor specificity

Ans. The key is C. False negative.

977. A 26yo political refugee has sought asylum in the UK and complains of poor conc. He keeps getting thoughts of his family whom he saw killed in a political coup. He is unable to sleep and feels hopeless about his survival. Because of this he is afraid to go out. What is the most likely dx?

- a. Acute stress disorder
- b. PTSD
- c. Social phobia
- d. OCD
- e. GAD

Ans. The key is B. PTSD. [Keep getting thoughts of his family disaster, insomnia, to avoid similar circumstances he is avoiding going out these are suggestive of PTSD].

978. A 2yo boy presented with gradual swelling of feet and poor feeding. He has gained weight and has dark urine. What is the single most appropriate inv?

- a. Serum albumin (2nd)
- b. 24h urinary protein (1st)
- c. Serum calcium
- d. BUE
- e. Serum glucose

Ans. The key is B. 24 hr urinary protein. [A case of nephritic syndrome. So the single most appropriate investigation from the given options is 24 hour urinary protein].

979. A 26yo lady presents with high fever, lower abdominal pain and purulent vaginal discharge. She looks very unwell. What is the most appropriate management?

- a. Tetracycline 250mg QD
- b. Doxycycline 100mg BD and metronidazole 400mg BD
- c. IV Ceftriaxone 2g with doxycycline 100mg
- d. IV ceftriaxone 2g with doxycycline 500mg
- e. Ofloxacin 400mg BD and metronidazole 400mg BD

Ans. The key is C. IV Ceftriaxone 2g with doxycycline 100mg. [The disease is severe needing inpatient management with IV Ceftriaxone 2g + IV doxycycline 100 mg].

980. A 39wk pregnant woman came to labor suite 3d after an obstructed labour presents with pain and swelling of one leg. Exam: leg has blue mottling and is cold. What is the dx?

- a. DVT
- b. Post phlebitis syndrome
- c. Embolus
- d. Varicose vein
- e. Herpes gladiatorum

Ans. The key is C. Embolus.

981. An 8yo boy has his tonsils and adenoids removed. On the 7th post-op day, he comes back to the ED with hemoptysis and fever. What is the most appropriate management?

- a. Admit for IV antibiotics
- b. Prescribe oral antibiotics and discharge
- c. Packing
- d. Surgery
- e. Reassurance

Ans. The key is A. Admit for IV antibiotic. [Most secondary hemorrhage occurs due to infection which erodes a vessel. So patient should be admitted for IV antibiotics].

982. A 50yo female had swelling in her ankles. She is a known alcoholic. Now she presented with breathlessness and palpitations. What is the most likely cause of her condition?

- a. VT
- b. SVT
- c. A-flutter
- d. A-fib
- e. V-ectopics

Ans. The key is D. Atrial fibrillation. [Ankle swelling suggests alcoholic

cardiomyopathy and alcoholism is also a well known cause of atrial fibrillation].

983. A young boy has acute scrotal pain for a few hours. Exam: one testis is very painful to touch. He had this kind of pain before but it was mild and resolved itself within 30mins. What would you do next?

- a. Urgent exploration
- b. US
- c. Antibiotics
- d. IV fluids
- e. Doppler US

Ans. The key is A. Urgent exploration. [As sudden onset of severe pain likely diagnosis is torsion of testis. (infection takes a more prolonged course). Next step is urgent exploration].

984. An 8wk pregnant woman presents with persistent vomiting and weight loss. Exam: HR=110bpm. Dehydration was corrected with NS infusion and K+. The condition didn't improve so IM cyclizine was given. She is still vomiting. What is the next appropriate management?

- a. IV fluids
- b. IV antiemetics
- c. IV steroids
- d. Terminate pregnancy
- e. Thiamine

Ans. The key is C. IV Steroid. [Steroids may be used in patient's of hyperemesis gravidarum refractory to standard therapy].

985. A 28yo lady presents with dyspareunia and dysmenorrhea. She is very obese. She now wants reversible contraceptive method. Which of the following will be most suitable for her?

- a. Mirena
- b. COCP
- c. POP
- d. Copper T
- e. Barrier method

Ans. The key is A. Mirena.

986. A young lady who is 28wks pregnant presents with vaginal bleeding. She has lost about 200ml of blood. Exam: uterus is tender. Resuscitation has been done. What is the most imp inv to establish the dx?

- a. US
- b. CT
- c. D-dimer
- d. Clotting profile
- e. None

Ans. The key is A. US. [Antepartum hemorrhage. Most important investigation to establish the dx is US].

987. A 14yo girl presents with primary amenorrhea and a short stature. What is the most likely dx?

- a. Down's syndrome
- b. Klinefelter's syndrome
- c. Turner's syndrome
- d. Fragile X syndrome
- e. Normal finding

Ans. The key is C. Turner's syndrome. [Down's syndrome and Fragile x syndrome don't have primary amenorrhea. Klinefelter's syndrome patients are tall males. So the likely diagnosis is Turner's syndrome].

988. A 32yo woman wants reversible form of contraception. She has one child delivered by emergency C-section. She also suffers from migraine and heavy periods. What is the most suitable form of contraception for this lady?

- a. COCP
- b. Mini pill
- c. IUCD
- d. Barrier method
- e. Abstinence

Ans. The key is C. IUCD. It is wrong key! Correct key is **b. Mini pill**.

989. A 45yo known hypertensive man presents with hematuria, proteinuria and edema. What is the definitive dx test for him?

- a. Urine protein
- b. Renal biopsy
- c. Renal function test
- d. Urine microscopy
- e. Serum protein

Ans. The key is B. Renal biopsy. [In nephritic syndrome glomerulus is affected. So renal biopsy is the definitive diagnostic test].

990. A 47yo man presents with proteinuria+, BP=160/95mmHg, small kidneys that have smooth renal pelvis. What is the most probable dx?

- a. GN
- b. Chronic pyelonephritis
- c. Unilateral renal artery stenosis
- d. Multiple myeloma
- e. ARF

Ans. The key is A. GN. [In chr. Pyelonephritis US will demonstrate renal scarring and urinalysis will demonstrate pyuria which are absent here. In renal artery stenosis there will be considerable difference in kidney size from one another which is not found here. Here likely diagnosis is GN].

991. You are the HO in the hospital and the lab report of a pt shows glucose=4mmol/l, K+=5.2mmol/l, Na+129mmol/l. what is the most appropriate management?

- a. NS 0.9%
- b. NS 0.45%
- c. NS 0.9% and insulin
- d. Insulin
- e. Dextrose

Ans. The key is A. NS 0.9% [Here there is significant hyponatremia with mild hyperkalemia. Glucose is in lower normal level. Insulin can shift K⁺ in cells but this mild hyperkalemia does not need this treatment at this level. More over in lower blood glucose insulin may cause hypoglycemia. So the best management option is A. NS 0.9% which will correct the electrolyte imbalance (including K⁺ level by renal handling)].

992. A 27yo man presents with abdominal pain. He says his urine is dark. Exam: BP=160/105mmHg. What is the most appropriate inv?

- a. US
- b. Renal biopsy
- c. CT
- d. Urine protein
- e. Urine microscopy

Ans. The key is A. US. [Abdominal pain, Dark urine (hematuria) and hypertension suggests ADPKD. The sensitivity of ultrasonography for ADPKD1 is 99% for at-risk patients older than 20 years].

993. A 12m child with AIDS is due for his MMR vaccination. What is the single most appropriate action?

- a. Defer immunization for 2wks
- b. Don't give vaccine
- c. Give half dose of vaccine
- d. Give paracetamol with future doses of the same vaccine
- e. Proceed with standard immunization schedule

Ans. The key is B. Don't give vaccine. [MMR is live attenuated vaccine which should be avoided in AIDS]. [*** Please note, In similar question where asked about HIV positive child's vaccination and the answer was give all vaccines except BCG. HIV positive is not in a immunodeficient state and can receive live attenuated vaccines (except BCG), where as child with AIDS means he has criteria of immunodeficiency already for which all live attenuated vaccines should be avoided]. [Please note the two terms "HIV positive" and "with AIDS"].

994. A young man presents with sudden, severe pain and swelling in the scrotum. Exam: one testis seems higher than the other. What is the most probable dx?

- a. Varicocele
- b. Hematocele
- c. Testicular tumor
- d. Epidiymo-orchitis
- e. Testicular torsion

Ans. The key is E. Testicular torsion. [Sudden severe pain, scrotal swelling and higher position of the affected testis is diagnostic of testicular torsion. You may get further support from examining cremasteric reflex which is absent in testicular torsion].

995. A 24yo male involved in RTA with XR: fx neck of humerus. What is the single most associated nerve injury?

- a. Axillary nerve
- b. Radial nerve
- c. Median nerve
- d. Ulnar nerve

Ans. The key is A. Axillary nerve.

996. A 64yo man complains of increasing SOB and cough for the past 18m. He coughs up a Tbsp of mucopurulent sputum with occasional specks of blood. What is the most likely underlying cause?

- a. Acute bronchitis
- b. Bronchiectasis
- c. Chronic bronchitis
- d. Lung cancer
- e. Pneumonia

Ans. The key is C. Chronic bronchitis. [There may be specks of blood in

sputum in both bronchiectasis, acute and chronic bronchitis. Duration of disease is 18 months, so it is not acute bronchitis. Again only one tablespoonful sputum does not justify the term copious sputum of bronchiectasis in which sputum will be much more like cup-full in amount. So it is chronic bronchitis].

997. A 55yo man who is hypertensive suddenly lost his vision. The retina is pale and fovea appears as a bright cherry red spot. What is the single most appropriate tx?

- a. Pan retinal photocoagulation
- b. Corticosteroids
- c. Scleral buckling
- d. Surgical extraction of lens
- e. Pressure over eyeball

Ans. The key is E. Pressure over eyeball. [In central retinal artery occlusion (CRAO) retina becomes pale and fovea becomes cherry red. Hypertension is a major cause of CRAO. Apply direct pressure for 5-15 seconds, then release. Repeat several times. Ocular massage can dislodge the embolus to a point further down the arterial circulation and improve retinal perfusion].

998. A 32yo man with schizophrenia and a hx of violence and distressing auditory hallucinations was admitted to the ward with aggressive behavior and has already smashed his room. He is refusing any oral meds. What is the single most appropriate injection?

- a. Flupenthixol
- b. Fluphenazine
- c. Haloperidol
- d. Paraldehyde
- e. Risperidone

Ans. The key is C. Haloperidol. [If oral preparation was asked we could give risperidone but in question asked injectable preparation. Injection Risperidone is a depot preparation the action of which takes few days to start. So in acute case it is not suitable; hence from the given options haloperidol is the best choice].

999. A 65yo man complains of hematuria, frequency, hesitancy and nocturia. He reports that on certain occasions he finds it difficult to control the urge to pass urine. Urine microscopy confirms the presence of blood but no other features. What is the most probable dx?

- a. BPH
- b. Bladder ca
- c. Prostatic ca
- d. Pyelonephritis
- e. Prostatitis

Ans. There are two keys A. BPH and C. Prostatic carcinoma. [There

are no constitutional features of carcinoma. Bleeding is more common in BPH and occurs in a minority of cases and much less common in prostatic carcinoma. Features given are of prostatism only which favours the diagnosis of BPH].

1000. A 60yo man presents with mass in the groin. Exam: mass lies below the midpoint of the inguinal ligament and is pulsatile. What is the most probable dx?

- a. Direct inguinal hernia
- b. Saphenavariix
- c. Femoral hernia
- d. Irreducible hernia
- e. Femoral aneurysm

Ans. The key is C. Femoral hernia. Wrong key! Correct key is femoral aneurism. [Hernia below pubic tubercle (below inguinal ligament) is femoral hernia. But below mid-inguinal point and pulsatile mass is femoral aneurism].

1001. An 82yo man has woken up with incoherent speech and difficulty in finding the right words. Exam: otherwise normal, good comprehension. Which anatomical site is most likely to be affected?

- a. Broca's area
- b. Wernicke's area
- c. Midbrain
- d. Parietal cortex
- e. Pons

Ans. The key is A. Broca's area. [A person with expressive aphasia will exhibit halting and effortful speech. Speech may only include important content words. Word comprehension is preserved. The person may still be understood, but sentences will not be grammatical. This contrasts with [receptive or Wernicke's aphasia](#), which is distinguished by a patient's inability to comprehend language or speak with appropriately meaningful words though fluency may be preserved].

1002. A 25yo woman has a recent cough, hoarseness and swelling in the neck. There are several nontender swellings on both sides of her neck. She has lost 13kgs. She takes recreational drugs. What is the most probable dx?

- a. Thyrotoxicosis
- b. Hyperthyroidism
- c. Vocal cord nodules
- d. Carcinoma bronchus
- e. TB

Ans. The key is E. TB. [Cough, wt. loss, non-tender cervical lymphade-

nopathy, and immunodeficient state as a result of recreational drug use all these favours the diagnosis of TB. Laryngeal involvement may be the cause of hoarseness].

1003. A 30yo woman presents with acute headache. She complains of seeing halos especially at night. What is the single most likely defect?

- a. Paracentral scotoma
- b. Mono-ocular field loss
- c. Tunnel vision
- d. Central scotoma
- e. Cortical blindness

Ans. The key is C. Tunnel vision. [The diagnosis is glaucoma (head-ache and haloes especially at night). In glaucoma there occurs tunnel vision].

1004. A 35yo man presents with a headache that worsens on bending his head forward. What is the most likely dx?

- a. Chronic sinusitis
- b. SAH
- c. Migraine
- d. Cluster headache
- e. Tension headache

Ans. The key is A. Chronic sinusitis.

1005. A 20yo man presents with painful swallowing. Exam: trismus and unilateral enlargement of his tonsils. The peritonsillar region is red, inflamed and swollen. What is the most appropriate tx?

- a. Oral antibiotics
- b. IV antibiotics and analgesics
- c. I&D with antibiotics
- d. Analgesics with antipyretics
- e. Tonsillectomy

Ans. The key is C. I&D with antibiotics. [The dx is peritonsillar abscess and tx is I&D with antibiotics].

1006. A 40yo manual worker presents with a swelling in the groin. Exam: mass is found to be just above and lateral to the pubic tubercle. It is reducible. On applying pressure on the internal ring there is no cough impulse seen. What is the most probable dx?

- a. Direct inguinal hernia
- b. Indirect inguinal hernia
- c. Femoral hernia
- d. Strangulated hernia
- e. Femoral aneurysm

Ans. The key is B. Indirect inguinal hernia. [Swelling in the groin; mass just above and lateral to the pubic tubercle means inguinal hernia. It is reducible. On applying pressure on the internal ring there is no visible cough impulse; it means the hernia enters through deep ring, and enters scrotum passing through the superficial ring. That means it is indirect inguinal hernia].

1007. A 34yo male presents with headache and vomiting. Exam: temp=38.5C, neck stiffness, discharge from left ear and right sided hyper-reflexia with an extensor plantar response. What is the most likely dx?

- a. Cerebral tumor
- b. Meningitis
- c. Cerebellar tumor
- d. Cerebral abscess
- e. Normal pressure hydrocephalus

Ans. The key is D. Cerebral abscess. [Otitis media can lead to cerebral abscess].

1008. A 26yo male presents with speech difficulties. Exam: nystagmus. Which anatomical site is most likely to be affected?

- a. Midbrain
- b. Pons
- c. Cerebellum
- d. Cerebrum
- e. Vestibule cochlear nerve

Ans. The key is C. Cerebellum. [Difficulty speech (cerebellar dysarthria) and nystagmus are suggestive of cerebellar lesion].

1009. A 75yo man presents with Bell's palsy. His PMH is significant for late onset asthma and heart failure. He also reports to have consulted his GP for generalized rash prv. CXR: multiple soft shadows and CBC: eosinophilia. What is the single most likely positive antibody?

- a. p ANCA
- b. c ANCA
- c. Anti Ro
- d. Anti dsDNA
- e. Anti centromere

Ans. The key is A. p-ANCA. [The dx is Churg Strauss Syndrome (CSS). There are six criteria for dx of CSS:

Asthma (wheezing, expiratory rhonchi).
Eosinophilia of more than 10% in peripheral blood.
Paranasal sinusitis.
Pulmonary infiltrates (may be transient).
Histological confirmation of vasculitis with extravascular eosinophils.
Mononeuritis multiplex or polyneuropathy.

The presence of four out of six of these features has a high specificity and sensitivity for the diagnosis of CSS.

In the given case there are 1. Bell's palsy (mononeuritis multiplex) 2. Asthma 3. Multiple soft shadows on CXR (pulmonary infiltrates) 4. Eosinophilia. Presence of these 4 features are diagnostic of CSS. In CSS %70 patient is p-ANCA positive!].

1010. A 50yo man complains of visual prbs and dull pain in the left eye. Fundoscopy reveals papilloedema. He was dx with MS 2yrs ago. There is no consensual light reflex of the right eye. What is the single most likely defect?

- a. Paracentral scotoma
- b. Mono-ocular field loss
- c. Homonymous upper quadrantanopia
- d. Central scotoma
- e. Homonymous lower quadrantanopia

Ans. The key is B. Mono-ocular field loss.

1011. A 54yo pt wakes up with right sided weakness. His current medication is bendroflumethiazide for HTN. Pulse=92bpm, BP=160/90mmHg. CT shows left cerebral infarct. What is the most appropriate tx?

- a. Alteplase
- b. Aspirin
- c. Clopidogrel
- d. Dipyridamole
- e. Simvastatin

Ans. The key is A. Alteplase. It is a wrong key! Correct option is B. Aspirin. [In stroke window period to use alteplase is 4.5 hours. In the given history we can in no way certain the time of stroke and we can not proceed for alteplase unless window period is confirmed. Hence we cannot give alteplase but Aspirin].

1012. A 33yo man presented to the GP with hx of headaches and photophobia. The GP examines him and finds a rash and is now ringing you at the hospital for advice. What would you advice the GP?

- a. Send pt home
- b. Start IV benzylpenicillin
- c. Conduct LP
- d. Start IV ceftriaxone

Ans. The key is B. Start IV benzylpenicillin. [Before hospitalization IV benzylpenicillin. In hospital Ceftriaxone can be given but not in calcium containing fluid instead give Cefotaxime (NICE). According to OHCM hospital management is Cefotaxime if <55yrs and Cefotaxime + Ampicillin if >55yrs].

1013. An 89yo pt has lung cancer. His Na+=122mmol/l. What is the tx for this?

- a. Demeclocycline
- b. Vasopressin
- c. Restrict fluids
- d. Reassure

Ans. There are two keys. A. Demeclocycline and C. Restrict fluids. Correct key is C. Restrict fluid. [This is a case of SIADH secondary to lung cancer and in case of SIADH even in severe hyponatremia 1st line treatment is fluid restriction. So for this question answer is C. Fluid restriction].

1014. A 25yo woman who is 11wks pregnant had central abdominal pain for 36h. The pain is now colicky. There is no vaginal bleeding. She has vomited once and has had an episode of loose motion. She looks ill, temp=37.8C and there is rebound tenderness in the RIF. What is the most probable dx?

- a. Salpingitis
- b. PID
- c. Appendicitis
- d. Ovarian torsion
- e. Uterine fibroid

Ans. The key is C. Appendicitis. [No vaginal bleeding and pain above pelvis makes pregnancy complication less likely. Loose motion, low grade temperature and positive Mc Burney's sign makes the diagnosis of appendicitis more probable].

1015. A 42yo man presents with stroke. He is not able to walk straight and his speech is slurred. What is the initial appropriate inv?

- a. CT brain
- b. PET brain
- c. MRI brain
- d. Carotid angiography
- e. Monitor for 24h

Ans. The key is C. MRI brain. [Ataxia and slurred speech are features of cerebellar lesion which is posterior fossa organ. For posterior fossa lesion MRI is the investigation of choice! So key is correct. It is C. MRI brain].

1016. A 24yo woman has severe depression 3m after the birth of her first child. She is breastfeeding but is otherwise unable to look after the baby and is convinced that her family is likely to kill her. She has no interest in anything and keeps crying. What is the most appropriate tx?

- a. Fluoxetine
- b. Citalopram
- c. CBT
- d. ECT
- e. Haloperidol

Ans. The key is D. ECT. This is wrong key. Correct key is E. Haloperidol. [Diagnosis is given in question as severe depression and as features of psychosis present the better diagnosis would be psychotic depression. As onset is beyond 4 weeks it is no more post partum psychosis. So the 1st line treatment for psychotic depression is combination of antipsychotic + antidepressant. As the combination is not given as options first choice goes for antipsychotic that is E. Haloperidol].

1017. A 20yo woman with no prv hx of ear complains, presents with 1d hx of severe pain in the right ear which is extremely tender to examine. What is the single most likely dx?

- a. Chondromalasia
- b. Furuncle
- c. Myringitis
- d. OE
- e. OM

Ans. The key is D. OE. [Extreme tenderness to examine indicate otitis externa].

1018. A couple has just finished their detox regime and wants a drug with a pharmacological action to serve as a deterrent when they take alcohol. What drug is the appropriate choice?

- a. Disulfiram
- b. Acamprosate
- c. Vitamin supplement
- d. Naloxone
- e. Naltrexone

Ans. The key is B. Acamprosate. This is a wrong key! Correct key is A. Disulfiram. [Acamprosate is not a deterrent (which keeps away from drinking by making it unpleasant) but Disulfiram!]

1019. A 68yo woman presents to the ED with confusion. Temp=39.3C and productive cough. Sputum is rusty colored after 2 days. CXR shows right lower lobe consolidation. What is the most likely organism?

- a. Streptococcus pneumonia
- b. Staphylococcus aureus
- c. Coxiella burnetti
- d. Mycoplasma pneumonia

Ans. The key is A. Streptococcus pneumonia. [Typical presentation of streptococcal pneumonia].

1020. A 70yo man with prostatic cancer has had severe acute back pain waking him up at night for 6wks. What is the most appropriate inv?

- a. MRI spine
- b. Radionuclide bone scan
- c. DEXA scan
- d. Serum ALP concentration
- e. Serum calcium concentration

Ans. The key is B. Radionuclide bone scan. [MRI is good for soft tissue but not for bone. If it was radiculopathy, spinal cord compression or prolapsed disc creating pressure on nerve MRI would be fine but not for bony metastasis. Here investigation of choice is radionuclide bone scan].

1021. An asymptomatic 56yo man who has never consumed alcohol came for a routine checkup. Exam: increased skin pigmentation, spider angioma, cardiomegaly, S3 gallop, liver firm with 8cm span, no ascites. He is in the risk of which condition?

- a. Cerebellar degeneration
- b. Wernicke's encephalopathy
- c. Renal failure
- d. Hepatoma
- e. Hepatic vein thrombosis

Ans. The key is D. Hepatoma. [Increased skin pigmentation, features of chronic liver disease (spider angioma), Cardiomyopathy (cardiomegaly, S3 gallop), Enlarged liver these are suggestive of Haemochromatosis. (OHCM: Slate-grey skin pigmentation; signs of chronic liver disease; hepatomegaly; cirrhosis; dilated cardiomyopathy; osteoporosis; also endocrinopathies are features of haemochromatosis). If cirrhosis, 22-30% get hepatocellular cancer].

1022. A 39yo male presents with visual symptoms. Ophthalmoscopy shows papilloedema. Which anatomical site is most likely to be affected?

- a. Optic nerve
- b. Optic disc
- c. Optic radiation
- d. Occulomotor nerve
- e. Optic chiasma

Ans. The key is B. Optic disc.

1023. A 75yo man has been attending the clinic for lower urinary tract symptoms. His mood is very low and he says he feels unhappy, anxious and unable to sleep. He has been dx with moderate depression. What tx would be most effective for this pt?

- a. Amitriptyline
- b. Citalopram
- c. CBT
- d. Dosulepin
- e. Diazepam

Ans. The key is B. Citalopram. [Mild depression = CBT, Moderate depression = Antidepressant, Severe depression & Psychotic depression = ECT, Amitriptyline and Dosulepine causes urinary retention (which is comparatively less in citalopram) so not suitable in a patient with lower urinary symptoms. Hence Citalopram is the preferred option].

1024. A 48yo pt after surgical removal of mandibular ca presents with perioral paresthesia and severe pain which is not relieved by oral morphine. What is the next step in treating this pt?

- a. Oral amitriptyline (2nd line)
- b. Oral oxycodone
- c. PCA
- d. IV morphine
- e. Fentanyl patch
- f. Gabapentine (1st line)

Ans. The key is F. Gabapentine. [This pain is likely due to nerve injury during operation and both amitriptylin and Gabapentine are 1st line for neuropathic pain].

1025. A 34yo man was slapped over his right ear in a fight. There is blood coming from his external auditory canal and he has pain, deafness and ringing in his ears. What is the most appropriate initial inv?

- a. CT
- b. MRI
- c. Otoscopy
- d. Skull XR
- e. Facial XR

Ans. The key is A CT. It is a wrong key! Correct key is C. Otoscopy. [Traumatic perforation of the tympanic membrane (TM) can cause pain, bleeding, hearing loss, tinnitus, and vertigo. Diagnosis is based on otoscopy. Treatment often is unnecessary. Antibiotics may be needed for infection. Surgery may be needed for perforations persisting > 2 mo, disruption of the ossicular chain, or injuries affecting the inner ear. Reference: Merck Manual (Professional version) [www.merckmanuals.com/professional/ear,-nose,-and-throat-disorders/middle-ear-and-tympanic-membrane-disorders/traumatic-perforation-of-the-tympanic-membrane].

1026. A 45yo man has developed an annular rash with a scaly edge on his thigh. The rash has been spreading over the last 3wks. He has some general aches and pains. What is the single most useful investigation?

- a. ANA
- b. Biopsy lesion
- c. Lyme antibodies
- d. Skin scrap for mycology
- e. Skin swab for bacteria

Ans. The key is C. Lyme antibodies. [Spreading annular rash suggests erythema migrans of Lyme disease].

1027. A 80yo man with prostatic cancer has confusion, thirst, abdominal pain and an abnormal ECG. What is the most appropriate inv?

- a. MRI spine
- b. Radionuclide bone scan
- c. DEXA scan
- d. Serum ALP concentration
- e. Serum calcium concentration

Ans. The key is E. Serum calcium concentration. [Confusion, thirst, abdominal pain and ECG changes (marked shortening of QT interval) are features of hypercalcemia. So E. Serum calcium concentration is the likely option].

1028. A 27yo lady after C-section developed epigastric pain after 8h. What is the appropriate inv?

- a. ABG
- b. Coag profile
- c. Liver enzyme
- d. Liver biopsy

Ans. The key is C. Liver enzyme. [Epigastric pain is a warning sign of HELLP syndrome. So to rule out HELLP syndrome Liver enzymes should be done].

1029. A 35yo woman presents with visual problems. CT brain reveals pituitary tumor. What is the single most likely defect?

- a. Homonymous hemianopia
- b. Homonymous upper quadrantanopia
- c. Bitemporal hemianopia
- d. Cortical blindness
- e. Homonymous lower quadrantanopia

Ans. The key is C. Bitemporal hemianopia. [pituitary tumour by pressing optic chiasma causes bitemporal hemianopia].

1030. A 45yo heroin addict was involved in a car crash and is now paraplegic. During the 1st week of hospital stay he cried everyday because he couldn't remember the accident. What is the most likely dx?

- a. PTSD
- b. Severe depression
- c. Organic brain damage

Ans. The key is C. organic brain damage.

1031. A pt with T1DM has a fundus showing micro-aneurysm and hard exudate. What is the single most likely dx?

- a. Macular degeneration
- b. Hypertensive retinopathy
- c. MS
- d. Diabetic background
- e. Proliferative DM retinopathy

Ans. The key is D. Diabetic background retinopathy. [Microaneurism, hard exudates are seen in background diabetic retinopathy].

1032. A 62yo man has multiple liver mets due to adenocarcinoma with an unknown primary. He is deeply jaundiced and has ascites with edema upto the buttocks. He is now drowsy and his family are worried that he is not drinking enough. His meds include: haloperidol 1.5mg, lactulose 10ml. Bloods taken 3d ago: electrolytes normal, urea=6.5mmol/l, creatinine=89mmol/l, calcium=2.04mmol/l, albumin=17g/L, total bilirubin=189mmol/l. What is the single most appropriate management of his fluid intake?

- a. Albumin infusion
- b. Crystalloids IV
- c. Crystalloids SC
- d. Fluids via NGT
- e. Fluids PO

Ans. The key is A. Albumin infusion. [Here serum albumin is 17. So the patient developed ascites and oedema secondary to reduced plasma colloidal osmotic pressure. Albumin infusion can help rise the colloidal osmotic pressure and improve the patients condition].

1033. A 2yo with atrophy of the buttocks, distended abdomen with frequent offensive smelly stool. Choose the single most likely inv?

- a. Upper GI endoscopy
- b. Endomysial/alpha gliadin antibody
- c. Sweat test
- d. Colonoscopy
- e. Stool culture

Ans. The key is B. Endomysial/alphagliadin antibody. [Atrophy of buttock due to fat malabsorption and distended abdomen (sometimes with everted umbilicus) with frequent offensive smelly stools are seen in coeliac disease. Hence endomysial/alpha gliadin antibody should be done].

1034. A 78yo woman is brought to the hospital complaining of back pain and is referred to the surgeon. She has been saying that her mother is due to visit her today and that somebody must have broken her lower back as she is in agony. Labs: creatinine=295mmol/l, calcium=3.03mmol/l. Which inv is most likely to lead to a dx?

- a. US KUB
- b. XR Spine
- c. IVU
- d. Bence-Jones Protein
- e. Mental state exam

Ans. The key is D. Bence-Jones protein. [Severe back pain, high calcium level and renal impairment are typical of multiple myeloma].

1035. A 40yo woman presents with dysphagia. Exam: febrile with erythema and middle neck swelling. What is the best management strategy?

- a. IV antibiotics and drainage
- b. Antipyretics
- c. XR neck
- d. Endoscopic diverticulectomy
- e. I&D

Ans. The key is A. IV antibiotics and drainage. [Neck abscess. Treated with IV antibiotics and drainage].

1036. A young lady presents with gradually worsening headaches, visual disturbance, and lack of energy. MRI shows 15mm tumor in the pituitary fossa. What is the tx of choice?

- a. Radiotherapy
- b. Octreotide
- c. Reassurance and f/u after 6m
- d. Surgery
- e. Chemotherapy

Ans. The key is D. Surgery. [Hormonically active tumour, tumour causing pressure symptoms (like headache, visual disturbance) and large size of tumour are indications for surgical removal].

1037. A man with dementia has an ulcerative lesion on his forehead. He wants it removed so 'it can help improve his memory'. Wife says he is not fit to give consent. What will you do?

- a. Get letter signed from the GP
- b. Get letter signed from the wife
- c. Get letter signed from the pt
- d. Refer to psychiatrist to assess the mental capacity to give consent

Ans. The key is D. Refer to psychiatrist to assess the mental capacity to give consent

1038. A pt with flame shaped hemorrhage on long term tx with nifedipine. What is the single most likely dx?

- a. Macular degeneration
- b. HTN retinopathy
- c. MS
- d. DM background
- e. Proliferative DM retinopathy
- f. SLE

Ans. The key is B. HTN retinopathy. [Stages of hypertensive retinopathy].

- Grade 1: Silver wiring
- Grade 2: 1 + AV nipping
- Grade 3: 2 + flame shaped hemorrhage
- Grade 4: 3 + optic disc edema + macular star].

1039. A pt whose pain is not relieved by oral codeine. What is the best management?

- a. Oral oxycodone
- b. Co-codamol
- c. PCA
- d. IV morphine
- e. Oral morphine

Ans. The key is E. Oral morphine.

1040. A 6wk baby with vomiting, irritability and palpable mass in the abdomen on feeding. Choose the single most likely inv?

- a. Upper GI endoscopy
- b. Barium meal
- c. US
- d. CT abdomen
- e. Barium enema

Ans. The key is C. US. [Palpable mass in the abdomen "ON FEEDING" (just after feeding the mass becomes more prominent and can be palpated more easily) is suggestive of pyloric stenosis. US is used to diagnose this].

1041. A 79yo man who is being treated with GnRH antagonist for proven adenocarcinoma of the prostate attends a follow up session. What is the most appropriate inv?

- a. Serum AFP
- b. Serum PSA
- c. Serum acid phosphates conc
- d. Serum ALP isoenzyme conc
- e. Trans rectal US

Ans. The key is B. Serum PSA. [Serum PSA is used to assess the progress of treatment. (If a man's PSA level rises after prostate cancer treatment, his doctor will consider a number of factors before recommending further treatment. Additional treatment based on a single PSA test is not recommended. Instead, a rising trend in PSA level over time in combination with other findings, such as an abnormal result on imaging tests, may lead a man's doctor to recommend further treatment)].

1042. A middle aged woman has some weakness of hand after an injury. Which vertebra will be the lowest to be included on cervical XR to dx the injury?

- a. C7/T1
- b. C8/T1
- c. C5/C6
- d. C6/C7

Ans. The key is A. C7/T1.

1043. A 50yo man with a known hx of stroke. He can't remember anything about his life. What is the single most likely defect?

- a. Homonymous hemianopia
- b. Homonymous upper quadrantanopia
- c. Bitemporal hemianopia
- d. Binasal hemianopia
- e. Homonymous lower quadrantanopia

Ans. The key is B. Homonymous upper quadrantanopia. [Memory processing occur in temporal lobe. So as the patient lost memory his temporal lobe is involved. We know temporal lobe lesion causes "homonymous upper quadrantanopia" which is the key here!]

1044. An 18yo girl has been dx with anorexia nervosa and has mild depressive symptoms. She has cut down her food intake for the last 18m and exercises 2h everyday. Her BMI=15.5, BP=90/60mmHg. What would be the single most appropriate management?

- a. Refer to eating disorder clinic
- b. Refer to psychodynamic therapy
- c. Refer to acute medical team
- d. Prescribe antidepressant

Ans. The key is C. Refer to acute medical team. This is a wrong key! Correct key is A. Eating disorder unit. [Anorexia nervosa is moderate when BMI is 15-17.5 as in given case. In moderate anorexia (BMI 15-17.5, no evidence of system failure) routine referral can be to the local community mental health team (CMHT)/adolescent unit or Eating Disorder Unit (EDU) if available. So the key is A. Eating disorder clinic]. OHCS, 9th edition, page-349.

1045. A 36yo woman has an injury to the right external laryngeal nerve during a thyroid surgery. What symptom would be expected in this pt?

- a. Stridor
- b. Hoarseness
- c. Aphonia
- d. Dysphonia
- e. Aphasia

Ans. The key is D. Dysphonia. [External laryngeal nerve (smaller, external branch of the superior laryngeal nerve) lesion causes monotone voice (loss of ability to produce pitched sound) that is dysphonia].

1046. A 75yo woman has weakness of the left side of her face. She has had a painful ear for 48h. There are pustules in the left ear canal and on the eardrum. What is the single most likely dx?

- a. Chronic serous OM
- b. Herpes zoster infection
- c. Impacted earwax
- d. Perforation of eardrum
- e. Presbycusis

Ans. The key is B. Herpes zoster infection. [A case of Ramsay Hunt syndrome defined as an acute peripheral facial neuropathy associated with erythematous vesicular rash of the skin of the ear canal, auricle (also termed herpes zoster oticus), and/or mucous membrane of the oropharynx caused by Herpes zoster infection].

1047. An 8wk baby boy is noted to be jaundiced. He is breast-feeding well and has gained 300g since birth. His stools are yellow and his urine is pale straw colored. What is the most likely dx?

- a. Galactosemia
- b. Biliary atresia
- c. G6PD deficiency
- d. Breast milk jaundice
- e. Congenital viral infection

Ans. The key is A. Galactosemia. [Biliary atresia causes obstructive picture where stools are pale and urine becomes dark. Hemolytic disorder like G6PD or spherocytosis causes appearance of jaundice in 1st 24 hours. In breastmilk jaundice, jaundice develops in 2nd week. Also congenital viral infection (TORCH) occurs in 1st 24 hours. Here there is failure to thrive also. So likely cause in the presented case is Galactosemia].

1048. A lady developed breast abscess after delivery. What is the most likely organism?

- a. Staph aureus
- b. Staph albus
- c. GBS
- d. Strep pyogenes
- e. Strep faecalis

Ans. The key is A. Staphylococcus aureus.

1049. A 32yo man suffering from MS presents with blurring of vision. Ophthalmoscopy shows pallor of the optic disc. Which anatomical site is most likely to be affected?

- a. Optic nerve
- b. Optic disc
- c. Optic radiation
- d. Trigeminal
- e. Oculomotor nerve

Ans. The key is A. Optic nerve. [MS--optic neuropathy which affects optic nerve and long standing optic neuropathy can be seen as pallor of optic disc in ophthalmoscopy].

1050. A 23yo man presents with severe pain in the right flank radiating to his groin. He is rolling about on the floor. An IVU confirms a stone in the ureter which is 8mm in size. Which tx modality will be most effective?

- a. Fluids and alpha blockers
- b. ESWL
- c. CCB
- d. Dormier basket
- e. PCNL

Ans. The key is B. ESWL. [Though for 8 mm stone we can use medical expulsive therapy but for this patient with agonizing pain "most effective" therapy seems to be ESWL].

1051. A 37yo woman believes that her neighbours have been using her shower while she is away from home. Her 42yo partner is convinced about this and calls the police. What term best describes this situ?

- a. Capgras syndrome
- b. Cotard syndrome
- c. Delusion of persecution
- d. Folie a deux
- e. Munchausen syndrome

Ans. The key is D. Folie a deux. [Folie a deux is symptoms of a [delu-](#)

[sional](#) belief and [hallucinations](#) that are transmitted from one individual to another as here from wife to husband].

1052. A 45yo woman has dull pain in her right ear which has been present for several weeks. There is no discharge. Chewing is uncomfortable and her husband has noticed that she grinds her teeth during sleep. The eardrum appears normal. What is the single most likely dx?

- a. Dental caries
- b. Mumps
- c. OM
- d. Temporomandibular joint pain
- e. Trigeminal neuralgia

Ans. D. Temporomandibular joint pain. [Temporomandibular joint pain may cause pain in ear and teeth grinding is a recognized cause of this symptom].

1053. A 42yo lady had corrective surgery for cyanotic congenital heart disease at the age of 3y, after a palliative operation during infancy. There is a parasternal impulse and an early diastolic murmur. What is the most probable dx?

- a. Aortic regurgitation
- b. Ischemic mitral regurgitation
- c. Aortic stenosis
- d. Pulmonary stenosis
- e. Pulmonary regurgitation

Ans. The key is E. Pulmonary regurgitation. [In the present day, some patients with tetralogy of Fallot have survived for longer than 15-20 years after their first operation. The major problem encountered by these individuals is the development of pulmonary valvular regurgitation. It appears that a number of these individuals require pulmonary valve replacement (ref: Medscape)].

1054. A 45yo lady presents with hx of double vision and facial numbness. Which anatomical site is most likely to be affected?

- a. Cerebral cortex
- b. Trigeminal nerve
- c. Oculomotor nerve
- d. Brain stem
- e. Basal ganglia

Ans. The key is D. Brain stem. [Cerebral cortex will not cause features of cranial nerve lesions. Trigeminal nerve: ophthalmic and maxillary divisions are pure sensory hence it is also not the answer. Oculomotor

does not cause facial numbness. These features are not of basal ganglia lesion also. These features only can be explained by cranial nerve involvement in brainstem lesion].

1055. A 30yo woman has experienced restlessness, muscle tension and sleep disturbance on most days over the last 6m. She worries excessively about a number of everyday events and activities and is unable to control these feelings which are impairing her ability to hold down her job. What is the most likely dx?

- a. Panic disorder
- b. GAD
- c. Pheochromocytoma
- d. Acute stress disorder
- e. Social phobia

Ans. The key is B. GAD. [In GAD patient is worried about different number of events every day. Almost everything triggers the anxiety].

1056. Which of the following is not a degenerative corneal disease?

- a. Band keratopathy
- b. Marginal dystrophy
- c. Fatty/lipid degeneration
- d. Mooren's ulcer
- e. Keratoconus

Ans. The key is D. Mooren's ulcer. [All other options are degenerative disease of cornea except Mooren's ulcer which is a type of ulcerative keratitis].

1057. A 30yo man presents to hosp complaining that his urine has been very dark recently, resembling coffee at worst. He has been under the weather 2wks back and had taken a few days off work with a sore throat and coryzal symptoms. Urine dipstick in hosp returns highly positive for blood and protein. He is admitted for supportive management and is scheduled for a renal biopsy, which shows mesangial proliferation with a positive immune-fluorescence pattern. What is the most probable dx?

- a. Membranous glomerulonephropathy
- b. SLE
- c. Wegener's granulomatosis
- d. Post - strep GN
- e. IgA nephropathy

Ans. The key is D. Post- strep GN. [Nephritic picture, H/O sorethroat 2 weeks before presentation and biopsy reports are suggestive of post streptococcal glomerulonephritis].

1058. A 65yo lady presents with a 6h hx of facial droop and weakness in the left side of her body. What single agent will she be prescribed for her whole life?

- a. Clopidogrel
- b. Alteplase
- c. Aspirin
- d. Labetalol

Ans. The key is A. Clopidogrel. [For both TIA and stroke Clopidogrel is prescribed for life long if there are no drug allergies].

1059. A 10yo boy is brought to the hosp with a rash over his buttocks a/w abdominal pain and vomiting. In the ED, he is accompanied by his mother and stepfather. His mother had left him for the weekend with the stepfather and was called to come back from holiday as he started to have some hematuria with the rash. Social services had been notified on arrival to hospital. What is the most probable dx?

- a. NAI
- b. ITP
- c. HSP
- d. ALL
- e. HUS

Ans. The key is C. HSP. [Rash over buttock, abdominal pain and vomiting, blood in urine or stool suggest HSP].

1060. A man with hx of fall had confusion and laceration mark on the head. Which is the most appropriate vessel affected?

- a. Basilar artery
- b. Middle meningeal artery
- c. Vertebral artery
- d. Dural venous sinus

Ans. The key is B. Middle meningeal artery. [Considerable head injury and lucid interval (several episodes of transient confusion) points towards extradural hematoma which occurs frequently from bleeding from middle meningeal artery. Subdural hematoma usually occurs due to bleeding vein].

1061. A 72yo lady is drowsy and her relatives want to take her home. She has been prescribed diazepam 2.5mg. What is the best delivery route?

- a. Oral
- b. IV
- c. IM
- d. Per rectal
- e. SC

Ans. The key is D. Per rectal.

1062. A nonsmoker who has worked in coal mines for 20yrs presents with gradually increasing SOB, limited exercise tolerance and a dry cough. His CXR shows round fibrotic tissue demonstrating a mixed restrictive and obstructive ventilator defect with irreversible airflow limitation and reduced gas transfer. What is the single most appropriate dx?

- a. Churg-Strauss syndrome
- b. Cryptogenic organizing
- c. Extrinsic allergic alveolitis
- d. Goodpasture's syndrome
- e. Progressive massive fibrosis
- f. Molluscum

Ans. E. Progressive massive fibrosis. [Coal miners pneumoconiosis].

1063. A pt was complaining of pain within 6h after his appendectomy for gangrenous appendix. What med is the best option for his pain relief?

- a. IV morphine
- b. Diclofenac per rectal
- c. PCA
- d. Tramadol

Ans. The key is D. Tramadol.

1064. A 62yo farmer presents with a persistent firm irregular lesion on upper part of pinna which grew over the last few months. What is the most appropriate dx?

- a. Basal cell
- b. Squamous cell
- c. Keratoacanthoma

Ans. The key is A. Basal cell. [Any ulcer which is located above the neck is always basal cell carcinoma until proven otherwise. (samson

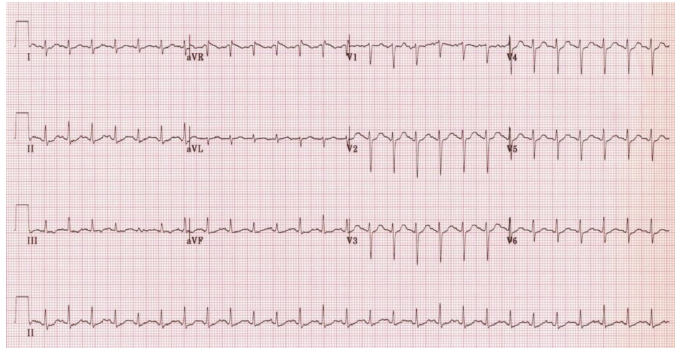
note)).

1065. A 24yo schizophrenic has been under antipsychotic tx for the last 1 yr and now complains of ED (Erectyl Dysfunction). Which drug is most likely to have caused this?

- a. Fluoxetine
- b. Citalopram
- c. Clozapine
- d. Haloperidol
- e. Risperidone

Ans. The key is D. Haloperidol. This is a wrong key. Correct key is E. Risperidone. [Haloperidol, raises serum prolactin levels to 20-40 ng/ml in therapeutic doses but risperidone causes around 171 ng/ml].

1066. What is the most likely dx based on this ECG



- a. Normal
- b. VT
- c. Sinus Tachycardia
- d. WPW syndrome
- e. A-fib

Ans. The key is C. Sinus Tachycardia.

1067. A 45yo woman has recently been dx with MS and has been started on oral steroids. She is brought to the hosp after having ingested 100 paracetamol tablets 4h ago. She is refusing all med tx. What is the next best step?

- a. Observe
- b. Refer to psychiatrist to assess pts ability to refuse tx
- c. Gastric lavage
- d. Activated charcoal
- e. Refer to social worker

Ans. The key is B. Refer to psychiatrist to assess pt's ability to refuse tx.

1068. A 44yo obese pt with findings: FBS=6mmol/l, OGTT=10mmol/l. What is the most likely dx?

- a. Impaired glucose tolerance
- b. Diabetes insipidus
- c. T1DM
- d. T2DM
- e. MODY

Ans. The key is A. Impaired glucose tolerance. [Impaired glucose tolerance is -2hours glucose level 199-140 mg/dl (7.8 to 11.0 mmol/l) on the -75g oral glucose tolerance test].

1069. A child distressed with fever, stridor and unable to swallow saliva. His RR=40bpm. What is the initial step that needs to be taken?

- a. Examine throat
- b. Secure airway
- c. Keep him laid flat
- d. IV penicillin

Ans. The key is B. Secure airway. [Probable epiglottitis. So airway should be secured].

1070. A pt presents with hemoptysis 7d after tonsillectomy and adenoidectomy. What is the next step of management?

- a. Explore again
- b. Pack it
- c. Oral antibiotics and discharge
- d. Admit and IV antibiotics
- e. Ice cream and cold fluid

Ans. The key is D. Admit and IV antibiotics. [secondary hemorrhage can occur due to infection causing sloughing out of part of arterial wall due to infection. It is managed by iv antibiotics following admitting the patient to hospital].

1071. A 55yo man presents with swelling at the angle of the mandible which is progressively increasing in size and it's mobile for 6m. What is the most probable dx?

- a. Benign parotid
- b. Mandible tumor
- c. Tonsillar carcinoma

Ans. The key is A. Benign parotid. [Mandibular tumour or tonsillar carcinoma would not be so mobile after such time period and Benign parotid is likely diagnosis].

1072. A 61yo man, known smoker, comes to the hospital with complaints of painless hematuria, urgency and dysuria. He has been worried about his loss of weight and reduced general activity. Which inv would be diagnostic of his condition?

- a. Urine microscopy
- b. IVU
- c. CT
- d. Cystoscopy
- e. US abdomen
- f. KUB
- g. Cystoscopy with biopsy
- h. Mid stream urine for culture
- i. Trans rectal US

Ans. The key is G. Cystoscopy with biopsy. [Painless hematuria in elderly man is due to Ca of bladder usually and in bladder cancer there are UTI like symptoms like urgency, dysuria. Also constitutional symptom like weight loss and reduced general activity is feature of carcinoma].

1073. An 8wk pregnant lady is brought to the ED due to severe vomiting. She was administered IV fluids and oral anti-emetics. She still can't tolerate anything orally. What is the next best tx?

- a. IV feeding
- b. IV antiemetics
- c. Termination of pregnancy
- d. PPI
- e. IV steroid

Ans. The key is IV antiemetics. [If oral antiemetics are not tolerated IV antiemetics are tried].

1074. A 48yo man presents with bone pain. Labs: ALP=high, phosphate=normal. What is the most likely dx?

- a. Osteoporosis
- b. Osteomalacia
- c. Paget's disease
- d. Fx
- e. Myeloma

Ans. The key is C. Paget's disease. [Bone pain, high ALP and normal phosphate are suggestive of paget's disease. In osteoporosis Ca⁺, PO₄^μ and ALP are normal. In osteomalacia Ca⁺ low, PO₄^μ low and ALP is high. In Paget's disease Ca⁺ and PO₄^μ normal and ALP markedly raised].

1075. A 54yo lady presents with sudden severe pain in the left half of her skull. She also complains of pain around her jaw. What is the most likely next step?

- a. CT
- b. MRI
- c. Fundoscopy
- d. ESR
- e. Temporal artery biopsy

Ans. The key is D. ESR. [Elderly lady with severe pain in the left half of her skull and pain around jaw is suspicious of Giant cell or Temporal arteritis. ESR if markedly raised supports the diagnosis of temporal arteritis].

1076. A 7yo school boy has been dx with meningococcal meningitis. What is the advice for schoolmates and staff?

- a. Rifampicin for the whole class and family
- b. Rifampicin for the whole school and family
- c. Meningococcal vaccine for the family
- d. Benzylpenicillin
- e. IV cefotaxime

Ans. The key is A. Rifampicin for the whole class and family. [In contacts of meningococcal meningitis chemoprophylaxis is given with Rifampicin].

1077. A pt came with dyskaryosis to the OPD. She is a heavy smoker and alcoholic. Cervical smear shows abnormal cells. What is the best advice for her?

- a. Colposcopy
- b. Biopsy
- c. Endocervical sample
- d. Repeat after 4m
- e. None
- f. Cone biopsy

Ans. The key is A. Colposcopy. [Patient with dyskaryosis should go for colposcopy].

1078. Pt with pain and swelling in left leg and thigh up to the level of inguinal ligament. Where is the level of occlusion?

- a. Femoro-popliteal artery
- b. Left common iliac artery
- c. Aortoiliac artery
- d. Femoral artery
- e. Profound femoral artery

Ans. There are two keys B. Left common iliac artery. and D. Femoral artery. Correct key is B. Left common iliac artery. [General rule is occlusion occurs in proximal bifurcation. So the correct key is B. Left common iliac artery. That is occlusion in the bifurcation of left common iliac artery (as femoral artery bifurcates more distally to superficial and deep branches)].

1079. A 65yo man presents with dyspnea 3d after an MI. On auscultation he has a pansystolic murmur at the apex radiating to the axilla. What is the most likely dx?

- a. Ruptured papillary muscle
- b. Ventricular aneurysm
- c. Pericarditis
- d. Pericardial effusion
- e. VSD

Ans. The key is A. Ruptured papillary muscle. [Pansystolic murmur in apex radiating to axilla may be due to mitral regurgitation secondary to papillary muscle rupture].

1080. A 64yo man with multiple myeloma has been vomiting since the past 2 days. Labs: Ca²⁺=3.2mmol/l, K⁺=5mmol/l, Na⁺=149mmol/l and PCV=55%. What is the most appropriate next step?

- a. IV insulin
- b. IV calcium gluconate
- c. IV fluids
- d. IV bisphosphonates
- e. Oral bisphosphonates

Ans. The key is C. IV fluids. [Multiple myeloma itself is a cause of vomiting and also associated hypercalcemia can cause sickness. As the patient is vomiting for 2 days there may be considerable dehydration and also the hypercalcemia needs treatment with IV fluid].

1081. A 30yo man from Australia returned from a business trip to Indonesia 6d ago presenting with complaints of fever, joint and muscle ache and headache, in particular behind the eye for the past 2 days. What is the most probable dx?

- a. Malaria
- b. Chicken pox
- c. TB
- d. Lyme's disease
- e. Dengue

Ans. The key is E. Dengue. [Fever, arthralgia, myalgia, headache these are common in dengue fever. Particularly retro-orbital pain is well recognized feature of dengue fever].

1082. A lady came for OBGYN assessment unit with hx of 8wk pregnancy and bleeding per vagina for last 2 days. On bimanual exam, uterus =8wks in size. On speculum exam, cervical os is closed. How do you confirm the viability of the fetus?

- a. Transvaginal US
- b. Serum BHCG
- c. Urinary BHCG
- d. Abdominal US
- e. Per speculum exam

Ans. The key is A. Transvaginal US. [Viability of the fetus is better assessed with transvaginal US. TVU can be done throughout pregnancy. It should be avoided once the membrane is ruptured to avoid chance of fetal infection].

1083. A 24yo lady has been low after the death of her husband and had stopped contacting her family. She was started on SSRI tx and starts feeling better after a few months. On discontinuating the meds she starts feeling that she has developed cancer just like her husband. What is the most appropriate next step?

- a. Continue SSRI
- b. Add TCA
- c. Neuropsychiatric analysis
- d. CBT
- e. Antipsychotics

Ans. The key is C. Neuropsychiatric analysis. This is wrong key. Correct key is A. [Continue SSRI. Such stopping of drug is not acceptable. Patients treated with fluoxetine for 12 weeks whose depressive symptoms remit should continue treatment with fluoxetine for at least an additional 26 weeks to minimize the risk of relapse].

1084. A 24yo male who is sexually active with other males with hx of discharge per urethra. Dx of chlamydia has been made. What is the possible complication if left untreated?

- a. Orchitis
- b. Balanitis
- c. Epididymo-orchitis
- d. Acute abdomen

Ans. The key is C. Epididymo-orchitis.

1085. A person doesn't go outside the home because he thinks that people will look at him and talk about him. He finds it difficult to associate with his peers in a restaurant or under social settings. What is the most likely dx?

- a. Agoraphobia
- b. GAD
- c. Panic disorder
- d. Adjustment disorder
- e. Social phobia

Ans. The key is E. Social phobia.

1086. A 63yo man presented with sudden onset of severe dyspnea, orthopnea, raised JVP and bilateral basal crackles 3d after an episode of MI. A dx of acute congestive cardiac failure was made and IV furosemide was started for this pt. What electrolyte abnormality is expected?

- a. High Na⁺, Low K⁺
- b. Low Na⁺, High K⁺
- c. Low Na⁺, Low K⁺
- d. High Na⁺, High K⁺
- e. Low Na⁺, Normal K⁺

Ans. The key is C. Low Na⁺, Low K⁺. [Furosemide causes hyponatremia, hypochloremic alkalosis, hypokalemia, hypomagnesemia and hypocalcemia].

1087. A 70yo hypertensive white british man on thiazide diuretics needs a 2nd drug to control his BP. Which one of the following is the best choice for him?

- a. Amlodipine (CCB)
- b. Enalapril (ACEi)
- c. Propranolol (BB)
- d. Increase dose of diuretic
- e. Prazocin (Alpha blocker)

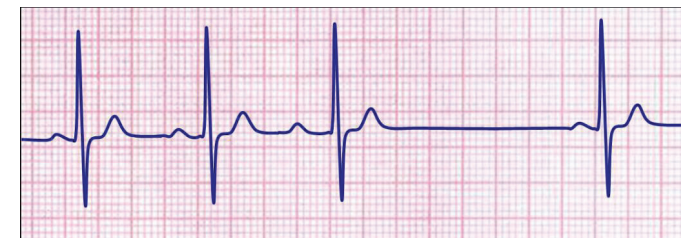Ans. The key is B. Enalapril. [In patients >55 yrs CCB. If CCB not suitable (oedema, heart failure) thiazide is preferred. In patients <55yrs ACEI or ARB. Now if patient is on CCB or Thiazide and 2nd drug is to be added it should be one of ACEI or ARB and not one from CCB or Thiazide].

1088. A 74yo lady who has had a stroke in the past has an indwelling catheter for 10m. She presents with bluish-purple discoloration of the catheter bag. What is the most likely explanation for this?

- a. Normal change
- b. Catheter degradation
- c. Acidic urine
- d. Alkaline urine
- e. Bacterial colonization of the urinary tract

Ans. The key is E. Bacterial colonization of the urinary tract. [Purple Urine Bag Syndrome].

1089. A 62yo man has slow palpitations and the following ECG. What is the most likely dx?



- a. Sinus bradycardia
- b. 1st degree heart block
- c. Mobitz type 1 block
- d. Mobitz type 2 block
- e. Complete heart block

Ans. The key is C. Mobitz type 1 block. [Gradual prolongation of PR interval followed by a drop beat].

1090. A 29yo woman presents with lid lag, lid retraction and diplopia. What is the most appropriate next step?

- a. TFT
- b. Tensilon test
- c. Fundoscopy
- d. Autoantibodies
- e. EMG

Ans. The key is A. TFT. [Features are suggestive of Grave's disease hence TFT].

1091. A 41yo man presents with longstanding foul smelling ear discharge and progressive hearing loss. Otoscopy showed perforation of the pars flacida and a mass in the upper part of the middle ear. What is the most likely dx?

- a. ASOM
- b. CSOM
- c. Acquired cholesteatoma
- d. Congenital cholesteatoma
- e. Barotrauma

Ans. The key is C. Acquired cholesteatoma. [In congenital cholesteatoma there is usually no perforation. In acquired cholesteatoma perforation is in pars flaccida].

1092. A 9yo child presented with a rash on his skin which didn't respond to antibacterial ointment. What med should be added next?

- a. Corticosteroid
- b. Antifungal
- c. Emollient
- d. Permethrin
- e. Coal tar

Ans. The key is B. Antifungal. [If a lesion is suspected to be infected should be given antibiotic, but if no response next step is to add an antifungal].

1093. A young boy has a hx of epistaxis. CBC=normal, except APTT=47s. What is the most likely dx?

- a. Hemophilia
- b. ITP
- c. Sick cell
- d. HUS
- e. Thalassemia

Ans. The key is A. Hemophilia. [A young boy with epistaxis and prolonged APTT is a probable case of hemophilia. Factor VIII and IX should be offered to confirm the diagnosis].

1094. A 29yo young man presents with complaints of recurrent attacks of diarrhea. He says his stools contain blood and mucus. Sometimes he has low grade fever. What is the most appropriate inv for his condition?

- a. Stool culture
- b. Plain abdominal XR
- c. Per rectal exam
- d. Barium enema

Ans. The key is D. Barium enema. [Features are suggestive of IBD, so barium enema is the most relevant investigation among the given options].

1095. A 26yo young man presents with hx of passing loose stools for the past 2m. He says his stools contain blood and mucus and are a/w abdominal pain. He undergoes a colonoscopy after which he was started on tx. What is the most appropriate tx for his condition?

- a. Mesalazine
- b. Corticosteroids
- c. Infliximab
- d. Cyclosporine

Ans. The key is A. Mesalazine. [Features and tx after colonoscopy suggests dx of ulcerative colitis for which initial treatment option is mesalazine].

1096. A 52 yo male with poorly controlled DM has now presented to his GP with pain in the ear. Exam: skin around the ear is black in color and there was foul smelling discharge from the ear. Pt also had conductive hearing loss. What is the most probable dx?

- a. Carbuncle
- b. Folliculitis
- c. Malignant OE
- d. Cholesteatoma
- e. Furuncle

Ans. The key is C. Malignant OE. [In some cases, otitis externa can spread to the outer ear and surrounding tissue, including the bones of the jaw and face. This infection is known as malignant otitis externa. Though the term malignant is used it is not a cancer].

1097. A 55yo male has been admitted for elective herniorrhaphy. Which among the following can be the reason to delay his surgery?

- a. Controlled asthma
- b. Controlled A-fib
- c. DVT 2yrs ago
- d. DBP 90mmHg
- e. MI 2m ago

Ans. The key is E. MI 2m ago. [Following MI at least 6 months should be elapsed for elective operation. Prior this time surgery is associated with increased mortality].

1098. A 21yo female in her first pregnancy at 38wks was brought to the ED with generalized tonic clonic seizure. IV MgSO₄ was given but fits was not controlled. She is having fits again. What is the single most imp immediate management of this pt?

- a. IV MgSO₄
- b. IV diazepam
- c. Immediate C-section
- d. IV phenytoin
- e. MgSO₄ bolus
- f. IV lorazepam

Ans. The key is A. IV MgSO₄. It is a wrong key! Correct key is E. MgSO₄ bolus. [Treat a first seizure with 4g magnesium sulfate in 100mL 0.9% saline IVI over 5min + maintenance IVI of 1g/h for 24h. Beware of hyperventilation. If recurrent seizure give 2g IVI magnesium sulfate over 5 min. Check tendon reflexes and respiratory rate every 15min. Stop magnesium sulfate IVI if respiratory rate <14/min or tendon reflex loss, or urine output <20mL/h. Have IV calcium gluconate ready in case of MgSO₄ toxicity: 1g (10mL) over 10 min if respiratory depression. Use diazepam once if fits continue (eg 5-10mg slowly IV). If seizures

continue, ventilate and consider other causes (consider CT scan). OHCS, 9th edition, page49-].

1099. A 24yo lady with BMI=30 complains of facial hair growth and hx of amenorrhea. FSH=10.9, prolactin=400IU, estradiol=177.8mmol/l, progesterone=normal, LH=33.2. What is the most probable dx?

- a. PCOS
- b. Pregnancy
- c. Cushing's disease
- d. CAH
- e. POF

Ans. The key is A. PCOS. [Clinical features (obesity, hirsutism, amenorrhea etc.) are consistent with PCOS. We know in PCOS LH:FSH ratio is 2:1 or 3:1. Here LH is 33.2 and FSH is 10.9 which also supports diagnosis of PCOS].

1100. A 17yo girl with a lump in her breast was seen in the clinic. Exam: the lump was free and mobile and not attached to the skin. Her mother wants further tests done. What should be the next step?

- a. CT
- b. US breast
- c. Punch biopsy
- d. Reassure and send home
- e. Stereotactic biopsy

Ans. The key is B. US breast. [Described lump is fibroadenoma. Next investigation is either US breast (for women under 35 yrs) or mammography (for women over 35 yrs)].

1101. A lady comes with a missing IUCD thread. Her LMP was 2wks ago. What is the single most appropriate next step in management?

- a. Abdominal US
- b. Prescribe contraceptives
- c. CT
- d. Serum BHCG
- e. Vaginal exam

Ans. The key is A. Abdominal US. It is wrong key! Correct key is E. Vaginal exam. [LOST THREAD: First confirm the thread is not in position by vaginal examination. If not present ultrasound should be arranged to locate the device. If ultrasound does not locate the device and there is no definite history of expulsion then abdominal X-ray should be performed to look for

an extrauterine device. Expulsion should not otherwise be assumed. Hysteroscopy can be helpful if ultrasound is equivocal. Surgical retrieval of an extrauterine device is advised].

1102. A 32yo woman presents with hx of lower abdominal pain and vaginal discharge. She had her menses 4wk ago. She has a temp of 38.6C. What is the most suitable dx?

- a. Acute appendicitis
- b. Acute PID
- c. Endometriosis
- d. Ectopic pregnancy
- e. UTI

Ans. The key is B. Acute PID. [Fever, lower abdominal pain and vaginal discharge are features of PID].

1103. A 40yo female was on COCP which she stopped 6m ago. But she has not had her periods since then. Labs: FSH=22, LH=24, prolactin=700, estradiol=80. What is the most appropriate dx?

- a. Hypothalamic amenorrhea
- b. Post pill amenorrhea
- c. Prolactinoma
- d. Pregnancy
- e. Premature ovarian failure

Ans. The key is E. Premature ovarian failure. [FSH and LH are raised in ovarian failure; an FSH level ≥ 20 IU/l in a woman aged around 40 with secondary amenorrhoea indicates ovarian failure. In POF there is also a mild to moderate rise in prolactin].

1104. A 25yo woman presents with a single lump in the breast and axilla. The lump is mobile and hard in consistency. The US, mammogram and FNA turn out to be normal. What is the most appropriate inv to confirm the dx?

- a. FNAC
- b. MRI
- c. Punch biopsy
- d. Genetic testing and counselling
- e. Core biopsy

Ans. The key is E. Core biopsy. [The lump is suspicious but US, mammogram and FNA turn out to be normal. So most appropriate investigation to confirm diagnosis is core biopsy. It is often the preferred biopsy method because it is accurate and does not involve surgery].

1105. A 37yo lady stopped taking COCP 18m ago and she had amenorrhea for 12m duration. Labs: FSH=8, LH=7, prolactin=400, estradiol=500. What is the cause?

- a. Hypothalamic amenorrhea
- b. PCOS
- c. Prolactinoma
- d. Post pill amenorrhea
- e. POF

Ans. The key is D. Post pill amenorrhea. [Post pill amenorrhea= failure to resume menses within 6 months of stopping pill, she was amenorrheic for 12 months].

1106. A lady with a firm smooth breast lump in outer quadrant had a FNAC done. Results showed borderline benign changes. She also has a fam hx of breast cancer. What is the your next?

- a. Mammography
- b. US
- c. Core biopsy
- d. Genetic testing and counselling
- e. Punch biopsy

Ans. The key is D. Genetic testing and counselling. Probably wrong key! Correct one should be C. Core biopsy. [Genetic testing is done for asymptomatic patients in their 30s and if positive SERMs are given which cause significant reduction in cancer. Since patient has firm breast lump in upper outer quadrant (most common location for cancer) and FNAC has shown borderline benign changes plus patient is high risk for cancer, so we must go for core biopsy to confirm whether it is cancer or not].

1107. A pt presents with mild dyskaryosis. 1y ago smear was normal. What is the most appropriate next step?

- a. Cauterization
- b. Repeat smear
- c. Swab and culture
- d. Cone biopsy
- e. Colposcopy

Ans. The key is E. Colposcopy. [In mild dyskaryosis colposcopy should be done with HPV test].

1108. An African lady presents with heavy but regular periods. Her uterine size correlates to 14wks pregnancy. What is the most appropriate dx?

- a. Blood dyscrasia
- b. Hematoma
- c. Fibroids
- d. Adenomyosis
- e. Incomplete abortion

Ans. The key is C. Fibroids. [Regular heavy menstruation in a uterus of 14 wk size is highly suggestive of fibroid].

1109. A 29yo at 38wks GA presents with a 2h hx of constant abdominal pain. She then passes 100ml of blood per vagina. What is the next appropriate inv?

- a. USS
- b. CTG
- c. Clotting screen
- d. Hgb
- e. Kleihauer Betke test

Ans. The key is A. USS. [Ultrasonogram scan can detect placental abruption and fetal heart beat as well. So it is the preferred key over CTG].

1110. A 26yo woman had amenorrhea for 10wks and is pregnant. She experiences hyperemesis. Now she presents with vaginal bleed. Exam: uterus=16wks, closed os. What is the most probable dx?

- a. Thyrotoxicosis
- b. Hyperemesis gravidarum
- c. Twins
- d. Wrong dates
- e. Molar pregnancy

Ans. The key is E. Molar pregnancy. [In hydatidiform mole uterus becomes more in size than actual gestational age and due to production of large amount of gonadotrophin by moles patient suffers from severe vomiting i.e. hyperemesis. There also occurs vaginal bleeding].

1111. A pregnant woman of G2, GA 11wks presents with heavy vomiting, headache and reduced urine output. Urine analysis shows ketonuria. Choose the next best step?

- a. US
- b. Oral fluid replacement
- c. Serum BHCG
- d. Parental anti-emetics
- e. IV fluids

Ans. The key is E. IV fluids. [Hyperemesis gravidarum with oliguria and ketonuria. IV fluid should be started to prevent renal failure].

1112. A pt had inflammatory changes on cervical smear. There is no vaginal discharge, no pelvic pain and no fever. What is the next step?

- a. Repeat smear in 6m
- b. Take swab
- c. Treat with antibiotics
- d. Colposcopy
- e. Cone biopsy

Ans. The key is B. Take swab. This is a wrong key! Correct key is A. Repeat smear in 6 months. [Ref: Samson notes].

1113. A 37yo infertile lady with 5cm subserosal and 3cm submucosal fibroid is trying to get pregnant. Which is the most suitable option?

- a. Clomifen therapy
- b. IVF
- c. Myomectomy
- d. Hysterectomy
- e. IU insemination

Ans. The key is C. Myomectomy. [Fibroids are preventing from her being pregnant. So myomectomy is the most suitable option to let her get pregnant].

1114. A young tall man and his wife are trying for babies and present at the infertility clinic. On inv the man has primary infertility and azoospermia. What other inv should be done?

- a. Testosterone
- b. LSH
- c. FSH
- d. Estradiol
- e. Karyotyping

Ans. The key is E. Karyotyping. [The likely diagnosis is Klinefelter's

syndrome for which Karyotyping should be done to make the diagnosis established].

1115. A woman who is on regular COCP presented to you for advice on what to do as she has to now start to take a course of 7d antibiotics. What would you advice?

- a. Continue regular COC
- b. Continue COCP and backup contraception using condoms for 2d
- c. Continue COCP and backup contraception using condoms for 7d
- d. Continue COCP and backup contraception using condoms for 2wks

Ans. The key is D. Continue COCP and backup contraception using condoms for 2wks. This is wrong key! Correct key should be A. Continue regular COCP. [Before it was thought that antibiotics alter the gut flora and ethinyloestradiol is not conjugated. There is more ethinyloestradiol passed in the stool. So pregnancy and breakthrough bleeding can occur. But later it was established that except for strong enzyme inducer like Rifampicin and Rifabutin other antibiotics practically does not reduce potency of COCP and hence except only rifampicin or rifabutin for other antibiotics no additional precautions are needed].

1116. A lady presents with hot flashes and other symptoms of menopause. What is the tx option?

- a. Raloxifen
- b. HRT
- c. Bisphosphonate
- d. COCP
- e. Topical estrogen

Ans. The key is B. HRT

1117. A 28yo woman at 34wks GA for her first pregnancy attends antenatal clinic. Her blood results: Hgb=10.6, MCV=95, MCHC=350. What do you do for her?

- a. Folate
- b. Dextran
- c. Ferrous sulphate
- d. None
- e. IV FeSO₄
- f. Explain this physiologic hemodynamic anemia
- g. Blood transfusion

Ans. The key is F. Explain this physiologic hemodynamic anemia. [According to NICE, cut offs for iron supplements:

at booking (8-10 weeks)- if less than 11
at 28 weeks and further- if less than 10.5
if less than these values=> give iron].

1118. A 34yo woman who never had fits or high BP developed fits 6h after delivery of a term healthy child. What is the most likely dx?

- a. Eclampsia
- b. Preeclampsia
- c. Epilepsy
- d. Pulmonary embolism
- e. Pregnancy induced HTN

Ans. The key is A. Eclampsia. [In eclampsia seizures occurs within 24 hours mostly and majority within 12 hours. Also single seizure doesn't support epilepsy strongly. So likely answer is A. Eclampsia].

1119. A 30yo lady who already has one child through a prv C-section demands a reversible contraception. She presently experiences heavy and painful periods. What is the most appropriate contraceptive you will recommend for her?

- a. COCP
- b. POP
- c. Implanon
- d. Danazol
- e. Mirena
- f. IUCD

Ans. The key is E. Mirena.

1120. A 32yo woman comes with intermenstrual bleeding. Her last cervical smear was 1y ago and was negative. What test would you recommend for her initially?

- a. Colposcopy
- b. Cervical smear
- c. Endocervical swab
- d. Transvaginal US
- e. Pelvic CT

Ans. The key is B. Cervical smear. This is a wrong key! Correct key is C. Endocervical swab. [Smear can only be done if it is due or overdue, not in any time or not as needed basis. Here patients next smear will be due after 2 more years].

1121. A 20yo woman has had abdominal pain in the LIF for 6wks duration. Over the past 48h, she has severe abdominal pain and has a fever of 39.1C. Pelvic US shows a complex cystic 7cm mass in the LIF. What is the most likely dx?

- a. Endometriosis
- b. Dermoid cyst
- c. Ovarian ca
- d. Tubo-ovarian abscess
- e. Ectopic pregnancy

Ans. The key is D. Tubo-ovarian abscess.

1122. A woman is 16wk pregnant and she is worried about abnormal chromosomal anomaly in her child. What is the definitive inv at this stage?

- a. Amniocentesis
- b. CVS (Chorionic Villous Sampling)
- c. Parents karyotyping
- d. Coomb's test
- e. Pre-implantation genetic dx

Ans. The key is A. Amniocentesis. [Amniocentesis is done between 14 to 16 weeks of gestation. CVS is done prior to 15 weeks. So the option is A. Amniocentesis].

1123. A 28yo lady with a fam hx of CF comes for genetic counselling and wants the earliest possible dx test for CF for the baby she is planning. She is not in favor of termination. What would you recommend for her?

- a. CVS (Chorionic Villous Sampling)
- b. Amniocentesis
- c. Pre-implantation genetic dx
- d. Chromosomal karyotyping
- e. Maternal serum test
- f. Reassure

Ans. C. Pre-implantation genetic dx. [Patient is not yet pregnant but planning for pregnancy. Earliest possible diagnostic test for CF is Pre-implantation genetic dx. Preimplantation genetic diagnosis (PGD) is a procedure used prior to implantation to help identify genetic defects within embryos created through in vitro fertilization to prevent certain diseases or disorders from being passed on to the child].

1124. A 39yo woman in her 36th week GA with acute abdominal pain is rushed for immediate delivery. Her report: BP=110/60mmHg, Hgb=low, bilirubin=22, AST=35, Plt=60, APTT=60, PT=30, Fibrinogen=0.6. What is the cause?

- a. Pregnancy induced hypertension
- b. DIC
- c. HELLP syndrome
- d. Acute fatty liver
- e. Obstetric cholestasis

Ans. The key is B. DIC. [It is not HELLP syndrome as liver enzyme is not elevated. Acute abdominal pain may indicate concealed abruption placenta which may lead to DIC].

1125. A 36wk pregnant woman presents with sudden onset of uterine pain and bleeding, uterus is tender, no prv LSCS. What is the most appropriate cause?

- a. Preeclampsia
- b. DIC
- c. Placental abruption
- d. Placental previa
- e. Ectopic pregnancy
- f. Missed abortion
- g. Ectropion

Ans. The key is C. Placental abruption. [Painful bleeding at 36th week is placental abruption (either revealed or mixed type)].

1126. A 28wk pregnant woman presents with uterine bleeding after sexual intercourse. What is the most appropriate cause?

- a. Preeclampsia
- b. DIC
- c. Placental abruption
- d. Placental previa
- e. Ectopic pregnancy
- f. Missed abortion
- g. Ectropion

Ans. The key is G. Ectropion. [Post coital bleeding can be either placenta previa or cervical ectropion. But as ectropion is commoner in pregnancy so it is the option here].

1127. A 6wk pregnant woman presents with abdominal pain. She has prv hx of PID. What is the most likely dx?

- a. Preeclampsia
- b. DIC
- c. Placental abruption
- d. Placental previa
- e. Ectopic pregnancy
- f. Missed abortion
- g. Ectropion

Ans. The key is E. Ectopic pregnancy. [H/O PID is a recognized cause of ectopic pregnancy. Also pain without bleeding at 6th week support the diagnosis of ectopic pregnancy].

1128. A 33wk pregnant woman presents with vaginal bleeding, low Hgb, low plt, increased bilirubin, AST normal, APTT & PT increased. What is the most likely dx?

- a. Preeclampsia
- b. DIC
- c. Placental abruption
- d. Placental previa
- e. Ectopic pregnancy
- f. Missed abortion
- g. Ectropion

Ans. The key is B. DIC.

1129. A 25yo lady at her 28th week GA came for check up. Her BP=160/95mmHg, protein in urine=6g/d. What is the most likely dx?

- a. Essential HTN
- b. Gestational HTN
- c. Chronic HTN
- d. Preeclampsia

Ans. The key is D. Preeclampsia.

1130. A 32yo woman has a hx of spontaneous abortions at 6wks, 12wks, and 20wks. She is now keen to conceive again. Which of the following would you prescribe for the next pregnancy?

- a. MgSO₄
- b. Aspirin
- c. Warfarin
- d. Mefenemic acid
- e. Heparin

Ans. The key is B. Aspirin. [Patient of antiphospholipid syndrome had 3 fetal losses and no thromboembolic event and now wants to be pregnant. In such case prophylactic treatment with low dose aspirin is indicated].

1131. A 6yo child presents with hx of recurrent jaundice. Between the episodes he is totally fine. Mother gives hx of jaundice being brought about by ongoing infections. What is the most likely dx?

- a. Hereditary spherocytosis
- b. G6PD deficiency
- c. Thalassemia
- d. Sick cell disease
- e. Congenital storage disorder

Ans. The key is B. G6PD deficiency. [There are some precipitating factors of hemolysis causing jaundice in patients with G6PD deficiency among which infection is a recognized one].

1132. A 42yo woman who smokes 20 cigarettes/d presents with complains of heavy bleeding and prolonged menstrual period. What is the most appropriate tx for her?

- a. Tranexemic acid
- b. COCP
- c. Mefenemic acid
- d. IUCD
- e. Norethisterone

Ans. The key is D. IUCD. This is wrong key. Correct key is A. Tranexemic acid.

1133. A 17yo senior school girl with complain of prolonged irregular menstrual period and heavy blood losses. What is the most appropriate tx for her?

- a. Mefenemic acid
- b. COCP
- c. POP
- d. IUCD
- e. Mirena

Ans. The key is B. COCP. [In irregular period: COCP except the contraindications for it and in that case POP should be used].

1134. A 32yo presents with heavy blood loss, US: uterine thickness>14mm. What is the most appropriate tx for her?

- a. Mefenemic acid
- b. COCP
- c. POP
- d. IUCD
- e. IU system (mirena)

Ans. The key is E. IU system (mirena). [Simple endometrial hyperplasia without atypia responds to high-dose progestogens, with repeat histology after three months. This can be effectively delivered by the levonorgestrel [intrauterine system \(IUS\)](#). Source: patient.info].

1135. A 37yo woman presents with heavy bleeding. Inv show subserosal fibroid=4cm and intramural fibroid=6cm. Which is the most appropriate tx?

- a. UAE
- b. Abdominal hysterectomy
- c. Hysteroscopic Myomectomy
- d. Vaginal Hysterectomy
- e. Abdominal myomectomy

Ans. The key is E. Abdominal myomectomy. [As patient is young we should go for myomectomy. As hysteroscopic myomectomy is suitable for mainly submucosal fibroids. We should go for Abdominal myomectomy which will deal with both subserosal and intramural fibroids].

1136. A woman with sickle cell disease complains of heavy menstrual blood loss. What is the most appropriate tx?

- a. COCP
- b. Mirena
- c. Depot provera
- d. Copper IUS
- e. Transdermal patch

Ans. The key is C. Depot provera. [Hormone and barrier methods are all acceptable choices but intrauterine devices are not recommended, as they may be associated with uterine bleeding and infection. Depot contraceptive (Depo-Provera®) is safe and has been found to improve the blood picture and reduce pain crises. Source: patient.info].

1137. A 70yo woman is admitted with diarrhea, vomiting and dehydration. Exam: yellow visual halos in her eyes, ECG=bradycardia. She has a hx of chronic A-fib. Which drug causes the above mentioned side effects?

- a. Nifedipine
- b. Ramipril
- c. Atenolol
- d. Lithium
- e. Digoxin

Ans. The key is E. Digoxin. [Digoxin toxicity causes diarrhea, vomiting, dehydration, xanthopsia (yellow halos around light), bradycardia. History of atrial fibrillation is also a clue of digoxin use].

1138. A 33yo lady who is a drug addict wants to quit. She says she is ready to stop the drug abuse. She is supported by her friends and family. What drug tx would you give her?

- a. Benzodiazepines
- b. Diazipoxide
- c. Lithium
- d. Methadone
- e. Disulfiram

Ans. The key is D. Methadone. [Methadone is an opioid medication. Methadone reduces withdrawal symptoms in people addicted to heroin or other narcotic drugs without causing the "high" associated with the drug addiction and thus used to help a drug addict to quit from drug addiction].

1139. A 50yo lady has been suffering from chronic RA and is on methotrexate and naproxen. Her CBC shows microcytic anemia. What is the most likely cause?

- a. Anemia of chronic disease
- b. GI hemorrhage
- c. Menorrhagia

Ans. The key is B. GI hemorrhage. [Anemia of chronic disease is mostly normocytic and methotrexate causes folate deficiency which may lead to macrocytosis. So for this microcytic anemia NSAIDs induced GI hemorrhage is the most likely cause].

1140. A 15yo male noticed swelling on the left knee following a fall while playing. The swelling has not subsided in spite of rest and analgesia. Exam: full knee movement with slight tenderness. He has painless palpable mass in left inguinal region. What is the most probable dx?

- a. Osteosarcoma
- b. Ewing's sarcoma
- c. Chondrosarcoma
- d. Lymphangiosarcoma
- e. Osteodosteoma

Ans. There are two keys i) Osteosarcoma ii) Ewing's sarcoma. But the likely correct key is probably A. Osteosarcoma. [Both occurs in children and young adults but the occurrence of painful symptom during playing is usually a feature of osteosarcoma. In case of osteosarcoma teenagers who are active in sports often complain of pain in the lower femur, or immediately below the knee. If the tumor is large, it can present as overt localised swelling. Sometimes a sudden fracture is the first symptom, because affected bone is not as strong as normal bone and may fracture abnormally with minor trauma].

1141. A 45yo female looking pale has bluish discoloration of hands whenever she goes out in the cold. She has also noticed some red-dish spots on her body. She has symmetrical peripheral arthropathy for the last yr. What is the most probable dx?

- a. RA
- b. Osteosarcoma
- c. Limited systemic sclerosis
- d. Diffuse systemic sclerosis
- e. Chondrosarcoma

Ans. The key is C. Limited systemic sclerosis. [Raynaud's phenomena, telangiectasia, sclerodactyly indicates to the dx of CREST syndrome or Limited systemic sclerosis].

1142. A 60yo female has pain and stiffness in her right hip joint. Pain is not severe in the morning but increases as the day progresses. She has noticed some nodules in her hands. Inv: Hgb=low. What is the most probable dx?

- a. RA
- b. Osteoarthritis
- c. Gout
- d. Pseudogout
- e. Multiple myeloma

Ans. The key is B. Osteoarthritis. [Stiffness and pain of right hip increasing as the day progresses, nodules in hands (Heberden or

Bouchard's nodes), anemia (probably secondary to prolonged NSAIDs use) indicates osteoarthritis].

1143. A 30yo female has chronic diarrhea, mouth ulcers and skin tags. She complains of visual prbs, low back pain and morning stiffness. Inv: ESR & CRP=raised, Hgb=10mg/dl. What is the most probable dx?

- a. SLE
- b. Reactive Arthritis
- c. Gout
- d. Pseudogout
- e. Seronegative arthritis

Ans. The key is E. Seronegative arthritis. [Chronic diarrhea, mouth ulcers and skin tags are features of IBD. There is a well known association between IBD and seronegative arthritis (particularly AS). Here low back pain, visual problem, morning stiffness, raised ESR and CRP, low hemoglobin indicates the diagnosis of Seronegative arthritis].

1144. A 28yo woman has been on tx for RA for 3yrs. She has gradual loss of vision in both eyes. Her IOP is normal. Red reflex is absent in both eyes. What is the single most likely dx?

- a. Cataract
- b. DM retinopathy
- c. Hypermetropia
- d. Macular degeneration
- e. HTN retinopathy

Ans. The key is A. Cataract. [Prolonged use of steroid (here in RA) is a known cause of cataract].

1145. An elderly man with recently dx HF has been treated with diuretics. He now develops severe joint pain in his left ankle with swelling and redness. What is single most likely inv?

- a. XR of bone
- b. Plasma RF
- c. Joint fluid uric acid crystals
- d. ESR

Ans. The key is B. Plasma RF. It is a wrong key. Correct key should be C. Joint fluid uric acid crystals. [Thiazide diuretics may increase uric acid levels in blood causing or precipitating gout and joint fluid may show uric acid crystals].

1146. A 60yo lady with a hx of HTN and suffering from RA since the last 10y now presents with hot, swollen and tender knee joint. What inv would you do for her?

- a. XR
- b. C&S of joint aspirate
- c. US
- d. MRI
- e. CT

Ans. The key is B. C&S of joint aspirate. [RA itself is a risk factor for joint infection and there are possibilities to increase the chance of septic arthritis with the use of probable steroid which lowers immunity and further facilitates infection of joints for which C&S of joint aspirate should be done].

1147. A 34yo man after an RTA was brought to the ED. He has BP=50/0mmHg and chest wall with asymmetrical movement, RR=34bpm. What would be the initial action?

- a. IV fluid infusion
- b. Intubation and ventilation
- c. CT chest
- d. Transfer to ITU

Ans. The key is B. Intubation and ventilation.

1148. A 7yo presented with chronic cough and is also found to be jaundiced on exam. What is the most likely dx?

- a. Congenital diaphragmatic hernia
- b. Congenital cystic adenomatoid malformation
- c. Bronchiolitis
- d. RDS
- e. Alpha 1 antitrypsin deficiency

Ans. The key is E. Alpha 1 antitrypsin deficiency. [In those with unexplained liver disease with or without respiratory symptoms should be evaluated for AATD].

1149. A 65yo man had a bowel resection 5d ago. He is anuric and breathless. His BP=150/110mmHg. He has crackles at both lung bases and sacral edema. Bloods: K+=6.8mmol/l, urea=58mmol/l, creatinine=600umol/l. What is the single most appropriate immediate management?

- a. Bolus of 20U insulin
- b. Calcium resonium enema
- c. Dextrose-saline infusion
- d. 5% dextrose infusion
- e. 10U insulin, 50ml of 50% dextrose infusion

Ans. The key is E. 10U insulin, 50ml of 50% dextrose infusion. [There is renal failure with hyperkalemia. First we have to save heart from arrest or life threatening arrhythmia by shifting K+ into cell. 10U insulin in 50 ml 50% dextrose will help doing this].

1150. A 25yo woman presents with a painful shallow ulcer on the vulva. What inv has to be done?

- a. HSV antibodies
- b. Syphilis serology
- c. Swab for hemophilus ducreyi
- d. Urine culture
- e. Blood culture

Ans. The key is C. Swab for hemophilus ducreyi. [Herpes simplex virus causes multiple painful vesicles and syphilis ulcer is painless. As here single painful ulcer probable dx is Chancroid caused by Hemophilus ducreyi].

1151. A child was admitted with fever, generalized skin lesion, some of them are weeping lesions and some of them are crusted. What is the most probable dx?

- a. Varicella
- b. Impetigo
- c. Drug reaction
- d. Contact dermatitis
- e. Scabies

Ans. The key is B. Impetigo. This is probably a wrong key! Likely correct key should be A. Varicella. [Please consider dx of impetigo if specifically mention honey (or yellow or golden) coloured lesion or distribution described to be on face and limbs predominately. Otherwise consider chickenpox. Though key is impetigo here, it is wrong key. Likely correct option here is varicella].

1152. A pt comes with 6m hx of painless bilateral swelling of the face which has been progressively increasing in size. On routine CXR, he is found to have perihilar lymphadenopathy. What is the most probable dx?

- a. Chronic sialadenitis
- b. Thyroid adenoma
- c. Carcinoma of salivary gland
- d. Adenoid cystic carcinoma
- e. Mikulicz's disease

Ans. The key is E. Mikulicz's disease. [Mikulicz's disease (MD) is a well-known disorder characterized by enlarged lacrimal and parotid glands caused by infiltration with lymphocytes. When no specific cause is found it is called Mikulicz's disease; and if secondary to disease like sarcoidosis it is termed as Mikulicz's syndrome].

1153. A woman has widespread metastasis from a carcinoma. She presented with severe back pain. Where do you expect the cancer to be?

- a. Lungs
- b. Cervix
- c. Ovary
- d. Uterus
- e. Breast

Ans. The key is E. Breast. [In female breast and lung cancer and in male prostate and lung cancer are most common to metastasize to bone].

1154. A 10yo child has got progressive bilateral hearing loss. He has started to increase the TV volume. All other examination is normal. What is the most likely dx?

- a. Wax
- b. Foreign body
- c. Bilateral OM with effusion
- d. SNHL
- e. Meningitis due to meningococcus

Ans. The key is C. Bilateral OM with effusion.

1155. A child had a patchy rash following tx for sore throat & cervical LN enlargement. Which is the most appropriate antibiotic?

- a. Ampicillin
- b. Erythromycin
- c. Cefuroxime
- d. Metronidazole
- e. Tetracycline

Ans. The key is A. Ampicillin. [Infectious mononucleosis can present with sorethroat and lymphadenopathy like tonsillitis and if treated with ampicillin leads to eruption of patchy rashes].

1156. A child with a hx of asthma is brought to ED with a cut on knee and sprained on her left wrist. Which is the best analgesic for her?

- a. Paracetamol
- b. NSAIDs
- c. Cocodamol
- d. Ibuprofen

Ans. The key is A. Paracetamol. [NSAIDs including ibuprofen can precipitate asthma and Cocodamol is also advised to avoid in asthma (due to its codeine content). So paracetamol is the best option here].

1157. A 15m baby girl presented to the ED with difficulty in breathing. Exam: she has intercostal recessions and a wheeze. Temp=normal. What is the most likely dx?

- a. URTI
- b. Pneumonia
- c. Bronchiolitis
- d. RDS
- e. Alpha 1 antitrypsin deficiency

Ans. The key is C. Bronchiolitis. [Asthma and bronchiolitis has similar sign symptoms. The difference is in pathology. In asthma there is bronchoconstriction but in bronchiolitis there is oedema of the airway wall. In infants and younger children bronchiolitis is commoner than asthma and it is seen that many of the children with bronhiolitis usually followed by asthma].

1158. An 8yo boy develops a seizure affecting his right arm, seizure lasts for several mins. He doesn't remember anything what happened. On his CT: lesion in left hemisphere. What is the most probable dx?

- a. Epilepsy
- b. Space occupying lesion
- c. Dementia
- d. Huntington's chorea
- e. Intracranial HTN

Ans. The key is B. Space occupying lesion. [This is complex partial seizure due to space occupying lesion].

1159. A 28yo female presented with complains of difficulties in swallowing liquids only. She also suffers from recurrent chest infection in the past few months. What is the most probable dx?

- a. Foreign body
- b. Plummer vinson syndrome
- c. Achalasia cardia
- d. Peptic stricture
- e. Esophageal carcinoma

Ans. The key is C. Achalasia cardia. [Dysphagia to both solid and liquid or mostly to liquid are common feature of achalasia. In achalasia there may occur aspiration due to regurgitation during lying down to sleep which may result recurrent chest infection and cough].

1160. Mother having 2 children with CF. What is the risk of getting another baby?

- a. 1:2
- b. 1:8
- c. 1:4
- d. 1:16
- e. 1:1

Ans. The key is C. 1:4. [Cystic fibrosis is an autosomal recessive disease. If both parents are carrier there is 1:4 chance of risk of occurrence of the disease for each child].

1161. A 14yo boy has been dx with nephrotic syndrome. 5d later he presents with flank pain, hematuria and fluctuating urea levels. A dx of renal vein thrombosis is made. What is the most likely cause for renal vein thrombosis?

- a. Protein C deficiency
- b. Vasculitis
- c. Loss of antithrombin III
- d. High estrogen levels
- e. Stasis

Ans. The key is C. Loss of antithrombin III.

1162. A 36yo woman presented with massive bleeding from multiple sites. Lab: fibrin degradation products: +++, plt=30, bleeding time=prolonged, PT=prolonged, APTT=prolonged. What is the most likely dx?

- a. Hemophilia
- b. DIC
- c. ITP
- d. Factor V leiden
- e. Warfarin

Ans. The key is B. DIC.

1163. A study was done amongst 2 hosp for the equal number of cancer pts. It was noted that hosp A had the higher rate of mortality than hosp B for treated cancer pts. What is the study done here classified as?

- a. Retrospective
- b. Observational
- c. Cohort
- d. Case study

Ans. The key is C. Cohort study. [A cohort is a group of people who share a common characteristic or experience within a defined period (e.g., are born, are exposed to a drug or vaccine or pollutant, or undergo a certain medical procedure)].

1164. A 17yo girl comes to see her GP after having unprotected sex 2d ago. She asks if her GP can explain to her how this prescribed procedure would work by helping her not to get pregnant.

- a. It helps to prevent implantation
- b. It helps in preventing or delaying ovulation
- c. It causes an early miscarriage
- d. It releases progesterone and stops ovulation
- e. It causes local enzymatic reaction

Ans. The key is A. It helps to prevent implantation. Probably key is suggesting IUCD which helps to prevent implantation and not the pills as both the available pill causes a delay in ovulation. [The time required for the egg to travel to the uterus and implant is usually between 7 and 10 days]. [There are two types of pill:

1. 1.5 mg of levonorgestrel pill. It should be taken within 72 hours (three days). It is thought to work mainly by preventing or delaying the release of an egg from your ovary, which normally happens each month (ovulation).

2. Ulipristal acetate (brand name ellaOne®) is a type of emergency contraceptive pill that was launched in the UK in 2009. It is taken as one single tablet. Take the pill as soon as possible after unprotected sex. The earlier you take the pill, the more effective it is. It can be taken up to 120 hours (five days) after having unprotected sex. It is a type of hormone which seems to work by stopping or delaying release of an egg (ovulation).

IUCD prevent implantation. As she is sexually active hymen is ruptured and IUCD can be given to her. But with IUCD chance of ectopic pregnancy is much more!].

1165. A 2d baby's mother is worried about the baby's hearing. Mother has a hx of conductive hearing loss. What is the most appropriate test?

- a. Brain stem evoked response
- b. CT
- c. Fork test
- d. MRI
- e. Reassure

Ans. The key is A. Brain stem evoked response. [A BAER (brainstem auditory evoked response) test can help to diagnose hearing loss and nervous system disorders, especially in newborns, young children, and others who may not be able to participate in a standard hearing test].

1166. A healthy 8yo boy had antibiotic tx for meningitis. Initially he wasn't resuscitated. What will be the outcome if he receives full tx?

- a. He will recover fully to his prv health
- b. He will have hearing impairment
- c. He will have brain abscess
- d. He will have encephalitis

Ans. The key is A. He will recover fully to his prv health.

1167. A pt presented with jaundice, fever and upper abdominal pain within 24h after removal of gallstone by ERCP. The cholangiography was done and it was patent. What is the possible cause of his complaints?

- a. Biliary infection
- b. Acute pancreatitis
- c. Perforation

Ans. The key is B. Acute pancreatitis. [Though biliary infection is possible but acute pancreatitis is more common complication of ERCP and absence of any obstruction (stone or tumour which helps biliary infection to occur) makes cholangitis less likely].

1168. A mother presents with her 14m child. He holds furniture and other things to help him stand and walk. He can say 'mama' and 'papa'. He makes eye contact and smiles. He can transfer objects from one hand to another. He responds to his name. what do you interpret from his development?

- a. Delayed gross motor development
- b. Delayed fine motor development
- c. Delayed verbal development
- d. Normal development
- e. Delayed social development

Ans. The key is D. Normal development.

1169. A young child, 3yo, has presented with vomiting for 3d. Exam: mild-mod dehydration. What is his ABG profile likely to show?

- a. pH low, PCO2 low
- b. pH low, PCO2 high
- c. pH high, PCO2 low
- d. pH high, PCO2 high

Ans. The key is D. pH high, PCO2 high. [Prolonged vomiting causes loss of H⁺, Cl⁻ and Na⁺. There is also hypokalemia. There occur metabolic alkalosis. Compensation for metabolic alkalosis occurs

mainly in the lungs, which retain carbon dioxide (CO₂) through slower breathing, or hypoventilation (respiratory compensation) leading to high PCO₂].

1170. A 68yo woman has been admitted with poor appetite, weight loss, poor concentration and self neglect for 3wks. She has not been eating or drinking adequately and has rarely left her bed. She is expressive suicidal ideas and is convinced that people are out to kill her. She has been on antidepressant therapy for the past 3m with no improvement. What is the most appropriate tx?

- a. Anti depressants
- b. CBT
- c. Interpersonal therapy
- d. ECT
- e. Antipsychotics

Ans. The key is D. ECT. This is wrong key! Correct key is E. Antipsychotics. [For psychotic depression with suicidal ideation, try antidepressants and if needed augment by adding antipsychotics and if failed then ECT].

1171. A 78yo retired teacher was admitted for a hernioplasty procedure. After the operation he became agitated, aggressive and confused. What is the most appropriate management?

- a. Diazepam
- b. Chlordiazepoxide
- c. Vit B
- d. Clozapine
- e. Thiamine

Ans. The key is B. Chlordiazepoxide. This is wrong key! Correct key is Diazepam. [Probable delirium tremens].

1172. A 25yo girl saw a tragic RTA in which a young boy was killed. The night of the event she couldn't sleep and the day after she suddenly lost her vision. She was prv fine and there was no hx of medical or psychological prbs. What is the dx?

- a. Conversion
- b. Somatization
- c. PTSD
- d. Dissociation
- e. GAD

Ans. The key is A. Conversion reaction. [Conversion reaction is sometimes applied to patients who present with neurological symptoms,

such as numbness, blindness, paralysis, or fits, which are not consistent with a well-established organic cause, and which cause significant distress. It is thought that these symptoms arise in response to stressful situations affecting a patient's mental health].

1173. A 25yo man has been suffering from breathlessness and wheeze for 3m. He has been taking salbutamol 2puffs as required. In the last 2 wks his symptoms have worsened and he has to take salbutamol more frequently during the day time. He also complains of excessive dyspnea at night. What drugs or regimen would you like to add?

- a. Prednisolone
- b. Fluticasone + salbutamol inhaled
- c. Beclomethasone inhaled
- d. Montelukast PO
- e. Salmeterol PO

Ans. The key is C. Beclomethasone inhaled. [Patient was in step 1. As not controlled next step is addition of inhaled corticosteroid].

1174. A 64yo man who was exposed to asbestos for 40yrs presents with weight loss and chest pain. The dx of mesothelioma has been made. He develops SOB and XR=pleural effusion. What is the most appropriate management?

- a. Thoracocentesis
- b. Chest drain
- c. Radiation therapy
- d. Pneumonectomy
- e. Chemotherapy

Ans. The key is E. Chemotherapy. It is probably a wrong key! Correct key should be B. Chest drain. [As mesothelioma poorly responds to chemo and radiotherapy and recurrent effusion causes distressing symptoms chest drain is the most appropriate measure. As there occurs repeated effusion so thoracocentesis is not appropriate but chest drain].

1175. A 72yo presents with polyuria and polydipsia. The fasting blood sugar is 8 and 10mmol/l. BP=130/80mmHg and the level of cholesterol=5.7mmol/l. There is microalbuminuria. What is the single most appropriate next management?

- a. ACEi and sulfonylurea
- b. Statin and biguanide
- c. Statin and glitazone
- d. Insulin and ACEi
- e. Statin and ACEi

Ans. The key is E. Statin and ACEi. This is wrong key. Here both A. ACEi and sulfonylurea and D. Insulin and ACEi are correct answer. [Please note IF SYMPTOMATIC (polyuria, polydipsia) we should give antidiabetic (preferably insulin or a secretagogue as sulfonylurea) and if not symptomatic first we shall give lifestyle modification].

1176. A 49yo woman presents to the OPD. Her oral glucose test after 2h of glucose intake vs plasma level in 2 different tests are 6mmol/l and 10mmol/l. This situation can be categorized as:

- a. Impaired glucose tolerance
- b. Impaired fasting glucose
- c. T1DM
- d. T2DM
- e. Metabolic syndrome

Ans. The key is A. Impaired glucose tolerance. [The WHO defines someone as having pre-diabetes if they have:

A fasting blood glucose of less than 7 mmol/L; AND

A blood glucose of 7.8 mmol/L or more but less than 11.1mmol/L after a two-hour oral glucose tolerance test].

1177. A white English man with a past hx of MI is a known HTN and DM. He is currently on aspirin, statin and metformin. What would you add to the tx?

- a. ACEi
- b. Diuretic
- c. Insulin
- d. Beta blocker
- e. CCB

Ans. The key is A. ACEi.

1178. A 57yo man who had MI a few months ago has been having a low mood. A dx of moderate depression has been established. Which medication is the best tx for him?

- a. SSRI
- b. TCA
- c. MAOI
- d. Benzodiazepam
- e. Mood stabilizer

Ans. The key is A. SSRI. [Among SSRIs Sertraline is the drug of choice in MI patient. If SSRI cannot be used Mirtazapine is recommended as next antidepressant].

1179. A 12yo presents with chest pain. Exam: tachycardia, hypotension, dilated neck veins and the trachea is not centrally placed. What is the next appropriate management?

- a. Portable XR
- b. Needle thoracocentesis
- c. Chest drainage
- d. ABG
- e. CTPA

Ans. The key is B. Needle thoracocentesis. [The case may be either pneumothorax or massive pleural effusion. Thoracocentesis is recommended for both].

1180. A 7yo child is being inv for TB. His parents don't agree for taking a BAL. what other sample will show growth of the organism?

- a. Blood test
- b. Throat swab
- c. Gastric washing
- d. Mantoux test
- e. CSF

Ans. The key is C. Gastric washing.

1181. A 51yo man had a MI a few days ago. He developed breathlessness. Echo was done and showed a pansystolic murmur. What can be the cause of this symptom?

- a. Ruptured papillary muscle
- b. Acute pericarditis
- c. Dresslers syndrome
- d. Malignant VT
- e. Ventricular aneurysm

Ans. The key is A. Ruptured papillary muscle. [Papillary muscle rupture causes mitral regurgitation causing pansystolic murmur leading to features of heart failure like breathlessness].

1182. A 61yo man was found with K+=7.5 and ECG with prolong QRS complex. What is the best possible tx option?

- a. Dialysis
- b. IV calcium gluconate
- c. IV insulin and dextrose
- d. Salbutamol nebulizer
- e. Loop diuretics

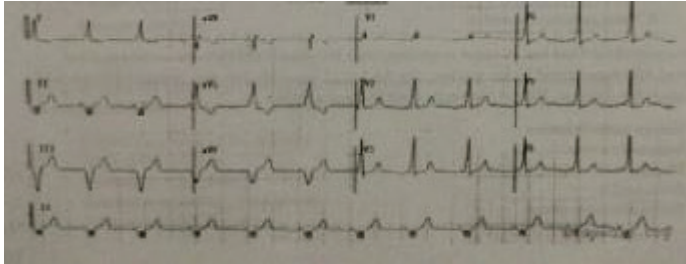
Ans. The key is B. IV calcium gluconate. [In this high level of potassium we have to shift this potassium into cells to reduce plasma level and save heart from arrest or life threatening arrhythmia. For keep the heart safe option of first choice in such emergency is IV calcium gluconate! However it does not shift or reduce potassium level but protects heart from arrhythmia and buy time for definitive measure to take place!].

1183. A 38yo man presents with acute infection of skin in the leg. Dx of cellulitis has been made. What meds should be prescribed?

- a. Penicillin + Flucloxacillin
- b. Metronidazole + erythromycin
- c. Vancomycin + metronidazole
- d. Ceftriaxone + terbinafine
- e. Ceftriaxone + flucloxacillin

Ans. The key is A. Penicillin + Flucloxacillin. [Cellulitis is usually caused by bacteria, such as staphylococci or streptococci that are commonly present on the skin. So Penicillin + Flucloxacillin should be given].

1184. A 72yo man presents to the ED with chest pain. The following ECG was taken. What is the most likely dx?



- a. Anterior MI
- b. Inferior MI
- c. Lateral MI
- d. Posterior MI
- e. NSTEMI

Ans. The key is E. NSTEMI.

1185. A 36yo woman has recently spent a lot of money on buying clothes. She goes out almost every night with her friends. She believes that she knows better than her friends, so she should choose the restaurant for eating out with her friends. She gave hx of having low mood at 12y. What is the dx?

- a. Mania
- b. Depression
- c. Bipolar affective disorder
- d. Borderline personality disorder
- e. Dysthymia

Ans. The key is C. Bipolar affective disorder. [In bipolar disorder there is depressive disorder alternate with mania and the present case is in manic stage of bipolar disorder].

1186. A homeless lady presents with cough and fever. She complains of night sweats and weight loss. CXR has been done and shows opacity. What is the next appropriate management?

- a. AFB
- b. Mantoux test
- c. IFN gamma testing
- d. Bronchoscopy
- e. CT

Ans. The key is A. AFB. [Cough, fever, night sweat and weight loss are very suggestive of TB. So we should do AFB as her next investigation].

1187. A 32yo woman presents with malaise fatigue and fever. She complains about weight loss. Exam: malar rash with sparing of nasolabial fold can be seen. What is the most appropriate inv?

- a. Anti ds DNA
- b. Anti histone
- c. Anti centromere
- d. Anti Jo
- e. Anti Scl70

Ans. The key is A. Anti ds DNA. [Features are suggestive of SLE. So most appropriate investigation from the given options is A. Anti ds DNA].

1188. A 75yo man presents with back pain. Inv: plasma cells are found. What is the most probable dx?

- a. Multiple myeloma
- b. AS
- c. Disc prolapse
- d. Leukemia
- e. Myelofibrosis

Ans. The key is A. Multiple myeloma. [H/O back pain with presence of plasma cells on inv. Are highly suggestive of Multiple myeloma].

1189. A 45yo woman presents with complains of abdominal pain and blood in stool. She brings the stool sample from home but has never been able to produce a sample at the hospital. Her urine and blood tests are normal. Exam: multiple scars on the abdomen consistent with laparoscopies and appendectomy. She insists on getting further inv although no abnormalities are found. What is the most likely dx?

- a. Malingering
- b. Somatization
- c. Hypochondriasis
- d. Conversion disorder
- e. Munchausen syndrome

Ans. The key is E. Munchausen syndrome. [Munchausen syndrome is a psychiatric factitious disorder wherein those affected feign disease, illness, or psychological trauma to draw attention, sympathy, or reassurance to themselves].

1190. A 36yo woman contacts the police to notify them she was responsible for a recent disastrous flood with loss of lives. What kind of delusions is she suffering from?

- a. Persecutory
- b. Poverty
- c. Guilt
- d. Nihilistic
- e. Reference

Ans. The key is C. Delusion of guilt. [Delusions of guilt or sin (self-accusation): This type of delusions involve feeling guilty or remorseful for no valid reason. An example would be someone that believes they were responsible for a war in another country or hurricane damage in another state. In this case, the person believes that they deserve to be punished for their sins and place full blame on themselves].

1191. A 27yo man presents with symptoms characterized by alternating mood swings a/w flight of ideas, elation, over activity and disinhibition, or low mood with lack of energy and social withdrawal. What is the most probable dx?

- a. Bipolar affective disorder
- b. Dysthymia
- c. Mania
- d. Hypomania
- e. Cyclothymia

Ans. The key is A. Bipolar affective disorder. [Flight of idea, elation, over activity and disinhibition are features of mania and low mood, lack of energy and social withdrawal are features of depression. Alternating mood swings with depression and mania are characteristic of Bipolar disorder].

1192. Healthy parents have 2 children, a child with CF and a healthy child. They want to have another child. What are the chances of that child being a carrier?

- a. 1:4
- b. 1:2
- c. 2:3
- d. 1:8
- e. 1:16

Ans. The key is B. 1:2. [As the parents have a child with cystic fibrosis and they are healthy both of them are carrier. It is an autosomal recessive disease where if both parents are carrier mode of inheritance is as follows: Chance of being healthy child 1:4, Chance of being diseased 1:4 and chance of being carrier 1:2].

1193. A 64yo man believes a female newscaster is communicating directly with him when she turns a page. What kind of delusions is he suffering from?

- a. Persecutory
- b. Control
- c. Grandeur
- d. Nihilistic
- e. Reference

Ans. The key is E. Delusion of reference. [Delusions of reference – A neutral event is believed to have a special and personal meaning. For example, a person with schizophrenia might believe a billboard or a celebrity is sending a message meant specifically for them].

1194. A 7yo girl with allergy became acutely unwell while visiting a friend's house and has been brought immediately to the ED. She is fully conscious but has got stridor, wheeze and erythematous rash. She is receiving oxygen. What is the single immediate management?

- a. Check airway patency and prepare intubation
- b. Give 0.25ml in 1000U epinephrine IM
- c. Give 10mg chlorpheniramine IM
- d. Give 50ml hydrocortisone IM
- e. Obtain secure IV access

Ans. The key is B. Give 0.25ml in 1000U epinephrine IM. [Stridor is one of the indication of IM epinephrine in anaphylaxis].

1195. A terminally ill pt with metastatic carcinoma presents with dysphagia and difficulty in swallowing. What is the best possible tx?

- a. Nystatin suspension
- b. Amphotericin B IV
- c. PO fluconazole
- d. Cotrimazole
- e. Analgesic

Ans. The key is C. PO fluconazole. [Treatment of carcinoma can predispose to development of oesophageal candidiasis which is treated as follows: Oral fluconazole (200 – 400mg) daily for 14 to 21 days (if needed IV fluconazole can also be given)].

1196. A couple attends their GP because of marital problems. The wife states that her husband is having affairs although she has no proof of this. The husband states that she even had him followed by a private detective and this is putting considerable strain on their marriage. What is the most likely dx?

- a. Fregoli syndrome
- b. Cotard syndrome
- c. Mood disorder
- d. Ekblom syndrome
- e. Othello syndrome

Ans. The key is E. Othello syndrome. [Othello syndrome is delusion of infidelity (cheating, adultery, or having an affair) of a spouse or partner].

1197. A 65yo lady who is on thiazide suffers from falls in the morning. What is the cause for her symptoms?

- a. Orthostatic hypotension
- b. TIA
- c. Epilepsy

Ans. The key is A. Orthostatic hypotension. [Thiazide diuretic is associated with orthostatic hypotension].

1198. A boy was admitted with partial thickness burn, what is your next step?

- a. Escharectomy
- b. Dressing
- c. Burst blisters
- d. Local antibiotics
- e. Refer to burn unit

Ans. The key is E. Refer to burn unit.

1199. A 28yo man presents with a 2h hx of rapid palpitations. He feels a little light headed but is otherwise well. Exam: pulse=170bpm and regular, BP=100/68mmHg. He has had 2 similar episodes in the past. What is the most likely rhythm disturbance?

- a. SVT
- b. VF
- c. VT
- d. V-ectopics
- e. A-fib

Ans. The key is A. SVT. [Palpitation, light headedness with a tachycardia of 170bpm that is regular are most likely a SVT].

1200. A child has hypothyroidism. What feature is a/w it?

- a. Microglossia
- b. Prolonged neonatal jaundice
- c. Undescended testis
- d. Anal tag
- e. Left soft palate

Ans. The key is B. Prolonged neonatal jaundice. [Prolonged neonatal jaundice is a well known feature of hypothyroidism].

1201. A 2wk girl presents with E-coli which is confirmed by urine culture. What is the most appropriate next inv?

- a. US
- b. IVU
- c. CT kidney
- d. BUE
- e. MCUG

Ans. The key is US. [Infants and children who have had a lower urinary tract infection should undergo ultrasound (within 6 weeks) only if they are younger than 6 months or have had recurrent infections. NICE (Probably to exclude VUR which is a cause of recurrent UTI)].

1202. A lady from Asia presented with lump in her neck. FNAC has been done and revealed lesions with caseous material in the center surrounded by fibrosis. What is the most probable dx?

- a. Thyroid carcinoma
- b. TB lymphadenitis
- c. Lymphoma
- d. Inf Mono
- e. Mesothelioma

Ans. The key is B. TB lymphadenitis. [Central caseous necrosis with surrounded fibrosis is diagnostic of TB lymphadenitis. The most common cellular components seen are epithelioid cell clusters. Lymphocytes and Langhans giant cells].

1203. A 32yo woman has undergone a biopsy for a breast lump. The report says: a well circumscribed lump with clear margins and separated from the surrounding fatty tissue. What is the most appropriate interpretation of this report?

- a. Fibroadenosis
- b. Ca Breast
- c. Mammary abscess
- d. Fibroadenoma
- e. Fat necrosis

Ans. The key is D. Fibroadenoma. [Fibroadenomas are the most common benign tumor of the female breast. White, well-circumscribed mass is clearly demarcated from the surrounding yellow adipose tissue].

1204. A young boy presented with peri-oral blisters. Some of which are weeping and others are crusted. What is the single most appropriate dx?

- a. Impetigo
- b. Varicella zoster
- c. Shingles
- d. Scabies
- e. Herpes simplex

Ans. The key is A. Impetigo. [Distribution of varicella zoster is centripetal (more in central area (trunk) and less in limbs and face. On the other hand if blisters are present mainly on face or limbs and/or described as golden, yellow or honey coloured crusts are impetigo].

1205. A 39yo man comes with umbilicated papules on his face. His CD4 count is measured to be 35. What is the single most appropriate option?

- a. Mycobacterium avium intercellular
- b. CMV
- c. Streptokinase
- d. Toxoplasmosis
- e. Pneumocystis jirovecii
- f. Molluscum contagiosum

Ans. The key is F. Molluscum contagiosum. [CD4 count 35 is too low indicating immunodeficiency where molluscum contagiosum occurs more easily. Umbilicated papules are feature of molluscum contagiosum].

1206. A 45yo man is admitted to ED with excruciating pain in the right leg. Exam: limb is pale and dorsalis pedis and posterior tibial pulses are absent. Pulse=88bpm, irregular and he has a pansystolic murmur at apex. What is the most probable dx?

- a. Thromboangitis Obliterans
- b. Sciatica
- c. DVT
- d. Atherosclerosis
- e. Embolus

Ans. The key is E. Embolus. [Pansystolic murmur at apex indicates mitral regurgitation and irregular pulse indicates AF which can lead to thrombus formation what probably is responsible for this embolus in leg].

1207. An 18yo man has a smooth, tender swelling extending from the ear to the angle of the jaw of sudden onset. Temp=38.5C. What is the single most likely dx?

- a. Dental caries
- b. Mumps
- c. OE
- d. OM
- e. Temporomandibular joint pain

Ans. The key is B. Mumps. [Here sudden onset and rise of temperature are points indicating the diagnosis of Mumps].

1208. A 6wk baby has a blue mark near coccyx since birth. His mother is worried. What would you do?

- a. Reassure
- b. Coag profile
- c. Karyotyping
- d. Skeletal survey
- e. CT

Ans. The key is A. Reassure. [This is a benign condition known as "Mongolian spot" or "Mongolian blue". Mongolian spot refers to a macular blue-gray pigmentation usually on the sacral area of healthy infants. Mongolian spot is usually present at birth or appears within the first weeks of life. Mongolian spot typically disappears spontaneously within 4 years but can persist for life].

1209. A man presents with inoperable carcinoma and back pain. His pain has been well controlled with morphine but he develops vomiting. Morphine was stopped and he was started on metoclopramide and fentanyl patches. He then develops neck stiffness and fever. What is the cause of these symptoms?

- a. Metoclopramide
- b. Fentanyl
- c. Morphine
- d. Meningitis
- e. Metastasis

Ans. The key is A. Metoclopramide. [Extrapyramidal effects like neck stiffness is common side effect of metoclopramide and also there may occur rise of temperature].

1210. A 51yo man has become increasingly fatigued for the past 10m. PE: no abnormal findings. Labs: Hgb=9.2, Hct=27.9%, MCV=132fl, plt=242, WBC=7.59. Which of the following morphologic findings is most likely to be present on examination of his peripheral blood smear?

- a. Hypersegmented neutrophils
- b. Nucleated RBC
- c. Blasts
- d. Hypochromic, microcytic RBC
- e. Schistocytes

Ans. No key is given! Probable key is A. Hypersegmented neutrophils. [Only anemia with macrocytosis is with normal examination findings makes Megaloblastic anaemia to be most likely cause where PBF shows hypersegmented neutrophils].

1211. A 9yo girl with weekly abdominal pain and occasional headaches but not a/w vomiting or diarrhea. She maintains a good appetite. Lab: normal. CBC, BUE, etc are normal. Exam: no abnormality as found and the abdomen was soft and non-tender. What would you do for her next?

- a. US abdomen
- b. CT thorax
- c. LFT
- d. Reassure
- e. Analgesics

Ans. The key is D. Reassure. [Probable case of abdominal migraine a benign condition for which reassurance is appropriate. Abdominal migraine is a form of migraine seen mainly in children. It is most common in children ages five-nine years old, but can occur in adults as well. The diagnostic criteria for abdominal migraine are:

- A. At least five attacks fulfilling criteria B-D.
- B. Attacks of abdominal pain lasting 1-72 hours (untreated or unsuccessfully treated).
- C. Abdominal pain has all of the following characteristics:
 - C1. Midline location, periumbilical, or poorly localized
 - C2. Dull or 'just sore' quality
 - C3. Moderate or severe intensity
- During abdominal pain at least two of the following:
 - Anorexia
 - Nausea
 - Vomiting
 - Pallor
- Not attributed to another disorder (1)].

1212. A 54yo male pt DM with BMI=33 who has been treated using dietary control up till now presents to his GP with a fasting blood sugar of 14mmol/l and creatinine=90mmol/l. Urine shows glycosuria. No other abnormalities are found. What is the best next step in management?

- a. Biguanide
- b. Sulfonylurea
- c. Insulin
- d. Sugar free diet
- e. ACEi

Ans. The key is A. Biguanide. [Patient is obese type2 diabetic with normal renal function for whom biguanide is the treatment of choice].

1213. What are the side effects of thiazide diuretics?

- a. Hypocalcemia
- b. Hyponatremia
- c. Hypernatremia
- d. Hyperkalemia

Ans. The key is B. Hyponatremia. [Thiazide causes hypercalcemia, hypokalemia and hyponatremia].

1214. A 46yo man who is a heavy drinker is brought to the ED in a drowsy state. He is responding vaguely to questions. Exam: nystagmus and hyperreflexia. MCV=103fl. What is the most likely cause for his cognitive impairment?

- a. B1 deficiency
- b. B12 deficiency
- c. Folate deficiency
- d. B6 deficiency
- e. Alcohol withdrawal

Ans. The key is A. B1 deficiency. [Presence of confusion and nystagmus indicates Wernicke's encephalopathy caused by thiamin (vit. B1) deficiency].

1215. A 23yo female presented with a swelling of her neck that moved upwards on protrusion of tongue. What is the next appropriate inv?

- a. FNAC
- b. Punch biopsy
- c. Core biopsy
- d. MRI neck
- e. Radioactive thyroid scan

Ans. The key is A. FNAC. [The diagnostic investigation is FNAC[Ref: wikipedia]. Then we palpate for thyroid tissue. If absent we do any one of following to confirm the absence of thyroid tissue: ultrasonography, CT scanning, thyroid scanning or MRI. If there is normal thyroid tissue we go for more aggressive Sistrunk's operation but if there is no normal thyroid tissue [in that case thyroglossal cyst itself may be the only source of thyroid tissue] we do conservative surgery and preserve some portion of cyst with thyroid tissue].

1216. A 34yo man from Asia presented with 5m hx of productive cough, night sweats and weight loss. His CXR reveals some shadowing in the left upper zone. What is the single most discriminating inv?

- a. AFB for sputum
- b. CXR
- c. CT
- d. TFT
- e. US abdomen

Ans. The key is A. Sputum for AFB. [Features are suggestive of PTB for which most discriminating inv. Is Sputum for AFB].

1217. A prv healthy 23yo presented a week hx of bloody diarrhea and abdominal pain with cramps and fever. Exam: tenderness in lower abdomen. What is the most appropriate dx?

- a. Celiac disease
- b. Colorectal polyps
- c. UC
- d. Laxative abuse
- e. Gastroenteritis

Ans. The key is E. Gastroenteritis. [A short history (one week) of bloody diarrhea, abdominal pain with cramps, fever and tenderness in lower abdomen is indicative of gastroenteritis].

1218. A 10yo boy presents with irritability, sudden onset of pain and discharge from the right ear. Which antibiotic would be the 1st line of tx?

- a. Amoxicillin
- b. Ciprofloxacin
- c. Flucloxacillin
- d. Ceftazidime
- e. Benzyl penicillin

Ans. The key is A. Amoxycillin. [For acute suppurative otitis media 1st

line antibiotic in UK is Amoxycillin. Ref: patient.info].

1219. A 26yo man strongly believes that every elderly man he meets is his father. Although they look different, he is sure it is father wearing different disguises. What kind of delusions is this man suffering from?

- a. Delusion of persecution
- b. Erotomania
- c. Delusion of grandeur
- d. Delusion of doubles
- e. Delusion of reference

Ans. The key is D. Delusion of doubles. [The Fregoli delusion, or the delusion of doubles, is a rare disorder in which a person holds a delusional belief that different people are in fact a single person].

1220. A 26yo passed a 4mm stone in his urine. On US a 3mm stone is found in the renal pelvis. What is the single most appropriate management?

- a. ESWL
- b. None
- c. Open Surgery
- d. Conservative

Ans. The key is D. Conservative. [Increased fluid intake is advised].

1221. A 35yo man has had acute pain and swelling below the mandible on the left side for 2h. The swelling occurred after eating a large meal. What is the single most likely dx?

- a. Laryngocele
- b. Ranula
- c. Neck abscess
- d. Parotid calculus
- e. Submandibular calculus

Ans. The key is E. Submandibular calculus. [Pain and swelling below mandible is due to stone in submandibular salivary gland duct. Pain and swelling increased after large meal as the saliva produced during meal could not come out of the gland due to stone].

1222. A 45yo man has had impaired vision and pain on eye movement in his left eye over the last 5d. He also notes loss of color vision in the same eye. In the left eye, the visual acuity is up to counting fingers. When the pupil is stimulated with light, it dilates. His fundus is normal. What is the single most appropriate clinical dx?

- a. Acute dacryocystitis
- b. Acute iritis
- c. Papillitis
- d. Retrobulbar neuritis
- e. Scleritis

Ans. The key is D. Retrobulbar neuritis. [Presentation can be described by either optic neuritis or retrobulbar neuritis. In optic neuritis there is disc pallor. As in this case disc is normal it is a case of retrobulbar neuritis].

1223. A 56yo pt has been dx with MS. She presents with a positive Romberg's test. She also has weakness and loss of sensations in all her 4 limbs. Which site is most likely to be affected?

- a. Cerebral cortex
- b. Cerebellum
- c. Cervical spinal cord
- d. Thoracic spinal cord
- e. Brain stem

Ans. The key is C. Cervical spinal cord. [Quadriplegia is the feature of cervical cord lesion].

1224. A 58yo man suddenly becomes shocked several days after suffering an acute ant MI. His CXR shows a large globular-shaped heart and clear lung fields. What is the single most likely explanation for the abnormal inv?

- a. Acute pericarditis
- b. Cardiac tamponade
- c. Atrial thrombus
- d. Left ventricular aneurysm
- e. Dressler syndrome

Ans. The key is B. Cardiac tamponade. [Shock in a post MI patient with globular heart on X-ray and clear lung field indicate Cardiac tamponade].

1225. A 56yo alcoholic man who has increased the amount of alcohol he is using wants to attend his daughter's wedding that is in 2wks. He is now coming to you for help. How would you help him?

- a. Acamprosate
- b. Refer to clinical psychologist
- c. Refer to GP
- d. Despiramine
- e. Refer to community mental health support group.

Ans. The key is A. Acamprosate. [If the patient stop alcohol without any supportive treatment there will occur withdrawal symptoms. For the presented situation Acamprosate can help by stopping alcohol without producing withdrawal symptoms (by restoring brain chemical derangement caused by alcohol which is responsible for withdrawal symptoms)].

1226. An 80yo woman fell over at her nursing home. XR shows fx of radius with <10degree of dorsal angulation. What is the single most appropriate tx?

- a. Below elbow full plaster of paris
- b. Below elbow split plaster of paris
- c. Closed reduction of fx
- d. Elasticated support bandage
- e. Open reduction and internal fixation

Ans. The key is C. Closed reduction of fracture. This is a wrong key! Correct option seems to be A. Below elbow full plaster of paris. [Older people are less likely to go under closed reduction even if the dorsal angulation is not anatomic (like 20 degrees!). Less than 10 degree dorsal angulation does not require even closed reduction].

1227. A 16yo girl who is normally fit and well attends her GP complaining of heavy and painful periods. She is requesting tx for these complaints. She denies being sexually active. Select the most appropriate management for her menorrhagia?

- a. Antifibrinolytics (tranexamic acid)
- b. COCP
- c. Endometrial ablation
- d. IUS progestogens (mirena)
- e. NSAIDS (mefenamic acid)

Ans. The key is A. Antifibrinolytics (tranexamic acid). It is a wrong key. Correct answer is E. NSAIDs (mefenamic acid).

1228. A 67yo lady with an ulcer on the anal margin. Which is the single most appropriate LN involved?

- a. External iliac LN
- b. Pre-aortic LN
- c. Aortic LN
- d. Inguinal LN
- e. Iliac LN

Ans. The key is D. Inguinal LN. [Anal canal below pectinate line is drained into superficial inguinal lymph nodes].

1229. A branch of the dominant coronary artery that supplies the inferior portion of the septum. What is the single most appropriate option?

- a. Septal branches
- b. Obtuse marginal branches
- c. Circumflex artery
- d. Left main stem, post descending artery
- e. Diagonal branch

Ans. The key is D. Left main stem, post descending artery. [Here no option is satisfactorily correct! By dominant coronary artery we mean that coronary artery which gives of the branch of posterior descending artery. Mostly it is right coronary artery and if there is left coronary dominance, posterior descending artery is the branch of circumflex artery and not direct branch of left main artery. However the only option that goes nearer is D. Left main stem, post. descending artery].

1230. A 55yo female presented with anemia and dysphagia. There is a feeling of something stuck in the throat. The esophagus can't be negotiated beyond the crico-pharynx. What is the most probable dx?

- a. Foreign body
- b. Plummer vinson syndrome
- c. Pharyngeal carcinoma
- d. Barret's esophagus
- e. Esophageal carcinoma

Ans. The key is B. Plummer Vinson syndrome. [The picture fits two D/D. 1. Plummer Vinson syndrome 2. Oesophagial carcinoma. Lower oesophagial stricture is more common for Ca. So presenting case is likely a case of Plummer Vinson syndrome. It can be differentiated by the type of anemia. If it is IDA dx is Plummer Vinson syndrome].

1231. A pt is on cancer tx with dexamethasone. According to her biochemical results her K+=normal and her Na+=low. What is the dx?

- a. Addison's
- b. Dexamethasone side effect
- c. Dilutional hyponatremia

Ans. The key is C. Dilutional hyponatremia.

1232. A diabetic has been prescribed a long acting hypoglycemic in the morning and short acting in the evening. He takes a regular lunch, but has been having hypoglycemic attacks at around 4pm each day. What is the most appropriate intervention?

- a. Recommend a heavier lunch
- b. Review morning drug
- c. Review evening drug
- d. Review both drug
- e. Reassure

Ans. The key is B. Review morning drug. [As there is hypoglycemic attacks at evening morning dose needs to be adjusted].

1233. A male pt presented with blood and mucus in stool. He has also noticed weight loss but has no hx of altered bowel habits. What is the dx?

- a. Carcinoma of cecum
- b. Carcinoma of descending colon
- c. Carcinoma of sigmoid colon
- d. Carcinoma of rectum

Ans. The key is A. Carcinoma of cecum.

1234. A 22yo man keeps having persistent and intrusive thoughts that he is a dirty thief. No matter what he tries these thoughts keep coming to him. Any attempt to avoid these thoughts leads to serious anxiety. What is the most likely dx?

- a. Schizophrenia
- b. OCD
- c. PTSD
- d. Mania
- e. Psychotic depression

Ans. The key is B. OCD. [Though here is obsession or thoughts but no compulsion of activity but there is compulsion of thoughts as well which makes the diagnosis as OCD].

1235. A 45yo female comes to the ED while having a generalized tonic clonic seizure and she has having difficulty breathing and is cyanosed. What is the tx option for her?

- a. Secure airways
- b. IV diazepam
- c. IV phenytoin
- d. Oxygen mask

Ans. A. Secure airways. [Breathing difficulty with cyanosis may indicate saliva, blood, foreign body (as denture), fall back of tongue etc. for which 1st action is to secure airway].

1236. A 30yo man is becoming concerned about the safety of his family. He has been checking the locks of the door every hour during the night. He becomes very anxious if his wife tries to stop him. What is the most likely dx?

- a. Paranoid delusion
- b. PTSD
- c. Social phobia
- d. OCD
- e. GAD

Ans. The key is D. OCD. [Obsessive compulsive disorder (OCD) is a mental health condition where a person has obsessive thoughts and compulsive activity.

An obsession is an unwanted and unpleasant thought, image or urge that repeatedly enters a person's mind, causing feelings of anxiety, disgust or unease.

A compulsion is a repetitive behaviour or mental act that someone feels they need to carry out to try to temporarily relieve the unpleasant feelings brought on by the obsessive thought].

1237. A 6wk baby has been dx as HIV+ve. Which immunization plan will you opt for him?

- a. Don't give any vaccine
- b. Give all vaccines except live attenuated vaccines
- c. Give only BCG vaccine
- d. Give all vaccines except BCG vaccine

Ans. The key is D. Give all vaccines except BCG vaccine. [There are two terms HIV +ve (not immune deficient yet) and AIDS (immune deficient state). In HIV +ve case live attenuated vaccines can be given except BCG and if AIDS all live attenuated vaccines are avoided].

1238. A 36yo man has been dx with DI. What electrolyte picture is expected to be seen?

- a. High serum Na, low serum osmolality, high urine osmolality
- b. Low serum Na, low serum osmolality, high urine osmolality
- c. Low serum Na, high serum osmolality, high urine osmolality
- d. High serum Na, high serum osmolality, low urine osmolality
- e. Normal Na, normal serum osmolality, normal urine osmolality

Ans. The key is D. High serum Na, high serum osmolality, low urine osmolality.

1239. The artery that supplies the ant right ventricular wall. What is the single most appropriate option?

- a. Acute marginal branch
- b. Left ant descending artery
- c. Coronary sinus
- d. Circumflex artery
- e. Right coronary artery

Ans. The key is A. Acute marginal branch.

1240. A 55yo male presents to the ED after an RTA with breathlessness, engorged neck veins and a dull percussion note on the right side of his chest. Exam: pulse=140bpm, BP=80/50mmHg. What is the most likely dx?

- a. Hemothorax
- b. Hemopneumothorax
- c. Tension pneumothorax
- d. Simple pneumothorax

Ans. The key is B. Hemopneumothorax.

1241. A 32yo woman presents with complaints of having low back pain. She is taking analgesics for it. All inv are normal. What will you advice her?

- a. Bed rest
- b. Physiotherapy
- c. Advice to be more active
- d. Admit

Ans. C. Advice to be more active.

1242. A 32yo woman suffers an episode of severe occipital headache with vomiting and LOC. She is brought to the hosp where she is found to be conscious and completely alert. Exam: normal pulse and BP with no abnormal neurological sign. What is the next step in her management?

- a. Admission for observation
- b. CT brain
- c. MRI head
- d. Reassurance and discharge home
- e. XR skull

Ans. The key is B. CT brain. [To exclude any possible intracranial bleeding].

1243. A 30yo woman is taking tx for asthma. She has a HR=130bpm and peak expiratory flow rate=400. What is the most appropriate management?

- a. Atenolol
- b. Digoxin
- c. Review drugs

Ans. The key is C. Review drugs. [Oral beta agonist frequently causes tachycardia and palpitations].

1244. A pt presents with a mask face. He also has gait prbs. Which class of drug is causing this?

- a. Anti-depressant
- b. Anti-psychotic
- c. Anti-HTN

Ans. The key is B. Anti-psychotic. [Anti-psychotics by reducing dopamine can precipitate or induce parkinsonism].

1245. A 16yo boy came home from boarding school with a cough. His CXR showed bilateral consolidations. What is the most likely organism which would have caused his symptoms?

- a. Legionella pneumophila
- b. Mycoplasma pneumonia
- c. Mycobacterium TB
- d. Pneumocystis jiroveci
- e. Pseudomonas aeruginosa

Ans. The key is B. Mycoplasma pneumonia. [Mycoplasma is common in military barrack, prison or boarding dwellers].

1246. After an MI, a man presents with pansystolic murmur which is radiating to the axilla. What is the dx?

- a. Tricuspid regurgitation
- b. Mitral regurgitation
- c. Aortic stenosis
- d. Mitral stenosis

Ans. The key is B. Mitral regurgitation. [MI can lead to papillary muscle rupture causing mitral regurgitation].

1247. A 34yo labourer developed severe pain in his lower back after lifting a sack of sand. He also complains of shooting pain down his leg. The GP has prescribed him complete bed rest, with painkillers and also scheduled an MRI for him. What is the most likely dx?

- a. Peripheral vascular disease
- b. Intervertebral disc prolapse
- c. Hairline fx of the spine
- d. Sprain of the back muscles
- e. Muscle injury

Ans. The key is B. Intervertebral disc prolapse. [Intervertebral disc prolapsed can cause severe back pain following heavy lifting and radiculopathy (pressure on spinal nerve root) can cause this shooting pain which can be demonstrated by MRI spine].

1248. A young man returns to his hostel and gets headache and lethargy. Now presents with fever. There are crepitations on the auscultation of lung. What is the most likely organism which would have caused his symptoms?

- a. Legionella pneumonia
- b. Mycoplasma
- c. Staphylococcus
- d. Streptococcus

Ans. The key is A. Legionella pneumonia. [Legionella is common in hostel, hotel, hospital, nursing home where it spread through their water system, aircondition etc.].

1249. A pt is about to undergo surgery. Her Hgb=8.9g/dl and MCV=70. What is the best option for her?

- a. Inv and postpone the surgery
- b. Transfuse and proceed with surgery
- c. Transfuse and defer surgery
- d. Continue with surgery

Ans. Key is A. Investigation and postpone the surgery. [For elective operation only proceed if Hb% > 10 g/dl. If Hb% < 10 g/dl then defer the operation and investigate first. If Hb% < 8 g/dl also must be transfused. Samson note].

1250. A 24yo male presents with discomfort in the groin area and scrotal swelling. Exam: scrotal skin is normal. What would be the next best step?

- a. Urgent US
- b. Urgent surgery
- c. OPD referral
- d. Antibiotics

Ans. The key is C. OPD referral. [A case of inguinal hernia or hydrocele. In both torsion or epididymo-orchitis scrotal skin will be inflamed (erythematous and oedematous). Should be referred to Surgery OPD].

1251. A 22yo girl unhappy about her weight with BMI=22. She likes to have her dinner in an expensive restaurant. She does excessive shopping. K+=3.3. What is the dx?

- a. Anorexia nervosa
- b. Bipolar
- c. OCD
- d. Bulimia

Ans. The key is D. Bulimia. [BMI 22, even though unhappy, hypokalemia, like to have dinner in an expensive restaurant (probable binge eating) suggest the diagnosis of bulimia].

1252. A 59yo pt has been dx with HTN. His BP has been >160/90mmHg on 3 separate occasions. His biochemical profile is as follows: Na+=145mmol/l, K+=6.2mmol/l, creatinine=112umol/l, urea=5.7mmol/l. What is the most appropriate anti-HTN drug for him?

- a. Amlodipine
- b. Bendroflumethiazide
- c. Ramipril
- d. Lorisartan
- e. Propranolol

Ans. The key is B. Bendroflumethiazide. [Thiazide reduces Na+ and K+ level. So in this picture of upper normal Na+ with hyperkalemia thiazide seems to be appropriate].

1253. A 22yo girl had a fight with her boyfriend and then took 22 tabs of paracetamol. She was commenced on N-acetyl cysteine and she was medically fit to go home the following day. Which of the following does she require?

- a. OPD referral to relationship counselor
- b. OPD referral to psychiatrist
- c. Inpatient referral to psychiatrist
- d. Inpatient referral to psychologist

Ans. The key is C. Inpatient referral to psychiatrist. [Suicidal ideation is abnormal and if discharged there is chance of repeated suicidal attempts. So inpatient referral to psychiatrist is needed for this patient].

1254. A 74yo man presents with sudden onset of with right sided weakness and slurred speech. He also has loss of sensation over the right side of the body and visual field defects. CT shows ischemic stroke. What is the most appropriate management?

- a. Alteplase
- b. Streptokinase
- c. Nimodipine
- d. Aspirin
- e. Labetolol

Ans. The key is A. Alteplase. [Patient has acute onset of symptoms and time of onset is also known. So considering window period of 4.5 hours from onset of symptoms can be given alteplase].

1255. The artery that runs along the left AV groove. What is the single most appropriate option?

- a. Left internal mammary artery
- b. Left anterior descending artery
- c. Circumflex artery
- d. Left main stem (LMS) post descending artery
- e. Diagonal branch

Ans. The key is C. Circumflex artery.

1256. A 26yo man presents with painless hematuria. He has no other complaints and on examination no other abnormality is found. What is the most appropriate initial inv to get to a dx?

- a. Cystoscopy
- b. Midstream urine for culture
- c. Abdominal US
- d. MRI spine
- e. Coag screening

Ans. The key is C. Abdominal ultrasound. [Abdominal US to exclude polycystic disease, malignancy, tumour, urolithiasis etc].

1257. A pt, 50yo smoker and heavy drinker, presents with complaints of racing heart. A 24h EKG comes out normal. What is your next step in management?

- a. Echo
- b. Reassure
- c. Stress test

Ans. The key is B. Reassure. [Racing heart or palpitation is a common phenomenon in alcoholics which is not serious or harmful. So reassure the patient].

1258. A 36yo woman came with uterine bleeding. Vaginal US reveals uterine thickness=12mm. what is the most probable dx?

- a. Cervical ca
- b. Endometrial ca
- c. Ovarian ca
- d. Breast ca
- e. Vaginal ca

Ans. The key is B. Endometrial Ca. [Actually it is endometrial thickening and in general 12 mm means hyperplasia which may suggest endometrial Ca in this woman].

1259. A 30yo woman has PID which was treated with metronidazole and cephalosporin. It is getting worse. What is the next best inv?

- a. Endocervical swab
- b. US
- c. Laparotomy
- d. High vaginal swab

Ans. The key is B. US. [Probable tubo-ovarian abscess].

1260. A pregnant woman had hit her chest 3wks ago. Now she is 24wks pregnant and presents with left upper quadrant mass with dimpling. What is the most probable dx?

- a. Breast ca
- b. Carcinoma
- c. Fibroadenoma
- d. Fibroadenosis
- e. Fatty necrosis of breast

Ans. The key is E. Fatty necrosis of the breast.

1261. A pregnant pt with Rh -ve who hasn't been prv sensitized delivers her first baby without any prbs. What would be the latest time to administer anti-sensitization?

- a. 6h PP
- b. 24h PP
- c. 48h PP
- d. 72h PP
- e. 5d PP

Ans. The key is D. 72h PP.

1262. A 30yo primigravida who is 30wks GA presents to the L&D with absent fetal movements. She also complains of severe headache, heartburn and seeing floaters before her eyes for the last few days. Exam: BP=170/110mmHg, urine protein=++++, rock hard uterus, no visible signs of fetal movements. Choose the single most likely dx?

- a. Abruptio of placenta 2nd pre-eclampsia
- b. Antepartum hemorrhage
- c. Placenta previa
- d. Primary PPH
- e. IUFD
- f. Abruptio of placenta due to trauma

Ans. 2 keys A. Abruptio of placenta 2nd pre-eclampsia, E. IUFD. Both are correct!

1263. A 38yo woman, 10d post partum, presents to her GP with a hx of passing blood clots per vagina since yesterday. Exam: BP=90/40mmHg, pulse=110bpm, temp=38C, uterus tender on palpation and fundus is 2cm above umbilicus, blood clots +++. Choose the single most likely dx?

- a. Abruptio of placenta 2nd preeclampsia
- b. Concealed hemorrhage
- c. Primary PPH
- d. Secondary PPH
- e. Retained placenta
- f. Scabies

Ans. The key is D. Secondary PPH. [Secondary PPH occurs from 24 hours after delivery. Usually occurs between 5 and 12 days].

1264. A 22yo lady who is in her last trimester of pregnancy comes with hx of exposure to a child dx with chicken pox 1d ago. She was investigated and was +ve for varicella antibody. What is the single most appropriate management?

- a. Give varicella Ig
- b. Quarantine
- c. Give varicella vaccination
- d. Oral acyclovir
- e. Reassure

Ans. The key is E. Reassure. [If you have antibodies in your blood, this means you have had chickenpox in the past, or have been immunised. No further action is then needed].

1265. A 22yo woman who is 20wk pregnant came with pain and bleeding per vagina. Exam: os is not open. What is the single most likely dx?

- a. Threatened abortion
- b. Missed abortion
- c. APH
- d. Miscarriage
- e. Inevitable abortion

Ans. The key is A. Threatened abortion.

1266. A 32yo lady G1, 28wks GA came to her ANC with a concern about pain relief during labour. She has no medical illnesses and her pregnancy so far has been uncomplicated. She wishes to feel her baby being born but at the same time she wants something to work throughout her labour. What method of pain relief best matches this lady's request?

- a. C-section
- b. Pudendal block
- c. Entonox
- d. TENS
- e. Pethidine

Ans. The key is C. Entonox. [This is a mixture of oxygen and nitrous oxide gas. Gas and air won't remove all the pain, but it can help to reduce it and make it more bearable].

1267. A primipara at fullterm in labor has passed show and the cervix is 3cm dilated. What is the single most appropriate management for her labor?

- a. Repeat vaginal examination in 4h
- b. CTG
- c. IV syntocinon drip
- d. Repeat vaginal examination in 2h
- e. Induction of labour

Ans. The key is A. Repeat vaginal examination in 4h.

1268. A 36yo pregnant woman comes for evaluation with her husband. Her husband has been complaining of morning sickness, easy fatiguability and even intermittent abdominal pain. What is the husband suffering from?

- a. Ganser syndrome
- b. Couvade syndrome
- c. Pseudo-psychosis
- d. Stockholm syndrome
- e. Paris syndrome

Ans. The key is B. Couvade syndrome. [Couvade syndrome, also called sympathetic pregnancy, is a proposed condition in which a partner experiences some of the same symptoms and behavior of an expectant mother].

1269. A woman comes to the ED complaining of pain in the right side of the abdomen, she has 7wks amenorrhea. Her pregnancy test is +ve and US scan shows an empty uterus. What is the next step?

- a. Laparoscopy
- b. HCG measurements
- c. US
- d. Laparotomy
- e. Culdo-centesis

Ans. B. HCG measurements. This is a wrong key! Correct key is A. Laparoscopy. [Surgery should be offered to those women who cannot return for follow-up after methotrexate or to those who have any of the following:

Significant pain.
Adnexal mass ≥ 5 mm.
Fetal heartbeat visible on scan.
Serum hCG level ≥ 1000 IU/L.

A laparoscopic approach is preferable. A salpingectomy should be performed, unless the woman has other risk factors for infertility, in which case a salpingotomy should be undertaken].

[If HCG >6000 IU/L and an intrauterine gestational sac is not seen on trans-abdominal US, ectopic pregnancy is very likely, as is the case if HCG $1000-1500$ IU/L and no sac is seen on transvaginal Ultrasound].

1270. A 23yo woman who has had several recent partners has experienced post-coital bleeding on gentle contact. What is the single most likely cause of her vaginal discharge?

- a. Cervical ca
- b. Cervical ectropion
- c. CIN
- d. Chlamydial cervicitis
- e. Gonococcal cervicitis

Ans. D. Chlamydia cervicitis.

1271. A 68yo woman presents with post-coital bleeding following her first episode of sexual intercourse in 10yrs. What is the single most likely cause that has led to post-coital bleeding?

- a. Endometrial ca
- b. Atrophic vaginitis
- c. Endometrial polyp
- d. Cervical ca
- e. Cervical ectropion

Ans. The key is B. Atrophic vaginitis.

1272. A 28yo woman 8wks GA had PID treated prvly and now comes with vaginal bleeding, rigid abdomen, BP=80/50mmHg, pulse=140bpm. What is the most probable dx?

- a. Threatened abortion
- b. Miscarriage
- c. Missed abortion
- d. Tubal pregnancy
- e. Inevitable abortion

Ans. The key is D. Tubal pregnancy. [Previous PUD is a risk factor for tubal pregnancy].

1273. A 34yo primigravida who is 16wk GA comes for routine antenatal check up. Her BP=160/100mmHg. She has a hx of repeated childhood UTI. What is the most likely cause of her high BP?

- a. Essential HTN
- b. Chronic pyelonephritis
- c. Acute pyelonephritis
- d. Pre-eclampsia
- e. Chronic UTI

Ans. The key is B. Chronic pyelonephritis. [35% of childhood UTI is associated with VUR and many of them develop renal scarring and chronic pyelonephritis causing hypertension].

1274. A 24yo woman has had lower abdominal pain for 12h. She is otherwise well. She is at 10wks GA in a planned pregnancy. What is the single most appropriate test to inv the cause of acute abdomen in this lady?

- a. Abdominal US
- b. Anti-phospholipid screen
- c. CBC
- d. Transvaginal US
- e. Laparoscopy

Ans. The key is D. Transvaginal US. [D/D: ectopic pregnancy, renal colic, torsion of ovarian cyst, appendicitis etc. Transvaginal US will give better results in case of lower abdominal pain].

1275. A pt is at term and in labor, the membranes have ruptured, the liquor contains meconium but the CTG is normal. The cervix is 3cm dilated. What is the single most appropriate action?

- a. BP monitoring
- b. CTG
- c. C-section
- d. Fetal scalp blood sample
- e. Internal rotation

Ans. The key is D. Fetal scalp blood sample. This is wrong key. Correct key is CTG. [Till CTG is normal we should not switch to other option but continuing CTG. If CTG shows fetal distress then we have to do fetal scalp blood sampling to take decision about probable cesarean section. (Only abnormal CTG is not enough to take decision of cesarean section)].

1276. A pt is at term and labor. The head has been delivered and you suspect shoulder dystocia. What is the single most appropriate action?

- a. C-section
- b. Episiotomy
- c. External rotation
- d. Fetal scalp blood sample
- e. Instrumental delivery

Ans. The key is B. Episiotomy.

1277. A 29yo female at 28wks GA presents to you with complains of hard stools and constipation for last 2wks. CTG shows fetal tachycardia. What is the single most appropriate tx?

- a. Oral laxatives
- b. Fiber diet
- c. Phosphate enema
- d. Lactulose
- e. Reassure

Ans. The key is B. Fiber diet. [Changes to diet and lifestyle are often recommended as the first treatment for constipation. It includes high fiber diet and plenty of fluid, regular exercise etc.].

1278. A 16yo girl presents with heavy bleeding. What is the most appropriate initial inv?

- a. Endometrial sampling
- b. Transvaginal US
- c. Hysteroscopy
- d. Pelvic US
- e. Exam under anesthesia

Ans. The key is D. Pelvic US. [Pelvic or transvaginal ultrasound are same thing].

1279. A woman who is 7wks pregnant presents with excessive and severe vomiting and put on IV fluids and anti-emetic (ondansetron). She is complaining of severe headache and can't take oral fluids. What is the most appropriate management?

- a. Termination of pregnancy
- b. TPN
- c. Feeds via NGT
- d. P6 acupressure
- e. IV hydrocortisone

Ans. The key is A. Termination of pregnancy. This is wrong key. Correct key is E. IV hydrocortisone. [Termination is the last resort! Before it IV hydrocortisone is tried. 1st oral antiemetics if fail parenteral antiemetics if fail iv hydrocortisone. Last resort is termination].

1280. A young lady with primary amenorrhea has normal LH, FSH, estradiol and prolactin. Choose the single most likely dx?

- a. PCOS
- b. POF
- c. Absent uterus
- d. Absent ovaries
- e. Turner's syndrome

Ans. The key is C. Absent uterus. [Normal LH, FSH, estradiol and prolactin rule out PCOS (increased LH, increased FSH, normal oestrogen. LH:FSH ratio is 2:1 or 3:1), POF (in POF, LH & FSH raised, FSH > 20 IU/L), Absent ovary will lead to low estradiol, high FSH and LH, Turner's syndrome: gonadal streaks, as absent ovaries].

1281. An obese lady presents with primary amenorrhea. She has high LH, normal FSH and slightly high prolactin levels. Choose the single most likely dx?

- a. PCOS
- b. POF
- c. Hypothyroidism
- d. Pregnancy
- e. Primary obesity

Ans. The key is A. PCOS. [High LH, high or normal FSH with slight rise in prolactin levels in an obese lady is suggestive of PCOS].

1282. A 38yo lady presents with amenorrhea has very high LH and FSH levels, normal prolactin and low estradiol. Choose the single most likely dx?

- a. PCOS
- b. POF
- c. Hypothyroidism
- d. Pregnancy
- e. Menopause

Ans. The key is B. POF. [High LH and FSH, normal prolactin and low estrogen in secondary amenorrhea in a lady under age 40 is highly suggestive of POF].

1283. A 77yo publican was admitted for an appendectomy. Post-op he becomes confused, agitated and starts to pick at things. He is then given an IV drug which settles this confusion. Which of the following drugs was given for his confusion?

- a. Diazepam
- b. Chlordiazepoxide
- c. Thiamine
- d. Vit B

Ans. The key is B. Chlordiazepoxide. This is a wrong key! Correct key is A. Diazepam. [Patient is alcoholic. On admission abstinence from alcohol caused this withdrawal symptom. Agitation, confusion and pick at things are suggestive of delirium tremens which is treated with Diazepam].

1284. A 65yo lady presents with dyspareunia. What will you give her for her condition?

- a. HRT
- b. COCP
- c. Estrogen gel
- d. Testosterone gel

Ans. No key is given. Likely key is C. Estrogen gel. [Seems to be atrophic vaginitis for which estrogen gel can be given].

1285. A 35yo lady with subserosal fibroid=4cm and submural fibroid=6cm is planning for a child. Which way will you remove the fibroids?

- a. Laparoscopy
- b. Vaginal myomectomy
- c. Abdominal myomectomy
- d. Drugs
- e. Reassure

Ans. The key is B. Vaginal myomectomy. Probably wrong key! Correct key should be C. Abdominal myomectomy. [Subserosal fibroid is not suitable to treat through vaginal route. Abdominal myomectomy can deal with both subserosal and submural fibroid].

1286. A 32yo presents with heavy blood loss, US: uterine thickness>14mm. What is the best possible management for her?

- a. COCP
- b. UAE
- c. Hysteroscopy myomectomy
- d. Abdominal myomectomy
- e. Endometrial ablation

Ans. B. UAE. [COCP will not resolve the case. There is no fibroid so no myomectomy. Endometrial ablation may render the young lady non fertile. So UAE is the only suitable option here].

1287. A pt comes with sudden loss of vision. Exam: high BP. Fundoscopy: retina appears swollen. Which blood vessel occlusion is involved?

- a. Branch RVO
- b. Branch RAO
- c. CRAO
- d. CRVO

Ans. The key is D. CRVO.

1288. A 2yo girl has had a temp=39C, poor appetite, abdominal pain and urinary frequency for 3d. What is the single most appropriate inv?

- a. Catheter specimen of urine for culture
- b. Clean catch urine specimen for culture
- c. CBC
- d. KUB US
- e. Supra-pubic aspirate of urine for culture

Ans. The key is B. Clean catch specimen of urine for culture.

1289. A child with T1DM who is not compliant with meds and eats a lot. He thinks that he is short in his class. He is not happy. What would you do next?

- a. Refer to psychologist
- b. Refer to pediatrician
- c. Refer to GP
- d. Refer to social services
- e. Change type of insulin

Ans. The key is A. Refer to psychologist. [Not compliant with medicine, eating a lot, thinking of being short and being unhappy these are psychological issues. So he should be referred to psychologist].

1290. An 8yo boy with a BMI=28 was admitted to a surgical ward following a MVC. He was found to have glycosuria. When he recovered from his injury the glycosuria resolved. What is the single most appropriate follow-up inv?

- a. Fasting blood glucose conc
- b. Glycosylated hemoglobin - HbA1c
- c. OGTT
- d. Random blood glucose conc
- e. Serum cortisol conc

Ans. The key is A. Fasting blood glucose concentration. [The boy had glycosuria while treating in hospital following a MVC (motor vehicular crash). It may be due to stress related cortisol release causing hyperglycemia which later became nil as the boy recovered from trauma. But yet to certain that he is not diabetic fasting blood glucose concentration should be done in follow up visit].

1291. At birth, a baby boy at 38wks GA weighs 1.8kgs. He has hepato-splenomegaly and a rash. Blood test show raised level of bilirubin and liver enzymes. What is the most likely dx?

- a. Galactosemia
- b. Biliary atresia
- c. G6PD deficiency
- d. Rh incompatibility
- e. Congenital viral infection

Ans. The key is E. Congenital viral infection. [Congenital infections affect the unborn fetus or newborn infant. They are generally caused by viruses that may be picked up by the baby at any time during the pregnancy up through the time of delivery. The more common viruses linked to congenital infections include the Cytomegalovirus (CMV), Herpes, Rubella (German measles), Parvovirus, Varicella (chickenpox), and Enteroviruses].

1292. A 12yo boy with T1DM has poor long-term control. He is unconscious, hyperventilating and dehydrated. His blood glucose is 28mmol/l. What is the single most imp initial tx?

- a. Albumin IV
- b. Bicarbonate IV
- c. Insulin IV
- d. Insulin SC
- e. Saline 0.9% IV

Ans. The key is E. Saline 0.9% IV. [Probable diabetic ketoacidosis. Initial treatment is IV fluid (0.9% saline)].

1293. A 30yo woman on OCP presents with dilated tortuous veins crossing her abdomen to join the tributaries to SVC. What is the single most likely cause?

- a. Intra-abdominal malignancy
- b. Ovarian cyst
- c. Fibroids
- d. Ascites
- e. DVT

Ans. The key is E. Intra-abdominal malignancy. This is wrong key. Correct key is E. DVT. [IVCT (inferior vena caval thrombosis) is well known to occur secondary to DVT leading to dilated tortuous veins crossing the abdomen to join the tributaries to SVC].

1294. An 84yo woman with drusen and yellow spots in the center of retina. What is the single most likely dx?

- a. Macular degeneration
- b. HTN retinopathy
- c. MS
- d. DM background
- e. Proliferative DM retinopathy

Ans. The key is A. Macular degeneration. [In early disease, the macula shows yellowish-colored subretinal deposits called "drusen"].

1295. A pt presents with headache, blurring of vision and acuity loss. On fundoscopy, dots and blots were noted with huge red swollen optic disc. What is the most probable dx?

- a. CRAO
- b. Branch RAO
- c. CRVO
- d. Optic atrophy

Ans. The key is C. CRVO.

1296. A 64yo DM has come for a routine eye check up. Fundoscopy: new vessels all over the retina. What is the most appropriate management?

- a. Strict sugar control
- b. Regular eye check ups
- c. Non urgent referral to specialist
- d. Laser photocoagulation
- e. Insulin

Ans. The key is D. Laser photocoagulation. [Neovascularization suggests proliferative diabetic retinopathy which is treated with laser photocoagulation].

1297. A 25yo primigravida of 8wk GA presents with severe lower abdominal pain, vaginal bleeding and passage of clots. The internal os is open. What is the most likely dx?

- a. Appendicitis
- b. Placental abruption
- c. Ectopic pregnancy
- d. Abortion

Ans. The key is abortion. [Up to 24 weeks termination of pregnancy is abortion. Ref: patient.info]

1298. A man developed intense pain after using the end of a pencil to scratch his inner ear. He took out the pencil from his ear and realized the end of the pencil with the rubber part is still stuck in his ear. What is the most appropriate management?

- a. Remove with a hook
- b. Instill olive oil
- c. Remove GA
- d. Remove with magnet instrument
- e. Do syringing

Ans. The key is A. Remove with a hook. [Place a hook behind the object and pull it out].

1299. A 16yo boy presents with acute pain in the right ear and little bleeding from the same ear. He had been in a boxing match and had sustained a blow to the ear. There is little amount of blood in the auditory canal and a small perforation of the eardrum. What is the most appropriate management?

- a. Admission for parental antibiotics
- b. Nasal decongestant
- c. Oral amoxicillin
- d. OPD review
- e. Packing of ear
- f. Surgical intervention
- g. Syringing ENT

Ans. The key is C. Oral amoxicillin. [Small perforations are usually heal by themselves within 6-8 weeks and doctors often prescribe antibiotics to prevent infections during this healing period].

1300. A 45yo man has noticed difficulty hearing on the telephone. He is concerned because his father has been moderately hard of hearing since middle age. BC=normal. An audiogram shows moderate hearing loss in both ears across all frequencies. What is the single most likely dx?

- a. Acoustic neuroma
- b. Meniere's disease
- c. Noise induced deafness
- d. Otosclerosis
- e. Presbycusis

Ans. The key is D. Otosclerosis. [This patient has conductive hearing loss. So it is not acoustic neuroma. a. Meniere's disease has symptoms like vertigo, tinnitus, fullness, along with hearing loss. There is no history of noise pollution not presbycusis as his age is 45. So his deafness fits more with otosclerosis. These are by exclusion. Points in favour of otosclerosis: i) Conductive hearing loss. ii) Age of 45 yrs iii) Moderate hearing loss in both ears across all frequencies].

1301. The biological parents of a child with CF come to you to know about the chances of their future children with the same disease. What would you say to them?

- a. There is a 1:4 chance that your future child will have this disease
- b. All their unaffected children will be carriers of CF
- c. Nothing can be predicted
- d. It can 100% dx antenatally

Ans. The key is A. There is a 1:4 chance that your future child will have this disease. [It is autosomal recessive disease. As one child is affected both parents are carrier. So in this case next child will be normal in 1:4 case, carrier in 1:2 cases and diseased in 1:4 cases].

1302. A 14yo boy presents with recurrent abdominal pain, malaise and weight loss over 6m. Exam: vague mass is felt in RIF. Colonoscopy shows transmural inflammation and granulomata. What is the most appropriate management?

- a. Sulfasalazine
- b. Paracetamol
- c. Metronidazole
- d. Ibuprofen

Ans. The key is C. Metronidazole. It is a wrong key. Correct key should be A. Sulfasalazine. [Drug of 1st preference is Steroids, then immuno-suppressants, then aminosalicylates (such as sulfasalazine). Metronidazole is used if there is infective complications like infected perianal fistula Ref: patient.info].

1303. A 62yo prv shipyard worker complains of breathlessness and chest pain for 6m. He has now developed a large pleural effusion. Which is the single best diagnostic inv?

- a. ABG
- b. Bronchoscopy
- c. CXR
- d. Pleural biopsy
- e. Transfer factor

Ans. The key is D. Pleural biopsy. [Shipyard worker is exposed to asbestos and the likely diagnosis here is mesothelioma for which single best investigation is pleural biopsy].

1304. A 67yo man presents with a hx of increasing confusion and drowsiness. He had a fall 2wk ago. CT head reveals a chronic subdural hematoma. What is the best management for this pt?

- a. Craniotomy
- b. Burr hole drainage
- c. Conservative management
- d. Excision and biopsy

Ans. The key is B. Burr hole drainage.

1305. A 45yo male with epigastric discomfort has been given triple therapy. He has now returned after 4wks of epigastric discomfort. What inv would you do for him?

- a. ECG
- b. H.pylori breath test
- c. Endoscopy and biopsy
- d. US

Ans. The key is C. Endoscopy and biopsy. This is a wrong key! Correct key is B. H. pylori breath test.

1. If H. Pylori test is positive then eradicate H. Pylori and review after 4 weeks.

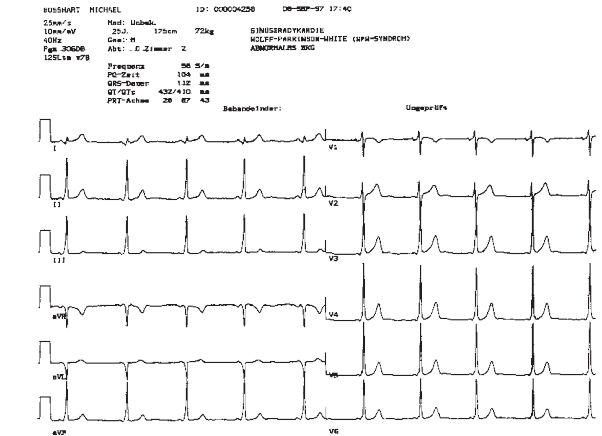
- If symptoms resolve then no further action required.
- If symptoms persist then do a urea breath test.
- If this is positive then continue H. Pylori eradication.
- If this is negative then consider UGI endoscopy.

1306. A 13yo boy with umbilical pain for the last 12h presents with anorexia, nausea and has not passed a bowel motion 24h. What is your dx?

- a. Acute appendicitis
- b. IBD
- c. IBS
- d. Meckel's diverticulum
- e. Muscle strain
- f. Ovarian cysts
- g. PID
- h. Psoas hematoma
- i. Pyelonephritis
- j. Uretric calculus

Ans. The key is D. Meckel's diverticulum. This is wrong key. Correct answer is A. Acute appendicitis.

1307. A 46yo man with tachycardia has the following ECG. What is the most likely dx?



- a. SVT
- b. VT
- c. Mobitz I heart block
- d. Atrial fibrillation
- e. WPW syndrome

Ans. The key is E. WPW syndrome. [Short PR interval and slurred delta wave indicates WPW syndrome].

1308. A 24yo male is admitted with acute severe asthma. Tx is initiated with 100% oxygen, nebulized salbutamol and ipratropium bromide nebulizers and IV hydrocortisone. Despite initial tx there is no improvement. Which is the next step in management?

- a. IV aminophylline
- b. IV magnesium sulphate
- c. IV salbutamol
- d. IM adrenaline
- e. IV adrenaline

Ans. The key is B. IV magnesium sulphate.

1309. A 49yo man first presented with increasing difficulty in swallowing. Several months later he developed weakness in his right foot. Now he can no longer feed himself, he chokes on food and has become confined to a wheelchair. What is the most likely dx?

- a. Cerebral tumor
- b. Myasthenia gravis
- c. Lambert-Eaton syndrome
- d. Motor neuron disease
- e. Cerebro-vascular disease

Ans. The key is D. Motor neuron disease. [The picture is of amyotrophic lateral sclerosis (ALS)].

trophic lateral sclerosis with bulbar onset, so it has very bad prognosis].

1310. A 10yo boy with lower abdominal pain for the last 10d presents with a hx of passing 6-8 loose stools. Temp=38.8C. He is tender in the right lower quadrant and has an anal fistula. Choose the single most likely cause of abdominal pain.

- a. IBD
- b. IBS
- c. Pyelonephritis
- d. Uretric calculus
- e. Gastroenteritis

Ans. The key is A. IBD. [Likely diagnosis is crohn's disease which is often associated with perianal fistula formation].

1311. A 28yo woman with hx of drug addiction wants to start a family and have a baby. She would like to stop taking heroin and asked for something to help her stay away from it. What drug tx would you give her?

- a. Naloxone
- b. Acamprosate
- c. Methadone
- d. Chlordiazepoxide
- e. Naltrexone

Ans. The key is C. Methadone. [Methadone is a powerful synthetic analgesic drug which is similar to morphine in its effects but less sedative and is used as a substitute drug in the treatment of morphine and heroin addiction].

1312. A pt with vesicles in the maxillary division of trigeminal nerve. Which area of mucus membrane will be involved?

- a. Palate
- b. Cheek
- c. Cornea
- d. Conjunctiva

Ans. The key is B. Cheek. [It also involve soft palate but not hard palate. So cheek is more complete answer than palate. Conjunctiva is more affected in ophthalmic division of trigeminal nerve].

1313. A 52yo man presents with visual hallucinations and features of cognitive impairment. What is the most likely dx?

- a. Frontotemporal dementia
- b. Lewy body dementia
- c. Delirium tremens
- d. Alzheimer's disease
- e. Huntington's disease

Ans. The key is B. Lewy body dementia. [Visual hallucinations and cognitive impairment are suggestive of Lewy body dementia. Hallucination is prominent feature of LBD than Alzheimers. Again cognitive impairment goes more with LBD while prominent early memory loss symptom suggests Alzheimer's].

1314. A 40yo woman who has recently returned from working in the middle east complains of thirst, episode of loin pain, urinary frequency, dysuria and has passed a urinary stone. All inv are normal. She plans to return to the Middle East in a month's time. What is the single best advice to prevent recurrent stone formation?

- a. Drink less milk
- b. High fibre diet
- c. Increase fluid intake
- d. Low calcium diet
- e. Low protein diet

Ans. The key is C. Increased fluid intake. [Risk factors for renal stones include being overweight, certain foods, some medications, and not drinking enough fluids].

1315. A 32yo man presents with 3d of scrotal pain. Exam: thickening of the left testis and it is hot to touch. What is the most appropriate management?

- a. Analgesia
- b. Reassurance
- c. Antibiotics
- d. Referral to surgeon

Ans. The key is C. Antibiotics. [scrotal pain of 3 days with thickening of testis which is hot to touch suggests epididymo-orchitis, which is treated with antibiotics].

1316. A 34yo woman presents with truncal obesity, easy bruising, hyperglycemia, high BP and depression. Which of the following inv's will be most helpful in localizing the cause for Cushing's syndrome?

- a. Serum cortisol
- b. 24h urinary cortisol
- c. Low dose dexamethasone suppression test
- d. High dose dexamethasone suppression test
- e. Overnight dexamethasone suppression test

Ans. The key is D. High dose dexamethasone suppression test. [High dose dexamethasone suppression test can identify whether pituitary adenoma or ectopic ACTH producing tumour].

1317. A 32yo man develops hematuria 2wks after a sore throat. What is the dx?

- a. Post infection nephritis
- b. IgA nephropathy
- c. Membranous nephritis
- d. Glomerulonephritis

Ans. The key is A. Post infection nephritis. [Hematuria 2 wks after sorethroat indicate post infection nephritis while hematuria after few days of sorethroat indicate IgA nephropathy].

1318. An elder man who has anorexia, prostate symptoms and HTN. There are small kidneys on US. What is the dx?

- a. Hypertensive renal disease
- b. Prostate ca
- c. BPH

Ans. The key is A. Hypertensive renal disease. [Small kidneys suggest chronic renal failure and uremia here is the cause of anorexia. As elder he may have associated prostate symptoms from concomitant BPH].

1319. A 55yo woman with breast ca which has spread to lung, liver and bone now presents with increasing constipation, weakness, thirst and anorexia for the past 3d. Her only medication is haloperidol for hiccoughs. Today she is disorientated and has left sided weakness. What is the most likely dx?

- a. Brain mets
- b. Hypercalcemia
- c. Liver failure

Ans. The key is A. Brain mets. [The patient has clinical hypercalcemia, but the neurological features of disorientation and left sided weakness

can only be explained with brain metastasis].

1320. A 22yo man presents with a red, hot, swollen, metatarsal phalangeal joint, sarcoilitis and onycholysis. What is the single most likely cause of his condition?

- a. Gout
- b. RA
- c. Reiter's syndrome
- d. Psoriatic arthropathy

Ans. The key is D. Psoriatic arthropathy. [Psoriatic arthritis initially can affect the toes very similar to gout. There can be sacroilitis and onycholysis. Ref: patient.info].

1321. Which of the following conditions requires operative management?

- a. Cellulitis
- b. Dyshidrosi
- c. Erysipelas
- d. Fournier's gangrene
- e. Lymphangitis

Ans. The key is D. Fournier's gangrene. [Fournier's gangrene: A horrendous infection of the genitalia that causes severe pain in the genital area (in the penis and scrotum or perineum) and progresses from erythema (redness) to necrosis (death) of tissue. Gangrene can occur within hours].

1322. A 55yo pt presents with collapse and complains of abdominal pain that radiates to the back. An expansile abdominal mass is felt on examination and the pt is in shock. What is the single most likely dx?

- a. Ruptured aortic aneurysm
- b. Renal colic
- c. Trauma
- d. Endocarditis
- e. Atheroma

Ans. The key is A. Ruptured aortic aneurysm.

1323. A house-bound 78yo man with severe COPD has had a gradual deterioration over recent months and is now breathless at rest. He is on maximal inhaled medical therapy. Result: pH=7.36, PaCO₂=5.9kPa, PaO₂=6.9kPa. What is the single most appropriate additional tx?

- a. Aminophylline PO
- b. ACEi PO
- c. Antibiotic PO
- d. Oxygen
- e. Steroid PO

Ans. The key is D. Oxygen. [In patients with chronic hypoxaemia, LTOT should usually be prescribed after appropriate assessment, when the PaO₂ is consistently at or below 7.3 kPa (55 mm Hg) when breathing air during a period of clinical stability. Clinical stability is defined as the absence of exacerbation of chronic lung disease for the previous five weeks. The level of PaCO₂(which may be normal or elevated) does not influence the need for LTOT prescription].

1324. A 79yo man has a swelling of the right groin which was clinically dx to be indirect inguinal hernia. What is the single feature of the hernia sac that would confirm the dx?

- a. Comes through femoral ring
- b. Doesn't pass through the deep inguinal ring
- c. Lies below and lateral to the pubic tubercle
- d. Only passes through the superficial inguinal ring
- e. Passes through the deep inguinal ring

Ans. The key is E. Passes through the deep inguinal ring. [Inguinal hernia lies mostly above and medial (occasionally lateral particularly when small) to pubic tubercle. It first enters the inguinal canal through deep inguinal ring and then enters the scrotum through the superficial inguinal ring].

1325. A 56yo woman with hx of breast cancer 10y ago has undergone radical mastectomy and axillary LN removal, now complains of swollen upper limb 3wks after an insect bite. The bite site is better but gross edema is still present. What is the cause?

- a. Lymphedema
- b. Breast Ca
- c. Allergy
- d. Filariasis

Ans. The key is A. Lymphedema. [As during mastectomy axillary clearance is done, lymphatics on that upper limb is compromised. So there occurs lymphedema].

1326. A homeless person is found wandering on the street. He had ataxic gait, nystagmus and ophthalmoplegia. He looked unkempt and his clothes had a sweaty odour. He had a dry mucous membrane with a BP=118/70mmHg and PR=90bpm. Blood sugar level=8. Alcohol breath test= - ve. What would the most imp initial inv?

- a. IV insulin
- b. Vit B complex
- c. Bolus IV 0.9%NS
- d. IV dextrose
- e. Antibiotics

Ans. The key is B. Vit B complex. [This is wernicke's encephalopathy

due to alcohol withdrawal, so Vit B complex should be given. This occurs mainly due to thiamine deficiency].

1327. A 34yo man has supra-orbital pain and tenderness and developed tenderness over the maxilla. He also has mild fever. What is the single likely cause for these symptoms?

- a. Acute sinusitis
- b. GCA
- c. Trigeminal neuralgia
- d. Maxillary carcinoma

Ans. The key is A. Acute sinusitis. [There is supraorbital pain in frontal sinusitis and tenderness over maxilla in maxillary sinusitis. Also mild fever may present in acute sinusitis].

1328. A 51yo woman presents with painful tongue and complains of tiredness. She is pale and has angular stomatitis and a smooth red tongue. There is no koilonychia. Choose the single cell type you will find on the blood film.

- a. Numerous blast cells
- b. Oval macrocytes
- c. Spherocytes
- d. Microcytic hypochromic
- e. Mexican hat cells
- f. Erythrocytes

Ans. The key is B. oval macrocytes. [Macrocytes are two types, round and oval. Oval macrocytes are seen in megaloblastic anemia which occurs due to Vit B12 and/or folic acid deficiency. Glossitis (painful tongue), angular stomatitis and smooth tongue are though characteristic feature of iron deficiency but also known feature of megaloblastic anemia. Absence of koilonychia also favours megaloblastic anemia].

1329. A 24yo woman presents with tingling and twitching of her fingers followed by throbbing unilateral headache. What is the most likely dx?

- a. Tension headache
- b. Migraine
- c. Cluster headache
- d. TIA
- e. SAH

Ans. The key is B. Migraine. [The tingling and twitching of her fingers are aura and the migraine is with aura].

1330. A young child dx with chicken pox. Usually goes to day care. What is the most appropriate advice?

- a. Child should be admitted to hospital straight away
- b. Isolate the child from parents and siblings at home
- c. Advice that he can go back to nursery when the rash is crusted over

Ans. The key is C. Advice that he can go back to nursery when the rash is crusted over. [At this stage patient is no more infectious].

1331. A 7yo boy is brought by his mother. There are multiple perioral and forehead vesicles. Some vesicles are crusted and some are not. The face is hot. What is the most likely dx?

- a. Varicella zoster
- b. Herpes zoster
- c. Fungal infection
- d. Impetigo
- e. Psoriasis

Ans. The key is B. Herpes zoster. This is a wrong key! Correct key is D. Impetigo. [Distribution of varicella zoster (chickenpox) is centripetal that is mainly on trunk. Impetigo is mostly occurs centrifugally that is more on face and limbs. Impetigo also has characteristic of yellow or honey coloured scrub. Herpes zoster usually occurs in elderly and unlikely to occur in children].

1332. A 5yo boy is rescued from a burning building and is presented to the ED. He has 5% partial thickness burns over the arms and legs and had soot in the mouth and nose. His breathing has become noisy. What is the single most immediate management?

- a. Nebulized adrenaline
- b. Nebulized salmeterol and oxygen
- c. Needle cricothyrotomy
- d. Oropharyngeal airway
- e. Intubation of airway

Ans. The key is E. Intubation of airway. [Soot in the mouth and nose and noisy breathing occurs in inhalation injury where intubation of the airway is indicated].

1333. A new born baby is brought with pansystolic murmur at sternal border but the baby is not cyanosed. What is the dx?

- a. VSD
- b. ASD
- c. TOF
- d. PDA

Ans. The key is A. ventricular septal defect. [Pansystolic murmur in sternal border without cyanosis is indicative of VSD].

1334. A woman complaining of diarrhea, abdominal pain and fatigue. All the tests are found to be normal. What is the cause?

- a. Somatization
- b. Conversion
- c. Hypochondriasis

Ans. The key is A. Somatization. [Somatization disorder is patients presenting with any physical symptom and frequent medical visits in spite of negative investigations].

1335. A 26yo man has returned from NY to the UK and noticed weight loss, night sweats, temp=37.5C and cervical lymphadenopathy. He also has splenomegaly. What is the dx?

- a. TB
- b. Lymphoma
- c. Bronchial carcinoma
- d. Bronchitis

Ans. The key is B. Lymphoma.

1336. A mother got infected with Hep B during pregnancy. Her child is born and she is worried about the risk of infection to the baby with Hep B. What would you give to the baby?

- a. Hep B Ig only
- b. Hep B full vaccine and Ig
- c. Hep B vaccine only once
- d. Nothing until immune status is checked
- e. Hep B vaccine once and Ig

Ans. The key is B. Hepatitis B full vaccine and Ig.

1337. A man suffers from Herpes Zoster affecting his face. Which of the following mucous membrane is to be affected?

- a. Cheek
- b. Cornea
- c. Conjunctiva
- d. Oropharynx
- e. Palate

Ans. The key is C. Conjunctiva.

1338. A 34yo man sustains a fx to shaft of femur after falling from the roof of his house. Exam: distal pulses are not palpable. Which vessel is damaged?

- a. Femoral artery
- b. Circumflex femoral artery
- c. Profundafemoris artery
- d. Popliteal artery
- e. Obturator artery
- f. Dorsalispedis artery

Ans. The key is A. Femoral artery.

1339. A 9yo child doesn't play with his peers and has collected 200 cars. He doesn't respond to any criticism. What is the dx?

- a. Autism
- b. Personality disorder
- c. Schizophrenia
- d. Rett syndrome
- e. Social anxiety

Ans. The key is A. Autism.

1340. A 63 yo man with vague but persistent pain. On endoscopy: columnar epithelium was found to be pouched into muscularis. What is the dx?

- a. Adenocarcinoma
- b. Adenoma
- c. Peptic ulcer
- d. H. pylori infection

Ans. The key is A. Adenocarcinoma.

1341. A 24yo man after a head injury presents with difficulty dressing himself, difficulty in writing and inability to differentiate the fingers of his hand. Which part of the brain is most likely to be affected?

- a. Frontal lobe
- b. Parietal lobe
- c. Temporal lobe
- d. Occipital lobe
- e. Brainstem

Ans. The key is B. Parietal lobe. [Dressing apraxia, agraphia and finger agnosia are features of parietal lobe lesions].

1342. A 16yo boy in boarding school feels unwell. He developed cough and rash. His CXR showed bilateral consolidations. What is the cause of his symptoms?

- a. Staph aureus
- b. Legionella
- c. Mycoplasma
- d. Streptococcus

Ans. The key is C. Mycoplasma. [Rash, bilateral consolidation favours mycoplasma pneumonia. Mycoplasma is common in military barrack, prison or boarding dwellers].

1343. A 10yo boy is brought to the ED 10h after injury to the foot. It was punctured with a metal spike that passed through his shoe. What is the next best step?

- a. Ig
- b. Ig and vaccine
- c. Vaccine only
- d. Clean the wound
- e. Antibiotics

Ans. The key is D. Clean the wound. ["NEXT" best step is clean the wound].

1344. A 56yo male presents with persistent watery diarrhea. What is the most likely dx?

- a. Treponema pallidum
- b. Nesseria meningitides
- c. Cryptosporidium
- d. Staph aureus
- e. Pseudomonas aeruginosa

Ans. The key is C. Cryptosporidium.

1345. A 2yo girl has frequency, urgency and burning micturition. She has some supra pubic tenderness. Which one of the following is the most appropriate initial inv?

- a. Supra pubic aspiration of urine for C&S
- b. Clean catch of urine for C&S
- c. USG
- d. IVU
- e. MCUG

Ans. The key is B. Clean catch of urine for C&S. [The features are consistent with lower UTI for which clean catch of urine for c&s should

be done].

1346. An 89yo man presents with carcinoma of posterior oropharynx. Which is the single most appropriate LN involved?

- a. Pre-aortic LN
- b. Aortic LN
- c. Submental LN
- d. Submandibular LN
- e. Deep cervical LN

Ans. The key is E. Deep cervical LN.

1347. A young boy presented to the OPD 12wks after renal transplantation with fever and pain in lower abdomen. Renal functions were deranged. Renal biopsy showed immune cell infiltrate and tubular damage. What is the most probable dx?

- a. Pyelonephritis
- b. Chronic graft rejection
- c. Acute rejection
- d. Drug toxicity
- e. Graft vs host disease

Ans. The key is C. Acute rejection. [Acute rejection usually occurs in the first few months after transplant, but may occur up to a year after transplant. Features presented are typical of acute graft rejection].

1348. A 56yo lady presents with a pathological fx of T11 vertebra. There is found to be an underlying metastatic lesion. What is her most common primary ca?

- a. Lung
- b. Breast
- c. Uterine
- d. Brain

Ans. The key is B. Breast. [In female breast and lung cancer and in male prostate and lung cancer are most common to metastasize to bone].

1349. A 6m infant has breast milk jaundice. He is otherwise feeding well and is not dehydrated. What would his LFTs look like?

- a. Total bilirubin:40, conjugated bilirubin<5%
- b. Total bilirubin:300, conjugated bilirubin 85%
- c. Total bilirubin:500, conjugated bilirubin>85%
- d. Total bilirubin:400, conjugated bilirubin<85%

Ans. The key is A. Total bilirubin:40, conjugated bilirubin<5%. [Brest milk jaundice is characterized by indirect hyperbilirubinemia].

1350. A 29yo man took a tour of Japan and also travelled to other parts of Asia, developed fever, petechie and rash on his body. He didn't take malaria prophylaxis prior to travel. What is the most likely dx?

- a. Malaria
- b. HSP
- c. HIV
- d. Dengue fever
- e. ITP

Ans. The key is D. Dengue fever.

1351. A 4yo boy ingested his grandmother's medicine and has developed dilated pupil. What is the cause?

- a. Amitryptiline
- b. Paracetamol
- c. Iron
- d. Digoxin

Ans. The key is A. Amitryptiline. [TCA causes mydriasis].

1352. A 46yo male presents with confusion and drowsiness. What is the most likely dx?

- a. Cryptococcus neoformans
- b. Toxoplasma gondii
- c. HSV
- d. CMV
- e. Candida albicans

Ans. The key is A. Cryptococcus neoformans. [This type of question can be regarded as CNS infection in AIDS and some may argue there is no mention of AIDS. If you consider with immunocompetent patient likely answer may be HSV and if you consider immunodeficiency likely answer is controversial! as some say toxoplasmosis as the most common and some say Cryptococcus is most common].

1353. A child has developed rash after the tx of penicillin. What will be the cause of rash?

- a. Drug reaction
- b. Kawasaki
- c. Inf Mono

Ans. The key is A. Drug reaction.

1354. A child comes with recurrent joint pain, multiple bruises, swollen ankle and unable to move his legs. What is the inv of choice?

- a. ESR
- b. RF
- c. Clotting factors

Ans. The key is C. Clotting factors. [Probable diagnosis is hemarthrosis with the disease hemophilia].

1355. A 66yo man has renal colic. He has also presented with acute onset pain in his knee in the past. What is the single most likely cause for renal failure?

- a. SLE associated GN
- b. Hypercalcemia
- c. HTN
- d. Hyperuricemia
- e. Hyperoxaluria

Ans. The key is D. hyperuricemia. [Knee pain is due to gout and renal colic may occur from uric acid stone (urate stone)].

1356. A boy with a hx of recurrent swollen tender joints on both knees and elbows and not able to participate in sports. What is the inv of choice to dx?

- a. RF/ASO titre
- b. Clotting factor
- c. ESR

Ans. The key is B. Clotting factor. [Haemarthrosis causing disability].

1357. A 26yo man is referred for gastroscopy because of a hx of several months of dyspepsia. He has routine bloods checked and is found to have a serum calcium level=3.2mmol/l with a venous bicarbonate level of 33mmol/l. Renal and LFT are both normal. CXR is normal. What is the most likely cause of his hypercalcemia?

- a. Melanoma
- b. Metastatic malignancy
- c. Milk alkali syndrome
- d. Primary hyperparathyroidism
- e. Sarcoidosis

Ans. The key is C. Milk alkali syndrome. [In medicine, milk-alkali syndrome is characterized by high blood calcium caused by taking in

too much calcium and absorbable alkali; common sources of calcium and alkali are dietary supplements taken to prevent osteoporosis and antacids. If untreated, milk-alkali syndrome may lead to kidney failure or death].

1358. A 3yo boy presents with difficulty in walking and skin lesions. What is the most likely causative agent?

- a. Strep pyogenes
- b. Rubella virus
- c. Parvovirus
- d. Papovirus
- e. Paramyxovirus

Ans. The key is C. Parvovirus. [Sometimes there may occur arthropathy for which children gets difficulty to walk. There occurs macular morbilliform rash in parvovirus infection following disappearance of rash of the cheeks].

1359. A pt after his house fire came with hematemesis with erosion/ulcer of esophagus and on examination there is 55% burn and on endoscopy there is a stomach/gastric erosion and soot in the mouth. What is the tx?

- a. PO PPI
- b. IV PPI
- c. PPI and antibiotic
- d. H. pylori test
- e. Tracheal intubation

Ans. The key is E. Tracheal intubation. [If a burnt patient gets soots in mouth and /or nose tracheal intubation is done. GI ulceration (here oesophageal and gastric ulcers and erosions) due to burns are known as curlings ulcers].

1360. A 40yo man complains of severe colicky loin pain that radiates to his scrotum. He is noted to have microscopic hematuria. No masses are palpated. What is the single most likely cause?

- a. Acute cystitis
- b. Bladder ca
- c. Renal vein thrombosis
- d. Acute pyelonephritis
- e. Ureteric calculus

Ans. The key is E. Ureteric calculus. [In ureteric stone there is radiation of pain from loin to groin or scrotum. There also occurs hematuria].

1361. A 55yo man is having slow growing ascites. When we tap the peritoneal fluid the protein is <25 and it is clear and yellow. What could be the origin for ascites?

- a. Budd-Chiari
- b. Gastrinoma
- c. Hepatoma
- d. TB
- e. Pancreatitis

Ans. The key is A. Budd-Chiari syndrome. [In gastrinoma there is no ascites! In hepatoma there will be exudative ascites as in TB and pancreatitis. Budd-Chiari syndrome causes transudative ascites and the likely option here].

1362. A 7yo boy presents with his mother to GP surgery. His mother describes he had presented this since 3wks ago. He had not experienced any trauma. No other symptoms a/w the condition. Exam: non tender swollen ankles bilaterally. There is no rash or lesion. He is otherwise well. Which single test would be the best as an initial assessment?

- a. Plasma electrolytes
- b. Albumin
- c. Total serum protein
- d. Anti-streptolysin

Ans. The key is B. Albumin. [Likely cause of ankle oedema from hypoalbuminemia].

1363. In lyme disease, which complication is most likely to lead to collapse?

- a. Dilated CM
- b. AV block
- c. Mild encephalitis
- d. Meningitis
- e. Myocarditis

Ans. The key is B. AV block.

1364. A 30yo pt came to the OPD with complaint of breathlessness and dry cough. He has lost 5kgs in 2m. He is an IV drug abuser. Inv: CXR=bilateral interstitial shadowing. What is the single most likely causative organism?

- a. Klebsiella
- b. TB
- c. Chlamydia pneumonia
- d. PCP
- e. Chlamydia psittaci

Ans. The key is D. PCP. [IV drug abuser, weight loss, breathlessness and dry cough with interstitial shadowing indicate PCP pneumonia in an AIDS patient].

1365. A 27yo female who had a RTA 7m back now complaints of attacks of sudden onset rotational vertigo which comes on with sharp movements of the head and neck. Which of the following would be most helpful?

- a. Caloric testing
- b. Hallpikes maneuver
- c. Gutenbergers test
- d. Meniere's test
- e. Otoscopy

Ans. The key is B. Hallpikes maneuver. [Vertigo which comes on with sharp movement of the head and neck points towards the diagnosis of benign positional vertigo which can be demonstrated by Hallpikes maneuver].

1366. A man rescued from a building on fire presented with unconsciousness without any evidence of burns or external injury or soot. What would you do next?

- a. 100% oxygen inhalation
- b. 24% oxygen by mask
- c. Hyperbaric oxygen in a hyperbaric chamber
- d. Intubation
- e. Refer to specialist unit

Ans. The key is A. 100% oxygen inhalation. [In CO poisoning 100% oxygen is the initial management and also there is a role of hyperbaric oxygen in a hyperbaric chamber].

1367. A pt has had 1 ep of depression and 2 eps of mania over the last year and now presents with depression. He is on anti-depressants. What additional pharmacological tx would now act as a prophylaxis for his condition?

- a. Antidepressants
- b. Antipsychotics
- c. Mood stabilizers
- d. No additions req

Ans. The key is C. Mood stabilizers. [Antidepressant alone can lead to manic attack and to prevent this a mood stabilizer is required].

1368. A man presented with a purplish swelling at the anal area. It is acutely painful and he complains of constipation for the last 2m. What is the most appropriate management?

- a. I&D
- b. I&D + antibiotics
- c. Reassure
- d. Analgesia
- e. Sclerotherapy

Ans. The key is B. I&D + antibiotics. [Excision is the method which is done in case of hemorrhoid not incision. This is a case of perianal hematoma which when clotted is treated by incision and left open with excellent result of healing but needs antibiotics prophylaxis from fecal contamination. It occurs in case of constipation. Answer is B. Incision and drainage + antibiotics. In acute case prior to thrombosis can be treated with evacuation with syringe].

1368. A man presented with a purplish swelling at the anal area. It is acutely painful and he complains of constipation for the last 2m. What is the most appropriate management?

- a. I&D
- b. I&D + antibiotics
- c. Reassure
- d. Analgesia
- e. Sclerotherapy

Ans. The key is B. I&D + antibiotics. [Excision is the method which is done in case of hemorrhoid not incision. This is a case of perianal hematoma which when clotted is treated by incision and left open with excellent result of healing but needs antibiotics prophylaxis from fecal contamination. It occurs in case of constipation. Answer is B. Incision and drainage + antibiotics. In acute case prior to thrombosis can be treated with evacuation with syringe].

1370. A pt had a stroke. Now, there is left sided weakness and right side facial numbness. CT shows ischemic stroke. Which one would you prescribe?

- a. Alteplase
- b. Aspirin
- c. Clopidogrel
- d. Heparin
- e. Warfarin

Ans. The key is A. Alteplase. [Some say CT detects ischaemic stroke beyond window period which is not correct and it is able to detect stroke much earlier and hence it's place is there in the treatment with alteplase].

1371. A young boy presents with fever and cough. His father was dx with TB a week ago. The parents don't want him to have a BAL under anesthesia. Which other samples can be taken for dx?

- a. Urine
- b. Blood
- c. CSF
- d. Gastric washing
- e. Sweat

Ans. The key is D. Gastric washing. [A young boy is able to cough up sputum unless it is dry cough where suspected TB is diagnosed by broncho-alveolar-lavage (BAL). As in dry cough TB bacteria contaminate saliva and goes to stomach with swallowed contaminated saliva. Gastric-washing can bring out bacteria and detected thereby. So gastric-washing is an alternative to BAL in dry cough].

1372. A 50yo man came to the hosp a few months after he had a MI. Exam: everything normal, S1 and S2 were heard on auscultation, but there is a new pan-systolic murmur. What is the most appropriate inv of choice?

- a. ECG
- b. 24h ECG
- c. Echo
- d. CXR
- e. CT

Ans. The key is C. Echo. [To rule out any valvular lesion (following papillary muscle rupture) or septal lesion].

1373. A 73yo stroke pt has been on aspirin for 2yrs. He now presents with epigastric pain and is asking for a tx. What is the most appropriate management?

- a. Laparotomy
- b. NSAIDs
- c. Omeprazole
- d. Morphine
- e. Tramadol

Ans. The key is C. Omeprazole.

1374. A 2yo girl is brought to the ED by her mother. The child is screaming that there is something in her ear and she appears agitated. Exam: a plastic bead is seen inside the ear. What is the best method of removal?

- a. Forceps
- b. Hook
- c. Under general anesthesia
- d. Syringing
- e. Magnet

Ans. The key is C. Under general anaesthesia.

1375. During antenatal visits, the following tests are routinely offered to all pregnant mothers apart from HIV and Hep B?

- a. Rubella and syphilis
- b. Syphilis and toxoplasmosis
- c. Hep C & thalassemia
- d. CMV and rubella
- e. Sick cell anemia and Hep

Ans. The key is A. Rubella and syphilis.

1376. A 32yo male complains of tremors everytime he tends to use his muscles and when he is pointing at objects. No complaints at rest. His father complained of similar problems. What is the most probable dx?

- a. Parkinsonism
- b. Lithium toxicity
- c. Thyrotoxicosis
- d. Benign essential tremor

Ans. The key is D. benign essential tremor. [In benign essential tremor there is no rest tremor but tremor occurs during movement of the affected limb].

1377. A 40yo woman with breast cancer has back pain which keep her awake at night. She blames it on a gym session she had 2wks ago. She now has difficulty in climbing stairs. There is tenderness over the right thoracic spine. She has diminished fine touch and temp sensation in her right foot. What is the single most appropriate inv?

- a. Bone density scan
- b. CT head
- c. MRI spine
- d. Nuclear bone scan
- e. XR thoracolumbar spine

Ans. The key is C. MRI spine. [There is neurological deficit so to exclude spinal involvement MRI is the single most appropriate investigation].

1378. A pregnant lady at her 39wk GA present with eclampsia. Soon after her arrival in the labour suit, IV MgSO₄ and IV hydralazine has been prescribed. The pt then develops another fit in the hosp and maintenance dose of MgSO₄ has been started. What is your next step in management?

- a. Mg SO₄ bolus
- b. Delivery of baby
- c. MgSO₄ loading dose
- d. Diazepam

Ans. The key is A. MgSO₄ bolus.

1379. A man suffering from Influenza A since 5d ago. CXR: pneumonia. What organism is responsible for pneumonia in this pt?

- a. Hemophilus influenzae
- b. Klebsiella
- c. Staphylococcus aureus
- d. Streptococcus pneumoniae
- e. Pseudomonas

Ans. The key is C. Staphylococcus aureus. [Post flue pneumonia is usually caused by staphylococcus aureus].

1380. A pt admitted due to repeated attacks of pancreatitis presents with dementia and loss of proprioception in the legs. What is the most appropriate tx?

- a. Thiamine
- b. Pyridoxine
- c. Cobolamin
- d. Lipase
- e. Antibiotics

Ans. The key is C. Cobalamin. [Pancreatic insufficiency can lead to malabsorption and B12 (cobalamin) deficiency. Dementia and diminished vibratory sensation and proprioception in the lower extremities were the most common objective findings of cobalamin deficiency].

1381. A man after MI presented with sudden breathlessness and dyspnea. Exam: scattered pansystolic murmur all over the precordium. What is the next inv that will lead to dx?

- a. ECG
- b. Echo
- c. CT
- d. Blood culture
- e. CXR

Ans. The key is B. echo. [Sudden breathlessness and dyspnea suggest mitral regurgitation secondary to papillary muscle rupture but on the otherhand pansystolic murmur all over the precordium suggest VSD! However in either case required investigation is echo].

1382. During a laparoscopic procedure, a trochar is inserted halfway between the umbilicus and the ant superior iliac spine. What are the structures most likely to be pierced?

- a. Rectus sheath
- b. Linea alba
- c. External oblique aponeurosis
- d. Internal oblique and transverse abdominal
- e. Both C and D

Ans. The key is D. Internal oblique and transversus abdominis.

1383. A pt, a small child presented with URTI and later developed fever, earache and tympanic membrane is dull. What is the likely dx?

- a. OM
- b. OE
- c. Glue ear
- d. Perforation of the tympanic membrane
- e. Referred ear ache

Ans. The key is A. OM. [Fever, earache and dull tympanic membrane following urti are pointing the diagnosis of acute otitis media].

1384. A 72yo male who is a regular smoker has come to the ED with complaints of loss of weight and loss of appetite. He also complains of odynophagia. Exam: actively bleeding ulcer on right tonsil. What is the most appropriate dx?

- a. Tonsillar ca
- b. Vincent's angina
- c. Irritant ingestion
- d. Paracoccidioidomycosis
- e. Herpes simplex infection

Ans. The key is A. Tonsillar ca.

1385. A pt with regular episodes of SNHL, vertigo and tinnitus lasting >30min. Neurological exam=normal. What is the likely dx?

- a. Meniere's disease
- b. Acoustic neuroma
- c. Otosclerosis
- d. Benign positional vertigo
- e. Labyrinthitis

Ans. The key is A. Meniere's disease. [SNHL vertigo and tinnitus lasting 30 minutes are consistent with Meniere's disease. Here attacks are episodic that is symptoms resolves but hearing loss is progressive. In acoustic neuroma hearing loss is not episodic. Otosclerosis also not episodic and conductive type. Benign positional vertigo, no hearing loss and vertigo with sharp posture change. Unilateral loss of vestibular function and hearing associated with nausea and vomiting which is preceded by viral infection].

1386. A pt with celiac disease from birth, now as an adult presented with some abdominal symptoms. The biopsy shows infiltration of the gastric epithelium by lymphocytes. What is the most likely dx?

- a. Lymphoma
- b. Diverticular disease
- c. Lynch syndrome
- d. Gastric TB
- e. Peritoneal tumor

Ans. The key is A. Lymphoma. [Coeliac disease leads to an increased risk of both adenocarcinoma and lymphoma of gut].

1387. A 55yo man presented with hot, raised, tender area of skin on his right leg. He is febrile with rigors. He has been started on flucloxacillin. What other meds will you add?

- a. Ciprofloxacin
- b. Gentamicin
- c. Metronidazole
- d. Benzylpenicillin
- e. Ceftriaxone

Ans. The key is D. Benzylpenicillin. [Abscess, cellulitis, furuncle these lesions are usually caused by Staphylococcus and streptococcus. So Benzylpenicillin should be added with flucloxacillin to cover streptococcus].

1388. A 65yo man has incurable bronchial cancer. He is unable to cough up his secretions. This is leading to a distressing cough. Which of the following drugs is most likely to help him?

- a. Scopolamine
- b. Xanomeline
- c. Aceclidine
- d. Pilocarpine
- e. Cevimeline

Ans. The key is A. Scopolamine. [Any secretory condition of lung is reduced and improved with scopolamine].

1389. A pt presented after eating a seafood dish at a local restaurant. He complains of difficulty in breathing. His speech is slurred and his BP=85/55mmHg. What would be the most appropriate next step?

- a. IV adrenaline
- b. IM adrenaline
- c. SC adrenaline
- d. PO chlorpheniramine
- e. IV chlorpheniramine

Ans. The key is B. IM adrenaline. [Patient is getting anaphylactic shock with difficulty of breathing and slurred speech (probably from tongue swelling) which is indications of IM adrenaline].

1390. A 7yo boy presents with proptosis and periorbital edema. What is the immediate action that needs to be taken?

- a. IV morphine and immediate ophthalmoscopy
- b. IV morphine
- c. Observation only

Ans. The key is A. IV morphine and immediate ophthalmoscopy.

1391. A schizophrenic man complains that he can hear voices talking about him and telling him to end his life by cutting his throat. He only hears them when he wakes up from sleep and not at other times. What type of hallucinations is he having?

- a. Somatic
- b. Kinesthetic
- c. Hypnagogic
- d. Hypnopompic
- e. Lilliputian

Ans. The key is D. Hypnopompic hallucination. [Hallucinations during going for sleep is hypnagogic and hallucinations during wake up from sleep is hypnopompic hallucinations].

1392. A 28yo woman complains of hearing strange voices in her bedroom as she is falling asleep in the night. She says there is no one in the room except her. On evaluation she has no other problems. What is she suffering from?

- a. Delusion of persecution
- b. Cotard syndrome
- c. Hypnagogic hallucinations
- d. Lilliputian hallucinations
- e. Schizophrenia

Ans. The key is C. Hypnagogic hallucinations. [Hallucinations during going for sleep is hypnagogic and hallucinations during wake up from sleep is hypnopompic hallucinations].

1393. A 32yo man on psychiatric meds presents with coarse tremors and diarrhea. What is the most likely alt to the drug causing the prb?

- a. Lithium
- b. Diazepam
- c. Haloperidol
- d. Valproate
- e. Citalopram

Ans. The key is D. Valproate. [Diarrhea and coarse tremors are well

known side effects of valproate].

1394. A man is brought to the ED after he was stabbed in the chest. Chest is clear bilaterally with muffled heart sounds. BP=60/0mmHg, pulse=120bpm, JVP is raised. What is the most probable dx?

- a. Pulmonary embolism
- b. Cardiac tamponade
- c. Pericardial effusion
- d. Hemothorax
- e. Pneumothorax

Ans. The key is B. Cardiac tamponade. [Lungs clear bilaterally excludes effusion and pneumothorax. Muffled heart sound and low bp with raised jvp points towards the diagnosis of cardiac tamponade].

1395. A 64yo alcoholic who has been dx with liver cirrhosis presents with a massive ascites. What is the mechanism of fluid accumulation in a pt with liver disease?

- a. Cirrhosis
- b. Portal HTN
- c. Hypoalbuminemia
- d. Liver failure
- e. Hepatic encephalopathy

Ans. The key is C. Hypoalbuminemia. [Mechanism of fluid accumulation (in general, not only ascites) is hypoalbuminaemia].

1396. A 38yo man presented to ED with severe pain in upper abdomen. He has already taken course of triple therapy and now had elective endoscopy 2d ago. He is in shock. What is the most probable dx?

- a. Ca esophagus
- b. Barrett's esophagus
- c. Mediastinitis
- d. Ca stomach

Ans. The key is C. Mediastinitis.

1397. A 68yo man who is a known case of liver cirrhosis has developed ascites. What is the mechanism for the development of ascites?

- a. Portal HTN
- b. Hypoalbuminemia
- c. Congestive heart failure
- d. Liver failure

Ans. The key is A. Portal hypertension. [In liver cirrhosis ascites (not

generalized oedema which is caused by hypoalbuminemia and other mechanisms) is caused by portal hypertension (portal hypertension is invariable in cirrhosis) along with other factors].

1398. A man feels mild discomfort in the anal region and purulent discharge in underpants. What is the most likely dx?

- a. Faecal incontinence
- b. Anal abscess
- c. Fistula in ano
- d. Anal tags
- e. Rectal Ca

Ans. The key is C. Fistula in ano. [Abscess is with severe pain which may reduce after it bursts with purulent discharge. But here mild discomfort and purulent discharge favours the diagnosis of fistula].

1399. A 38yo female presents with difficulty in looking upward and on examination she was found to have lid lag as well. She also complains of her heart racing at times. Which test will help in dx?

- a. Tensilon test
- b. 24h ECG
- c. TFT
- d. Schimmer test
- e. Young Helmholtz ophthalmoscopy

Ans. The key is C. TFT. [Difficulty in looking upwards is due to superior rectus or inferior oblique palsy and palsy of one or more extra-ocular muscle can occur in thyrotoxicosis which is known as Ballett's sign. There is lid lag in thyrotoxicosis and racing heart is due to paroxysmal atrial fibrillation caused by hyperthyroidism].

1400. A young anxious mother of a 10m boy comes to you and requests a test for CF. What is the most appropriate inv?

- a. Sweat test
- b. Heel prick test
- c. Breath test
- d. CXR

Ans. The key is A. Sweat test. [The sweat test measures the concentration of chloride that is excreted in sweat. It is used to screen for cystic fibrosis (CF). Due to defective chloride channels, the concentration of chloride in sweat is elevated in individuals with cystic fibrosis].

1401. A 22yo Greek man presents with rapid anemia and jaundice following tx of malaria. He is noted to have Heinz bodies. Choose the single most likely cause from the given options?

- a. G6PD deficiency
- b. Anemia of chronic disease
- c. Pernicious anemia
- d. IDA
- e. Vit B12 deficiency

Ans. The key is A. G6PD deficiency. [G6PD (glucose-6-phosphate dehydrogenase) deficiency exacerbated by administration of oxidant drugs (e.g., primaquine, dapsone, quinidine) can also result in Heinz bodies].

1402. A 65yo has terminal cancer and his pain is relieved by a fentanyl patch but he now complains of shooting pain in his arm. Which of the following will add to his pain relief?

- a. Gabapentin
- b. Radiotherapy
- c. Amitriptyline
- d. Morphine

Ans. The key is A. Gabapentin. [Shooting in the arm indicates neuropathic pain for which both amitriptyline and gabapentin can be used].

1403. A 45yo male alcoholic presents after a large hematemesis. He has some spider naevi on his chest, BP=100/76mmHg, pulse=110bpm. He has a swollen abdomen with shifting dullness.

- a. Gastric ca
- b. Mallory-weiss tear
- c. Esophageal ca
- d. Esophageal varices
- e. Esophagitis
- f. Peptic ulceration

Ans. The key is D. Esophageal varices. [Spider nevi and ascites suggest advanced liver disease. Here in alcoholic middle aged man having large hematemesis with above mentioned features are very suggestive of bleeding from esophageal varices secondary to portal hypertension in liver cirrhosis].

1404. A 23yo woman presents with a 1cm small smooth, firm, mobile mass in her left breast. She is very anxious. What is the most appropriate inv?

- a. Mammography
- b. US breast
- c. FNAC
- d. Mammography and US

Ans. The key is B. US breast. [This is fibroadenoma of the breast (breast mouse) for which US of breast is the appropriate investigation and if it reveal a fibrous lump we shall go for FNAC. Another point a doctor should know that for any suspicious breast lesion radiology should must be done before options of biopsy and investigation of choice in radiology is US scan before the age of 35 and mammography after the age of 35. In that term also for this case the investigation of choice is US breast].

1405. A pt was admitted with abdominal pain, diarrhea, pigmented palmar creases and buccal mucosa. What is the most probable dx?

- a. Addison's disease
- b. Cushing syndrome
- c. Pheochromocytoma
- d. Hyperthyroidism
- e. Hypoparathyroidism

Ans. The key is A. Addison's disease. [Abdominal pain, diarrhea, pigmented palmar creases and buccal mucosa are well known features of addisons disease].

1406. A 36yo pt came with diarrhea, bleeding, weight loss and fistula. What is the single most likely dx?

- a. Colorectal ca
- b. Celiac disease
- c. CD
- d. UC
- e. IBS

Ans. The key is C. CD. [Bloody diarrhea can occur in both CD & UC. Also weight loss is common! but fistula formation is unique feature of CD].

1407. A 45yo man has undergone detox and now wants a drug to stop him from craving alcohol. What med would be that drug of choice?

- a. Disulfiram
- b. Acamprosate
- c. Thiamine
- d. Naloxone
- e. Diazepam

Ans. The key is B. Acamprosate. [Disulfiram is a deterrent which does not reduce craving. Acamprosate by restoring deranged brain chemical reduces craving].

1408. A 68yo man awoke to find that he is unable to close his left eye and dribbling saliva from the left angle of his mouth. What is the single most appropriate option?

- a. Facial nerve
- b. Glossopharyngeal nerve
- c. Hypoglossal nerve
- d. Optic nerve
- e. Vagus nerve

Ans. The key is A. Facial nerve. [Features are suggestive of left sided facial nerve palsy].

1409. A 19yo female dx with trichomonas vaginalis. LMP was 10d ago. What is the best antibiotic tx?

- a. Erythromycin
- b. Vancomycin
- c. Metronidazole
- d. Penicillin
- e. Clarithromycin
- f. Doxycycline
- g. Fluconazole
- h. Clotrimazole

Ans. The key is C. Metronidazole.

1410. A 35yo man has been given a dx of allergic rhinitis and asthma. Exam: peripheral neuropathy with tingling and numbness in a 'glove and stocking' distribution. Skin elions are present in the form of tender subcutaneous nodules. The pt is responding well to corticosteroids. What is the single most appropriate dx?

- a. AS
- b. Churg-strauss syndrome
- c. Cryptogenic organizing
- d. Extrinsic allergic alveolitis
- e. Tropical pulmonary eosinophilia

Ans. The key is B. Churg-strauss syndrome. [The American College of Rheumatology has identified six criteria for the diagnosis of CSS:[3]

- Asthma (wheezing, expiratory rhonchi).
- Eosinophilia of more than 10% in peripheral blood.
- Paranasal sinusitis.
- Pulmonary infiltrates (may be transient).
- Histological confirmation of vasculitis with extravascular eosinophils.
- Mononeuritis multiplex or polyneuropathy.

The presence of four out of six of these features has a high specificity and sensitivity for the diagnosis of CSS].

1411. A 28yo woman comes with sudden onset vomiting and pain per abdomen. Exam: mobile swelling in the right iliac fossa. What is the most probable dx?

- a. Ectopic pregnancy
- b. Tubo-ovarian abscess
- c. Acute appendicitis
- d. Ovarian torsion
- e. Diverticulitis

Ans. The key is D. [As there is no history of amenorrhea ectopic pregnancy is less likely. So dx is possible ovarian torsion].

1412. A 68yo man on tx for an irregular heart beat comes to the ED. He has palpitations for the last 3h. Exam: pulse=regular, 154bpm. Carotid sinus massage settled his pulse down to 80bpm. What is the most likely rhythm disturbance?

- a. SVT
- b. V-fib
- c. VT
- d. V-ectopics
- e. A-fib

Ans. The key is A. SVT. [Regular tachycardia responding to vagal maneuver is likely SVT].

1413. A 43yo man with a hx of hospital admissions talk about various topics, moving from one loosely connected topic to another. What is the most likely dx?

- a. Psychosis
- b. Mania
- c. Schizophrenia
- d. Pressured speech
- e. Verbal diarrhea

Ans. The key is B. Mania. [Flight of idea is common in mania].

1414. An 18yo girl presents with rash on her trunk, abdominal pain, arthritis, proteinuria and hematuria. What is the most probable dx?

- a. TTP
- b. ITP
- c. HSP
- d. HUS
- e. Measles

Ans. The key is C. HSP. [Henoch-Schönlein purpura (HSP) is an acute immunoglobulin A (IgA)-mediated disorder characterized by a generalized vasculitis involving the small vessels of the skin, the gastrointestinal (GI) tract, the kidneys, the joints, and, rarely, the lungs and the central nervous system (CNS). Rash on trunk, abdominal pain, arthritis, proteinuria and hematuria are well known features of HSP].

1415. A pt is on loop diuretics. What effect do loop diuretics produce?

- a. Low Na⁺, low K⁺
- b. Low Na⁺, normal K⁺
- c. Normal Na⁺, normal K⁺
- d. High Na⁺, low K⁺
- e. High Na⁺, high K⁺

Ans. The key is A. Low Na⁺, Low K⁺. [Loop diuretics causes hyponatremia and hypokalemia].

1416. A 6yo girl is being investigated for renal failure. She is found to have a congenital abnormality of the insertion of the ureters into the urinary bladder. What is the single most likely cause for renal failure in this pt?

- a. SLE
- b. PKD
- c. Wilm's tumor
- d. Acute tubular necrosis
- e. Reflux nephropathy

Ans. The key is E. Reflux nephropathy. [Reflux nephropathy is kidney damage (nephropathy) due to urine flowing backward (reflux) from the bladder toward the kidneys; the latter is called vesicoureteral reflux (VUR)].

1417. A 76yo man is in the CCU 2d after an acute MI. He tells you that he had an episode of rapid pounding in the chest lasting for about 2mins. He remains conscious throughout. What is the most likely rhythm?

- a. SVT
- b. VF
- c. VT
- d. V-ectopics
- e. A-fib

Ans. The key is C. VT. This is wrong key. Correct key is D. V-ectopics. [Why not VT? Non sustained VT lasts less than 30 seconds. So it is not non sustained VT. Again sustained VT causes syncope, but patient was conscious. So it is not sustained VT as well. There may be runs of V-ectopics. So the answer is D. V-ectopics].

1418. A 49yo man comes with hx of cough and SOB. His CD4 count is measured as 350. CXR shows lobar consolidation. What is the single most appropriate option?

- a. Mycobacterium avium intercellular
- b. CMV
- c. Streptococcus
- d. Toxoplasmosis
- e. Pneumocystis jirovecii

Ans. The key is C. Streptococcus. [Features are consistent with lobar pneumonia].

1419. A 32yo woman with prv hx of PID now presents with severe abdominal pain. Her LMP was 8wks ago. What is the most probable dx?

- a. Ectopic pregnancy
- b. Ovarian torsion
- c. Hematometrium
- d. Chronic PID
- e. Cholecystitis

Ans. The key is A. Ectopic pregnancy. [PID is a risk factor for ectopic pregnancy].

1420. A 25yo who is 38wks pregnant presents to the labour ward with a hx of fewer fetal movements than usual during the evening. She also says that abdominal contractions are coming every few minutes and she is having a blood stained show per vagina for the last few minutes. Exam: cervix is fully effaced, 9cm dilated, cephalic presentation and station is +1. Choose the single most likely dx?

- a. APH
- b. Concealed hemorrhage
- c. Labour
- d. IUFD
- e. IUGR

Ans. The key is C. Labour. [Abdominal contractions coming every few minutes, having blood stained show per vagina, fully effaced cervix with dilatation of 9 cm, cephalic presentation and station +1 suggests that the patient is in labour].

1421. A 30yo woman has a painless lump in the outer aspect of her left breast. She has had a prv breast lump. Her grandmother had breast cancer at 70yrs. She has a 1cm smooth, firm, discrete, mobile lump in the other quadrant region of the left breast. What is the single most likely dx?

- a. Breast abscess
- b. Breast carcinoma
- c. Breast cyst
- d. Fibro-adenoma
- e. Sebaceous cyst

Ans. D. Fibroadenoma. [H/O previous breast lump and presently with a lump of 1 cm size which is smooth, firm (not hard), discrete and mobile (not fixed) suggests fibro-adenoma].

1422. A 38yo woman is in the ED following an OD of her meds. She doesn't need med tx for the OD. She says she wishes to be discharged. What is the single most appropriate management?

- a. Community psychiatric nurse visit
- b. Psychiatric OPD review the next day
- c. Prescribe anti-depressants
- d. Admission under the mental health act
- e. Discharge and allow to go home

Ans. The key is D. Admission under the mental health act. [There is every chance of repeat over dose. So she should be admitted under mental health act].

1423. A 63yo male presents after having had a seizure. Exam: alert and oriented. Exam: inattention on the left side and hyperreflexia of the arm. What is the most probable dx?

- a. Cerebral tumor
- b. Pituitary adenoma
- c. Cerebellar abscess
- d. Huntington's chorea
- e. Parkinsonism

Ans. The key is A. Cerebral tumour.

1424. A 70yo lady on Raloxifene for osteoporosis has recently to the UK from Australia. She now presents with severe chest pain, SOB and suddenly collapsed in the ED. What is the single most appropriate dx?

- a. MI
- b. Aortic dissection
- c. Pulmonary embolism
- d. Costochondritis
- e. Pneumothorax

Ans. The key is C. Pulmonary embolism. [Prolonged air travel is a risk factor for pulmonary embolism].

1425. A 35yo woman complains of hoarseness of voice 3h after partial thyroidectomy. She had no hx of phonation probs before the surgery. What is the single most appropriate inv?

- a. Laryngoscopy
- b. Bronchoscopy
- c. CT neck
- d. CXR
- e. Barium swallow

Ans. The key is A. Laryngoscopy. [Probable diagnosis is recurrent laryngeal nerve palsy].

1426. A 40yo pt came to OPD with complaint of fever, pleuritic chest pain, productive cough and painful vesicles around the lips. Exam: temp=38C. He has a hx of splenectomy last yr. What is the single most likely causative organism?

- a. Pneumococcal pneumonia
- b. Staphylococcus
- c. Klebsiella
- d. Streptococcus
- e. Chlamydia psittaci

Ans. The key is A. Pneumococcal pneumonia. [painful vesicles around the lips is well known association of pneumococcal pneumonia. Also pleuritic chest pain and productive cough are present in pneumococcal pneumonia].

1427. A 37yo male pt who recently returned back to UK from UAE attends the OPD with complaint of dry cough, breathlessness and anorexia. According to him he had flu like symptoms a week ago. He is slightly confused. Inv: lymphopenia & decreased Na+. CXR: bi-basal consolidation. What is the single most likely causative organism?

- a. Legionella
- b. Chlamydia pneumonia
- c. PCP
- d. Viral pneumonia
- e. Chlamydia psittaci

Ans. The key is A. Legionella. [H/O travel (staying in AC and watersystem of hotel), lymphopenia, decreased Na+, bi-basal consolidation are well known features of legionnaires disease].

1428. A 20yo student came to the OPD with complains of headache, malaise, dry cough, joint pain and vomiting. Exam: temp=39C. CXR: patchy consolidation. What is the single most likely causative organism?

- a. Pneumococcal pneumonia
- b. Mycoplasma
- c. Klebsiella
- d. Streptococcus
- e. PCP

Ans. The key is B. Mycoplasma.

1429. A 45yo man presented to his GP with vague symptoms of headache, proximal muscle weakness and nocturia. Test results show him to be severely HTN (230/130mmHg) and hypokalemic. What is the most probable dx?

- a. Addison's disease
- b. Conn's disease
- c. Familial hyperaldosteronism
- d. Cushing's disease
- e. Cushing's syndrome

Ans. The key is B. Conn's disease. [High BP is often the only presentation of Conn's syndrome. Loss of K+ in urine leads to hypokalemia which in turn causes muscle weakness and polyuria particularly nocturia].

1430. A man says his insides are rotting and nobody has buried him. Which term best describes his condition?

- a. Delusion of nihilism
- b. Delusion of guilt
- c. Delusion of persecution
- d. Incongruent affect
- e. Clang association

Ans. The key is A. Delusion of nihilism.

1431. A man with chronic cough presents with copious purulent sputum. What is the single most dx?

- a. Bronchitis
- b. Bronchiectasis
- c. COPD
- d. Pneumonia
- e. Emphysema

Ans. The key is B. Bronchiectasis.

1432. A 32yo man working in a shipyard comes with SOB. Exam: dullness on left side of the chest, pain in left side of chest, pleuritic rub and crackles been heard on the same side. What is the single most likely dx?

- a. Pericarditis
- b. Pleurisy
- c. Pleural effusion
- d. CCF
- e. TB

Ans. The key is C. Pleural effusion. [Shipyard worker are exposed to asbestos and presenting case has developed mesothelioma causing pleura thickening and pleural effusion. Though it is usual that in pleural effusion pleural rub reduces or becomes absent but it is also possible to get pleural rub even in pleural effusion and the like diagnosis is pleural effusion here].

1433. A 67yo female presents with balance prbs. Exam: nystagmus on left lateral gaze, a loss of the left corneal reflex and reduced hearing in the left ear. What is the most likely dx?

- a. Meniere's disease
- b. Acoustic neuroma
- c. Cerebral abscess
- d. Pituitary tumor
- e. Gentamicin

Ans. The key is B. Acoustic neuroma. [nystagmus, loss of corneal reflex, hearing loss, balance problem are well known feature of acoustic neuroma].

1434. A 22yo man reports a 2d hx of hoarseness of voice. He denies any weight loss but he has been smoking for 4yrs. What is the single most appropriate inv?

- a. None
- b. Laryngoscopy
- c. Bronchoscopy
- d. BAL
- e. CXR

Ans. The key is B. Laryngoscopy. It is a wrong key! Correct key is A. None. [If hoarseness is of >3 weeks in man >50 yrs and smoker and heavy drinker to rule out cancer do CXR and/or laryngoscopy- NICE guideline].

1435. A 34yo IVDA (intravenous drug addict) presents with a 4m hx of productive cough. He has lost 10kgs. What is the single most appropriate inv?

- a. Sputum for AFB
- b. Laryngoscopy
- c. Bronchoscopy
- d. CT neck
- e. CXR

Ans. The key is A. Sputum for AFB. [In IVDA immunity becomes low and easily gets infected with TB].

1436. A 25yo pt came to the OPD with complaint of fever, malaise, breathlessness, cough and anorexia. His gf has got similar symptoms. He had hx of sore throat and ear discharge a month ago. What is the single most likely causative organism?

- a. Legionella
- b. Mycoplasma
- c. Chlamydia pneumonia
- d. PCP
- e. Chlamydia psittaci

Ans. The key is C. Chlamydia pneumonia.

1437. A 72yo male presents with acute confusion. He has been in the hosp for 2wks having been treated for a DVT. The nurses have noticed that he became increasingly drowsy. Exam: small scalp laceration, a GCS of 8 and bilateral up-going plantar response.

- a. Infection toxicity
- b. Delirium tremens
- c. Extradural hematoma
- d. Subdural hematoma
- e. Electrolyte imbalance

Ans. The key is D. Subdural hematoma. [Even trivial head trauma can lead to subdural hematoma. Presence of small scalp laceration, confusion and becoming increasingly drowsy Glasgow coma scale of 8 are suggestive of subdural hematoma].

1438. A 50yo DM pt came to the OPD with complaint of fever, muscle ache, dry cough and anorexia. Inv: CXR=upper lobe cavitation. What is the single most likely causative organism?

- a. Legionella
- b. Mycoplasma
- c. Staphylococcus
- d. Klebsiella
- e. Streptococcus

Ans. The key is D. Klebsiella. [Upper lobe cavitation favours Klebsiella pneumonia. Also it is well known that staphylococcal and klebsiella pneumonia are more common in DM than normal person].

1439. A 20yo man complains that all his movements are being watched. Sometimes he feels as though his actions are being controlled by his radio. At other times he is aware of voices describing what he is doing. What is the most probable dx?

- a. Mania
- b. Drug induced psychosis
- c. Delusion of control
- d. Schizophrenia
- e. Korsakoff psychosis

Ans. The key is D. Schizophrenia.

1440. A 35yo is agitated and euphoric. He claims to be helping the prime minister with economic policy, although this is not true when checked. What is the most likely dx?

- a. Mania
- b. Schizophrenia
- c. Hypomania
- d. Drug induced personality disorder
- e. Delusion of grandeur

Ans. The key is E. Delusion of grandeur. Key is wrong! Correct key should be mania. [Agitated, euphoric and delusion of grandiosity makes the likely dx to be "Mania". Agitation and euphoria are not feature of delusion of grandiosity but mania].

1441. A 20yo student who recently visited Asia came to the OPD with complains of low grade fever, night sweats, anorexia and productive cough. Inv: CXR=cavitary lesions in upper lobes. What is the single most likely causative organism?

- a. Mycoplasma
- b. Klebsiella
- c. TB
- d. PCP

Ans. The key is C. TB. [Low grade fever, night sweats, anorexia, dry (initially) or productive cough, and upper lobe cavitary lesions are highly suggestive of TB].

1442. A 35yo man with T1DM is dehydrated with BP=90/50mmHg. What is the single most appropriate initial inv?

- a. ABG
- b. CBC
- c. HbA1c
- d. LFT
- e. BUE

Ans. The key is A. ABG. [The likely dx is DKA. Among the given options ABG is the most appropriate inv. To demonstrate acidosis].

1443. A 45yo woman presents with pruritus. Exam: skin pigmentation. Inv: raised ALP and presence of anti-mitochondrial antibodies. What is the single most likely dx?

- a. Psoriasis
- b. Scabies
- c. Atopic eczema
- d. Dermatitis herpetiformis
- e. Hyperthyroidism
- f. Primary biliary cirrhosis

Ans. The key is F. Primary biliary cirrhosis. [Pruritus, skin pigmentation (increased amounts of melanin, widely dispersed throughout both epidermis and dermis), raised ALP, and presence of AMA are diagnostic of primary biliary cirrhosis].

1444. A 60yo man complains of tiredness, lethargy and itching that is severe after a hot bath. He also has nocturia, polyuria and nausea and vomiting. Exam: pallor, pigmentation and generalized edema. What is the single most likely dx?

- a. Hyperthyroidism
- b. Lichen planus
- c. Lymphoma
- d. Eczema
- e. Liver failure
- f. CRF

Ans. The key is F. CRF. [Given picture is typical of CRF].

1445. A 30yo man complains of vague pain in the loin with BP=140/90mmHg. He is found to have proteinuria and hematuria. What is the inv to confirm the dx?

- a. Abdominal US
- b. ANCA
- c. ANA
- d. Urine microscopy and culture
- e. Stool culture

Ans. The key is A. Abdominal US. [The likely dx is ADPKD for which US is diagnostic investigation].

1446. A 54yo man comes with sudden onset of palpitations and breathlessness. His HR=164bpm. What is the single most appropriate tx in the acute phase?

- a. Adenosine
- b. Metoprolol
- c. Verapamil
- d. Amiodarone

Ans. The key is A. Adenosine. This is wrong key! Correct key is B. Metoprolol. [The only arrhythmia where we use acute and chronic phase is AF. So though the given key is Adenosine it is a wrong key!! It is acute phase of atrial fibrillation for which we use beta-blocker. So the answer should be B. Metoprolol here].

1447. A 29yo woman has developed an itchy scaly rash particularly over her wrist with fine white streaks overlying the lesion. Her nails have ridges and her buccal mucosa is lined with a lacy white pattern. What is the single most likely dx?

- a. Psoriasis
- b. Scabies
- c. Urtericaria
- d. Dermatitis herpetiformis
- e. Hyperthyroidism
- f. Lichen planus

Ans. The key is F. Lichen planus. ["Lacy white pattern" is used as a diagnostic description of lichenplanus].

1448. The artery that runs in the ant inter-ventricular groove. What is the single most appropriate option?

- a. Acute marginal branch
- b. Left ant descending artery
- c. Coronary sinus
- d. Circumflex artery
- e. Right coronary artery

Ans. The key is B. Left ant descending artery.

1449. Which virus is transmitted by the fecal-oral route?

- a. Hep C
- b. Coxsackie virus
- c. Dengue
- d. None of the above

Ans. The key is B. Coxsackie virus.

1450. A 40yo woman presented with generalized itching and tiredness for few months. She gave a hx of heavy menstrual periods. Exam: pallor. What is the single most likely causative factor?

- a. IDA
- b. Lichen planus
- c. Dermatitis herpetiformis
- d. Eczema
- e. Uremia

Ans. The key is A. IDA. [IDA is one of the cause of pruritus. Heavy periods, pallor and tiredness further supports the diagnosis].

1451. A 7yo child presents with lesions on the trunk. Exam: some lesions are weeping and others are crusted with a red base. What is the causative organism?

- a. Herpes simplex
- b. Varicella zoster
- c. Rubella virus
- d. Herpes zoster

Ans. The key is B. Varicella zoster.

1452. An 87yo woman with a hx of HTN has acute breathlessness. She has a RR=32bpm, widespread lung crackles, pulse=120bpm, BP=160/90mmHg and elevated venous pressure. Her peripheral O2 sat=85%. What is the single most appropriate initial management?

- a. IV antibiotics
- b. IV furosemide
- c. Nitrate infusion
- d. Neb. Salbutamol
- e. 100% oxygen

Ans. The key is E. 100% oxygen. [Most appropriate initial management is E. 100% oxygen. Oxygen saturation is low. So we have to give oxygen initially].

1453. A 25yo man presented with painless cervical lymphadenopathy with lethargy, night sweats and itching. What is the single most likely causative factor?

- a. Lymphoma
- b. Polycythemia
- c. IDA
- d. Uremia
- e. Drug induced

Ans. The key is A. Lymphoma. [Cervical lymphadenopathy, lethargy, night sweats and itching are well known features of lymphoma].

1454. A 25yo male presents with fever and pain in the right lower thigh of 1m duration. Exam: lower third of his thigh is red, hot and tender. The XR showed new bone formation. What is the most probable dx?

- a. Osteosarcoma
- b. Ewing's sarcoma
- c. Tuberculosis arthritis
- d. Exostosis
- e. Fibrosarcoma

Ans. The key is B. Ewing's sarcoma.

1455. A 76yo man presents with sore throat, local irritation by hot food, dysphagia and a sensation of a lump in his throat. He has a 20y hx of smoking. What is the single most likely dx?

- a. Nasopharyngeal ca
- b. Pharyngeal ca
- c. Sinus squamous cell ca
- d. Squamous cell laryngeal ca
- e. Hypopharyngeal ca

Ans. The key is B. Pharyngeal Ca.

1456. A 42yo female who is obese comes with severe upper abdominal pain and right shoulder tip pain with a temp=37.8C. She has 5 children. What is the most probable dx?

- a. ERCP
- b. LFT
- c. Serum amylase
- d. MRCP
- e. US abdomen

Ans. The key is US abdomen. [5 "f". Fat, female, fair, forty, fertile = cholecystitis].

1457. A 37yo laborer comes with hx of redness of left eye with foreign body sensation in the same eye. What is the single most appropriate option?

- a. Ciliary body
- b. Sclera
- c. Conjunctivitis
- d. Cornea
- e. Iris

Ans. The key is D. Cornea. [Redness with foreign body sensation of

eye in a labourer are most likely due to foreign body in cornea].

1458. An 11yo boy came to the hospital with pain after falling off his bicycle. XR= fx at distal radius with forward angulations. What is the single most probable dx?

- a. Dinner fork deformity
- b. Cubitus valgus
- c. Gun stock deformity
- d. Garden spade deformity
- e. Genu valgus

Ans. The key is D. Garden spade deformity.

1459. A middle aged man with a lump in front of his neck which moves up while he's swallowing. US shows a mass replacing the left lobe of thyroid. And spread to the sternocleidomastoid and adjacent muscles. What is the most probable dx?

- a. Thyroid ca
- b. Pharyngeal pouch
- c. Bronchus ca
- d. Thyroid cyst
- e. Larynx ca

Ans. The key is A. Thyroid Ca.

1460. A 28yo male complains of severe pain while trying to grasp any object. It started since he participated in skiing and had a fall and caught his thumb in the matting. Exam: rupture of the ulnar collateral ligament of MCP joint of the thumb. What is the single most probable deformity?

- a. Dinner fork deformity
- b. Game keeper thumb
- c. Mallet finger
- d. Gun stock deformity
- e. Garden spade deformity

Ans. The key is B. Game keeper thumb. [Gamekeeper's thumb is an insufficiency of the ulnar collateral ligament (UCL) of the metacarpophalangeal (MCP) joint of the thumb].

1461. A 25yo male had an injury to the knee while playing football. XR=condylar fx of tibia. What is the single most probable deformity?

- a. Dinner fork deformity
- b. Gibbus
- c. Cubitus valgus
- d. Garden spade deformity
- e. Genu valgus

Ans. The key is E. Genu valgus.

1462. A 50yo man presents with itching after hot shower with dizziness, chest pain after exercise. Exam: splenomegaly. What is the single most likely causative factor?

- a. ALL
- b. Lymphoma
- c. Polycythemia
- d. Scabies
- e. Eczema

Ans. The key is C. Polycythemia. [Itching after hot shower; dizziness and angina due to hyperviscosity and splenomegaly are well known features of polycythemia].

1463. A man presented with carcinoma of the bladder and has been working in factories. He wants to know what dye has caused it. What is the single most likely cause?

- a. Aniline
- b. Asbestos
- c. Latex
- d. Silica

Ans. The key is A. Aniline. [Aniline dye is a well known cause of bladder cancer].

1464. A 62yo man presents with left sided hearing loss and tinnitus. He also complains of vomiting and headache. Exam: papilledema and SNHL in the left ear. What is the single most likely dx?

- a. Meningioma
- b. Nasopharyngeal ca
- c. Acoustic neuroma
- d. Pharyngeal ca
- e. Meniere's disease

Ans. The key is C. Acoustic neuroma. [SNHL, tinnitus, papilledema (raised intracranial pressure) are suggestive of acoustic neuroma].

1465. A HIV +ve 55yo man presents with painless lymphadenopathy, fever, night sweats and weight loss. What is the most probable dx?

- a. Hodgkin's lymphoma
- b. NHL
- c. ALL
- d. AML
- e. CML

Ans. The key is B. NHL. [NHL is more likely diagnosis in AIDS or immunodeficient state].

1466. A 22yo man says that he can hear the voice of his deceased uncle telling him that he is being spied on. The pt is distressed by this becoming low in mood and anxious and has not left the house for 2wks. He is starting to drink increasing quantities of alcohol. He is noticed to have thought-block and passivity phenomena. What is the single most suitable med to treat his symptom?

- a. Diazepam
- b. Disulfiram
- c. Fluoxetine
- d. Lithium
- e. Olanzapine

Ans. The key is E. Olanzapine. [Auditory hallucination, social withdrawal, thought block are features of schizophrenia. So olanzapine is the drug to be prescribed from the given option].

1467. A middle aged Asian presents with episodes of fever with rigors and chills for last 1yr. Blood film: ring form of plasmodium with schuffners dots in RBCs. What is the drug to eradicate this infection?

- a. Doxycycline
- b. Mefloquine
- c. Proguanil
- d. Quinine
- e. Artesunate

Ans. The key is B. Mefloquine which is a wrong key! None of the given options is correct!! [Schuffners dot indicate either vivax or ovale infection and the hepatic cycle only can be eradicated by primaquine. Probably It is a bad recall].

1468. A 50yo man presents with flight of ideas which are rambling and disinhibited. He is distractable, confused and overactive. What is the most likely dx?

- a. Dementia
- b. Mania
- c. Schizophrenia
- d. Psychosis
- e. Acute confusional state

Ans. The key is B. Mania. [Flight of ideas, dysinhibition, distractibility, confusion and overactivity are features of mania].

1469. A pt presents with a lid lag, bulging eyes, ophthalmoplegia and thyroid bruit. What inv will you do?

- a. TFT
- b. Eye sight
- c. Tensilon test
- d. US
- e. FNAC

Ans. The key is TFT. [TFT should be done. Why not FNAC? Thyrotoxicosis is benign and not malignant].

1470. A 30yo lady complaining of right ear deafness with decreased corneal reflex and past pointing. Acoustic analysis shows SNHL. What is the next most appropriate inv to do?

- a. CT brain
- b. CT acoustic canal
- c. MRI brain
- d. MRI acoustic canal
- e. PET brain

Ans. The key is MRI brain. This is wrong key! Correct key is D. MRI acoustic canal.

1471. A 29yo woman who returned from Egypt 2wks ago now presents with difficulty in breathing, chest pain, cough and purulent sputum with an episode of blood staining. She is on COCPs. What is the most likely dx?

- a. Pulmonary embolism
- b. Pneumonia
- c. Lung abscess
- d. Pneumothorax
- e. Pulmonary edema

Ans. The key is B. Pneumonia. [Purulent sputum is the clincher to differentiate pneumonia from pulmonary embolism here].

1472. A 60yo pt recovering from a surgery for toxic goiter is found to be hypotensive, cyanosed in the recovery room. Exam: neck is tense. There is oozing of blood from the drain. What is the most probable dx?

- a. Thyroid storm
- b. Reactionary hemorrhage
- c. Secondary hemorrhage
- d. Primary hemorrhage
- e. Tracheomalacia

Ans. No key is given. Correct key is B. Reactionary hemorrhage. [Hemorrhage within 1st 24 hours which usually occurs due to dislodgement of clot or slippage of a ligature].

1473. A 40yo woman has had varicose vein surgery, planned as a day pt. After the op, she is distressed by repeated retching and vomiting. Her pain is currently well controlled. What is the best management strategy?

- a. Tramadol
- b. Co-codamol
- c. IM morphine
- d. IV ondansetron
- e. PO ondansetron

Ans. The key is D. IV ondansetron. [As there is repeated retching and vomiting pt. cannot keep oral medication down. So IV ondansetron].

1474. A pt with renal failure has serum K⁺=7.5, raised creatinine and broad complex tachycardia. What is the most appropriate management?

- a. Calcium gluconate
- b. Sodium bicarbonate
- c. Dialysis
- d. Furosemide
- e. Sotalol

Ans. The key is A. Calcium gluconate. [Calcium gluconate don't shift K⁺ to cell or reduce potassium level but it prevents arrhythmogenic action of raised K⁺ till definitive measure is taken].

1475. An 18yo lady in her 30th wk of pregnancy is brought to the hospital in an altered sensorium. She is taking slow, shallow breaths and her breath has a fruity smell. An ABC: pH=7.20, urine ketones: +ve. What is the most probable dx?

- a. HONK
- b. DKA
- c. HELLP syndrome
- d. PIH
- e. GDM

Ans. The key is B. DKA. [Shallow breath and fruity smell with acidosis in ABC and positive ketone body in urine suggests the diagnosis of DKA].

1476. A 26yo man presented with abdomen distension and pain. His stools have been mucoid and sometimes blood stained. What is the most appropriate inv?

- a. Stool C&S
- b. Gastroscopy
- c. IgG tissue transglutaminase
- d. Barium meal
- e. Jejunal biopsy

Ans. The key is D. Barium meal. This is wrong key. Correct key is A. Stool C&S. [Probable diagnosis is Ulcerative colitis and abdominal distension may indicate toxic megacolon where barium enema should be avoided. Stool assessment is one of the lab procedures done in ulcerative colitis which may be the option from given ones. Stool culture is not confirmatory but suggestive].

1477. An 83yo elderly woman presented in the ED with cough, fever and sneezing. Tx was given but she became confused and again presented with above said symptoms. What is the cause of her condition?

- a. Aspiration due to confusion
- b. Alveolar damage due to drugs
- c. Drug toxicity
- d. Pneumothorax

Ans. The key is A. Aspiration due to confusion.

1478. A 37yo man presents with some raised lesions on the shin. He came with cough and also complains of arthralgia. Exam: bilateral hilar lymphadenopathy and erythema nodosum is present. What is the single most likely cause?

- a. CD
- b. UC
- c. Sarcoidosis
- d. Streptococcal infection
- e. TB

Ans. The key is B. UC. It is a wrong key! Correct key is C. Sarcoidosis. [Cough, arthralgia, bilateral hilar lymphadenopathy and erythema nodosum are suggestive of sarcoidosis].

1479. A young lady with cervical ectropion bleeds on touch. What is the most appropriate next inv?

- a. Transvaginal US
- b. Cervical smear
- c. Punch biopsy
- d. Serum estradiol
- e. Colposcopy

Ans. B. Cervical smear. Wrong key! Correct key is E. colposcopy. [Screening test cervical smear is only done in scheduled time and not in on demand basis. So if it is scheduled now then it can be the option otherwise Colposcopy should be the key!! This is definitely an incomplete question].

1480. A 28yo man with recent onset of dyspepsia after eating spicy food and alcohol consumption. H. pylori fecal antigen was negative. He returns after 1m with similar symptoms despite being given omeprazole 40mg. What is the single best initial inv?

- a. Hydrogen breath test
- b. Gastroscopy
- c. Barium meal
- d. None

Ans. The key is B. Gastroscopy.

1481. A 35yo woman who usually has 4 days mid-cycle bleeding, had her period 10d ago. She has now presented with spots of blood. Her smear was normal 6m ago. Exam: cervical ectropion which doesn't bleed on touch. What would you do?

- a. Cervical smear
- b. Endocervical swab
- c. US guided biopsy
- d. Laparotomy
- e. Transvaginal US
- f. Punch biopsy
- g. Serum estradiol
- h. Colposcopy

Ans. The key is A. Cervical smear. Wrong key! Correct key is endocervical swab. [Cervical smear can only be done on scheduled time and not in on need basis. In given case for intermenstrual bleeding endocervical swab should be done].

1482. A 7yo boy presents with epistaxis of 2h duration. The bleeding has been controlled. Inv: Plts=210, PT=13, APTT=42, bleeding time=normal. Which of the following is the most likely dx?

- a. Hemophilia
- b. Von willebrand disease
- c. ITP
- d. Vit K deficiency
- e. Liver disease
- f. Anatomical defect

Ans. The key is F. Anatomical defect.

1483. A pregnant woman returns from Sudan, now presenting with intermittent fever, rigor and seizures. What is the dx?

- a. TB
- b. Malaria
- c. Meningitis
- d. Lyme disease

Ans. The key is B. Malaria. [Intermittent fever is seen in malaria. In meningitis fever is not intermittent].

1484. A pt is unresponsive and cyanosed. What is the most definitive 1st step in management?

- a. Chest compressions
- b. Check airway
- c. Call 999
- d. Mouth to mouth
- e. Recovery position

Ans. The key is B. Check airway.

1485. A man was bitten by a drug addict and comes to the hosp with a wound. What inv should be undertaken?

- a. Hep C
- b. Lyme disease
- c. Hep B
- d. Syphilis
- e. Hep A

Ans. The key is C. Hepatitis B.

1486. An 18yo woman says that she can't walk around as she is very big for that room. What is the most likely hallucination?

- a. Extracampine visual hallucinations
- b. Lilliputian visual hallucinations
- c. Alice in wonderland syndrome
- d. Hypnagogic hallucinations

Ans. The key is B. Lilliputian visual hallucination. [B. Lilliputian visual hallucinations and C. Alice in wonderland syndrome are same].

1487. A middle aged lady presented with fever, altered sensorium, bleeding gums and jaundice. Labs: deranged renal function tests, normal PT/APTT, fragmented RBCs and low plts. What's the most likely dx?

- a. Cholesterol emboli
- b. HUS
- c. TTP
- d. Hepatorenal syndrome
- e. Sepsis

Ans. The key is C. TTP. [Fever and altered sensorium suggest the diagnosis of TTP].

1488. A child came to the ED with severe asthma and not responding to salbutamol nebulizer and vomiting many times. What is the most appropriate management?

- a. Salmeterol
- b. Montelukast
- c. Prednisolone
- d. Budesonide inhaler
- e. Oxygen
- f. IV salbutamol

Ans. The key is A. Salmeterol which is a wrong key!! The correct option is F. IV salbutamol. [In acute attack there is no place for salmeterol. In the given case most appropriate management is IV salbutamol].

1489. A 73yo woman with skeletal and brain mets from breast ca has worsening low back pain and blurring of vision. She has weakness of her legs, minimal knee and absent ankle tendon reflexes, a palpable bladder, a power of 2/5 at the hip, 3/5 at the knee and ankle, and tenderness over the 2nd lumbar vertebra. There is reduced sensation in the perineum. She has been started on dexamethasone 16mg daily. What is the single most likely cause of her weakness?

- a. Paraneoplastic neuropathy
- b. Progression of brain tumor
- c. PID at L2/L3
- d. Spinal cord compression
- e. Steroid induced myopathy

Ans. No key is given! The likely correct option is D. Spinal cord compression. [Brain metastasis induced cerebral oedema can explain blurring of vision secondary to raised intracranial pressure. Rest of the features including weakness can well explain spinal cord compression].

1490. A 78yo woman presents with unilateral headache and pain on chewing. ESR=70mm/hr. She is on oral steroids. What is the appropriate additional therapy?

- a. Bisphosphonates
- b. HRT
- c. ACEi
- d. IFN
- e. IV steroids

Ans. The key is A. Bisphosphonates. [Oral steroid can lead to decrease in bone mineral density. To overcome this Bisphosphonate can be administered].

1491. A 48yo woman is admitted to the ED with a productive cough and mod fever. She often has central chest pain and she regurgitates undigested food most of the time but doesn't suffer from acid reflux. These symptoms have been present for the last 3.5m which affects her daily food intake. CXR: air-fluid level behind a normal sized heart. What is the single most likely dx?

- a. Pharyngeal pouch
- b. Hiatus hernia
- c. Bulbar palsy
- d. Achalasia
- e. TB

Ans. 1. The key is B. Hiatus hernia. [Usually in hiatus hernia there is acid reflux but in given case there is no acid reflux which can be true if hiatus hernia is small].

1492. A retired ship worker has pleural effusion and pleural thickening on right side with bilateral lung shadowing. What would you do to improve his symptoms?

- a. Aspiration
- b. Chest drain
- c. Chemotherapy
- d. Diuretic

Ans. The key is C. Chemotherapy. It is a wrong key! Correct key is B. Chest drain. [Response to chemotherapy and life expectancy is poor in mesothelioma. To improve symptoms chest drain should be undertaken].

1493. An 88yo woman is a known smoker. She had an attack of MI 2y back and is known to have peripheral vascular disease. She presents with an irreducible herniation over the incision region of a surgery which she underwent in her childhood. What is the most appropriate tx?

- a. Truss
- b. Elective herniorrhaphy
- c. Urgent herniorrhaphy
- d. Elective herniotomy
- e. Reassure

Ans. The key is B. Elective hernioraphy. [Truss can not be used as hernia is irreducible; urgent herniorrhaphy in strangulation; elective herniotomy- in herniotomy the hernia may recur; only reassure is not an option as irreducible hernia may become strangulated or may develop intestinal obstruction].

1494. A 72yo woman who is taking loop diuretics for left ventricular failure. She now is suffering from palpitations and muscle weakness. What is the electrolyte imbalance found?

- a. Na+=130mmol/L, K+=2.5mmol/L
- b. Na+=130mmol/L, K+=5.5mmol/L
- c. Na+=140mmol/L, K+=4.5mmol/L
- d. Na+=150mmol/L, K+=3.5mmol/L
- e. None

Ans. The key is A. Na+=130mmol/L, K+=2.5mmol/L. [Loop diuretics causes hyponatremia and hypokalemia].

1495. A young woman who is a marathon runner comes with secondary amenorrhea. Inv: normal LH, FSH and estradiol, prolactin=600. What is the most likely dx?

- a. Hypothalamic amenorrhea
- b. Pregnancy
- c. PCOS
- d. Prolactinoma
- e. Anorexia

Ans. The key is D. Prolactinoma. It is a wrong key. Correct key is A. Hypothalamic amenorrhea. [Generally in hypothalamic amenorrhea there is slight low level of LH, FSH and Oestrogen and mild elevation of prolactin].

1496. A 4yo child comes with a sprain in his foot. Hx reveals that the child has had recurrent admissions to the hosp due to severe asthma. What is the most appropriate analgesic?

- a. Diclofenac sodium
- b. Ibuprofen
- c. Paracetamol
- d. Codeine

Ans. The key is C. Paracetamol.

1497. A 34yo pregnant woman, 38wk GA is in labor. She had a long 1st stage and troublesome 2nd stage, has delivered a baby. After her placenta was delivered she had a convulsion. What is the most probable management?

- a. MgSO4 IV
- b. Diazepam IV
- c. IV fluid
- d. Hydralazine IV
- e. Anti-epileptic

Ans. The key is A. MgSO4 IV. [Eclampsia, tx is IV MgSO4].

1498. A 23yo woman presents with offensive vaginal discharge. Vaginal pH=4.5. What is the most likely organism?

- a. Gardenella
- b. Trichomonas
- c. Candida
- d. Mycoplasma

Ans. The key is A. Gardenella.

1499. A 62yo man has had ano-rectal pain aggravated by defecation for 3d. Rectal exam: purple, tender lump at the anal verge. Flexible sigmoidoscopy: normal rectal mucosa and hard feces. What is the best management strategy?

- a. Anal hematoma
- b. Anal fissure
- c. Rectal ca
- d. Diverticulitis
- e. Angiodysplasia

Ans. The key is A. Anal hematoma.

1500. A 43yo presents with severe vertigo on moving sideways whilst sleeping. What test would you do to confirm the dx?

- a. Hallpikes maneuvre
- b. Romberg's test
- c. Trendelenburg test
- d. Heel-shin test

Ans. The key is A. Hallpike maneuvre. [Hallpike maneuvre is the preferred method to detect benign positional vertigo].

1501. A 23yo man is having difficulty in speaking following a stab wound to the right of his neck. On being asked to protrude his tongue, the tip deviated to the right. Which anatomical site is most likely to be affected?

- a. Facial nerve
- b. Hypoglossal nerve
- c. Vagus nerve
- d. Trigeminal nerve
- e. Glossopharyngeal nerve

Ans. The key is B. Hypoglossal nerve. [In hypoglossal nerve palsy the tongue will be curved toward the damaged side, combined with the

presence of fasciculations or atrophy of tongue on same side].

1502. A girl presents with signs of hyperventilation. What is the most likely ABG derangement?

- a. pH increased, PCO₂ increased
- b. pH decreased, PCO₂ increased
- c. pH increased, PCO₂ decreased
- d. pH decreased, PCO₂ decreased

Ans. The key is A. pH increased, PCO₂ increased. This is a wrong key. Correct key should be C. pH increased, PCO₂ decreased.

1503. A pt presents with skin pigmentation, diarrhea, vomiting, abdominal pain and postural hypotension. What electrolyte abnormality is likely to occur?

- a. Na⁺=130, K⁺=6.5
- b. Na⁺=130, K⁺=2.5
- c. Na⁺=13, K⁺=6.0
- d. Na⁺=140, K⁺=8
- e. Na⁺=130, K⁺=1.5

Ans. The key is A. Na⁺=130, K⁺=6.5. [In Addison's disease there is low Na⁺, low Cl⁻, low CO₂ and raised K⁺].

1504. A 10yo boy develops nasal bleeding. What is the best way to stop the bleeding from the nose?

- a. Pressure over base of the nose
- b. Ice packs
- c. Pressure over the soft tissues
- d. Nasal packing
- e. Surgery

Ans. The key is C. Pressure over the soft tissues.

1505. A pt came to the hosp with a complaint of severe chest pain lasting for >1h. Following ECG test, pt revealed to have ST depression. He was already on aspirin. What is the most specific tx for this pt?

- a. GTN
- b. Simvastatin
- c. Clopidogrel
- d. BB
- e. LMWH

Ans. The key is B. Simvastatin. It is a wrong key. Correct key should be LMWH. [Specific treatment means treatment particularly adapted to the special disease being treated. LMWH is vital to prevent further events or deterioration and seems to be the most specific drug in the given scenario].

1506. A 69yo woman presents with a sudden onset of weakness of her right arm and leg. She is known to be hypertensive. There has been no headache, LOC, visual, speech or sensory symptoms. Exam: BP=180/90mmHg, pulse=100 and regular heart sounds, no carotid bruit. Higher mental function tests are normal. No apraxia or neglect. Speech, swallowing and sensation are normal. There are no visual field defects. There is a mild facial weakness sparing the forehead. The right arm and leg are flaccid and weak. Reflexes and tone are normal. There is a right extensor plantar response. What is the most likely cause of this pt's symptoms?

- a. Cardioembolic stroke
- b. Lacunar stroke
- c. Right internal carotid artery atheroembolic stroke
- d. Right internal carotid artery dissection
- e. Right vertebral artery atheroembolic stroke

Ans. The key is B. Lacunar stroke. [Weakness of right arm and leg. So lesion is on left side. Hence C,D and E can not be the option. Also no AF or carotid artery disease and features are very much consistent with lacunar infarct].

1507. A 34yo man has an intermittent epigastric pain for 3wks. It is worse by food but helped by some tablets he obtained from the pharmacy. He had a similar episode 3yrs ago and his doctor gave him a course of 3 types of tablets at the time. What is the most appropriate next inv?

- a. Abdomen US
- b. Barium meal
- c. Serum H.Pylori antibodies
- d. C13 urea breath test
- e. Upper GI endoscopy

Ans. The key is D. C13 urea breath test. [Patient was alright for 3yrs after eradication therapy. Now symptoms again may indicate recurrence of H. Pylori infection which can be demonstrated by C13 urea breath test. Serum antibody persist (IgG) for long and not reliable for recheck].

1508. A girl with sickle cell anemia has painful bleeding and vaso-occlusive crisis during her periods. What is the best possible management for this pt?

- a. COCP
- b. Tranexamic acid
- c. Copper IUS
- d. UAE
- e. Depot provera

Ans. The key is E. Depot provera. [Hormone and barrier methods are all acceptable choices but intrauterine devices are not recommended, as they may be associated with uterine bleeding and infection.

Depot contraceptive (Depo-Provera®) is safe and has been found to improve the blood picture and reduce pain crises].

1509. A 70yo pt comes with swelling in the parotid region for the last 10y. Exam: gland is soft and cystic. Choose the most probable dx?

- a. Pleomorphic adenoma
- b. Carcinoma of the salivary glands
- c. Mikulicz's disease
- d. Adenoid cystic carcinoma
- e. Parotid duct stones

Ans. The key is D. Adenoid cystic carcinoma. [Pleomorphic adenoma is firm in consistency not soft and cystic. Also adenoid cystic carcinoma progresses slowly and 15 year survival is 40%].

1510. A 74yo man has been admitted unconscious with no hx. He has a GCS=6 and a dilated left pupil which becomes insensitive to light. What is the single most likely dx?

- a. Extradural hematoma
- b. Meningitis
- c. Opioid OD
- d. Pontine hemorrhage
- e. SAH

Ans. The key is E. SAH. [Extradural hematoma is very rare in elderly and there occurs lucid interval; Features are not consistent with meningitis. Opioid and pontine hemorrhage causes myosis. So likely dx here is SAH].

1511. A 27yo man presents to the ED with 2d hx of severe headache and pyrexia (38.9C). CT: petechial hemorrhage in the temporal and inf frontal lobes. What is the most likely dx?

- a. Brain abscess
- b. Meningococcal meningitis
- c. Cerebral malaria
- d. Herpes simplex encephalitis
- e. New variant CID

Ans. The key is D. Herpes simplex encephalitis. [Petechial hemorrhage in the temporal and inferior frontal lobes are characteristic of Herpes simplex encephalitis].

1512. A 44yo woman with memory loss, poor concentration and inability to recognize household projects. She has right-handed involuntary writhing movement. There is strong fam hx of similar complain. What is the single most likely dx?

- a. Pic's dementia
- b. Wilson's disease
- c. Huntington's disease
- d. HIV associated dementia
- e. Fronto-temporal dementia

Ans. The key is C. Huntington's disease. [A person with Huntington's disease may appear to have a lack of drive, initiative and concentration. Involuntary jerking or writhing movements (chorea). Typical presentation is between 35-55 yrs].

1513. A 54yo man has collapsed suddenly following a headache. He has hypertension and takes warfarin for prosthetic heart valve. GCS=4 and dilated left pupil. What is the single most likely dx?

- a. Ant circulation stroke
- b. Post circulation stroke
- c. Intracerebral hemorrhage
- d. Intracerebellar hemorrhage
- e. Pontine hemorrhage.

Ans. The key is C. Intracerebral hemorrhage. [Headache, collapse, and warfarine use makes the dx of intracerebral hemorrhage most likely.

"Pointers to bleeding (unreliable!): Meningism, severe headache, and coma within hours." OHCM].

1514. A 5wk breast fed baby whose birth weight was 3.5kg and is now 4.5kg is thriving well but is deeply jaundiced. What is the most likely dx?

- a. Galactosemia
- b. Breast milk jaundice
- c. Thalassemia
- d. Sick cell disease
- e. Congenital storage disorder

Ans. The key is B. Breast milk jaundice. [Breast milk jaundice is a type of neonatal jaundice associated with breastfeeding. It is characterized by indirect hyperbilirubinemia, presents in the first or second week of life, and can persist for as long as 12 weeks before spontaneous resolution. There is normal thrive and weight gain. In galactosemia there will be lethargy, vomiting, diarrhea and failure to thrive].

1515. A 71yo man with no prv immediate hx is brought to the ED by his wife who says he has become progressively more forgetful, tends to lose his temper and is emotionally labile. There is no hx of infectious disease or trauma. What's the single most likely dx?

- a. Pic's dementia
- b. Fronto-temporal dementia
- c. Huntington's disease
- d. Alzheimer's disease
- e. Vascular dementia

Ans. The key is D. Alzheimer's disease. [Pic's dementia and fronto-temporal dementia are similar in some way (first personality change then dementia) but in pic's there is odd social behavior like violating etiquettes and says vulgar. In huntington's disease there is changes in personality, cognition and physical skills at the age of 35-45yrs and there is chorea. In vascular dementia there is multiple progressive infarcts and so neurological features may be associated with features of other vascular disease].

1516. A 38yo woman with hemophilia who received several blood transfusions a few years ago presents with irritability and increasing memory deficit. She is unable to speak properly. He is on anti-TB tx. What is the single most likely dx?

- a. Creutzfeldt Jacob disease
- b. Drug toxicity
- c. Vascular dementia
- d. HIV associated dementia
- e. Space occupying lesion

Ans. The key is D. HIV associated dementia. [Blood transfusion is the clue for HIV transmission. Immunodeficiency is also responsible for TB].

1517. An 18yo girl has menorrhagia and dysmenorrhea and requires contraception. What drug will you give her?

- a. COCP
- b. Mirena coil
- c. Copper T
- d. UAE
- e. Depo provera

Ans. The key is A. COCP. [As there is no history about parity and young girl, seems to be nulliparous. Mirena coil is usually given to them who has at least one child].

1518. A pt of tuberculous abscess with the hx of prv abscess drainage presented with fever and tenderness between L2/L3 vertebra. Which is the best inv for this pt?

- a. XR
- b. CT
- c. US
- d. MRI
- e. Blood culture

Ans. The key is D. MRI.

1519. A 4yo child presents with repeated chest infections. He has yellow discoloration of sclera and the mother gives a hx of diarrhea as well. What is the single inv most likely to lead to a dx?

- a. Sweat chloride test
- b. Anti-endomysial antibodies
- c. LFT
- d. Jejunal biopsy
- e. TFT

Ans. The key is A. Sweat chloride test. [Repeated chest infections, and jaundice suggests dx of cystic fibrosis. In the hepatobiliary system which is damaged in about 25 to 30% of the cystic fibrosis patients, malfunctioning secretion can cause liver disease and gall stones, leading to pain and jaundice. For cystic fibrosis sweat chloride test can be done].

1520. An 82yo woman has been admitted from a nursing home with dense hemiplegia and homonymous hemianopia. She is dysphasic. What vessel is most likely to be involved?

- a. Ant cerebral artery
- b. Mid cerebral artery
- c. Post cerebral artery
- d. Internal carotid artery
- e. Post inf cerebellar artery

Ans. The key is B. Mid cerebral artery. [Hemiplegia, homonymous hemianopia, dysphasia these are common features of mid cerebral artery stroke].

1521. A pt is dx with SIADH. Choose the appropriate biochemical change.

- a. Plasma Na⁺ decrease and urine osmolarity increase
- b. Plasma Na⁺ decrease and urine osmolarity decrease
- c. Plasma Na⁺ increase and urine osmolarity decrease
- d. Plasma Na⁺ increase and urine osmolarity increase

Ans. The key is A. Plasma Na⁺ decrease and urine osmolarity increase.

1522. A newborn that is electively intubated at birth and is due for surgery 48h after birth. The condition was suspected on antenatal US on CXR. What is the most likely dx?

- a. CF
- b. Congenital diaphragmatic hernia
- c. Congenital cystic adenomatoid malformation
- d. RDS
- e. Alpha 1 antitrypsin deficiency

Ans. The key is B. Congenital diaphragmatic hernia.

1523. A 63yo male undergoes abdominal surgery. On Monday morning, 3d post-op, repeat samples confirm serum K⁺=7.1mmol/l. His ECG shows broad QRS complexes. Which one of the following can be used as an effective tx for this pt's hyperkalemia?

- a. Calcium chloride IV
- b. Calcium gluconate IV
- c. Insulin subcutaneously
- d. Furosemide IV

Ans. The key is B. Calcium gluconate IV. [Calcium gluconate does not shift potassium into cells or reduce its level but prevents its arrhythmogenic effect on heart and buys time till definitive measures are taken].

1524. A 25yo man attended in urological OPD has single testis. He was inv and other testis was located in the abdomen. What is the best management plan for this pt?

- a. Short trial of HCG
- b. Orchidectomy
- c. Orchidopexy
- d. Reassurance
- e. IV testosterone

Ans. The key is C. Orchidectomy. [Ectopic testis is prone to develop testicular cancer and therefore it should be surgically removed].

1525. A 56yo male who presented with epilepsy like symptoms has been dx with an intracranial space occupying lesion. He now complains of thirst and mild dehydration. His blood glucose is also increased. What is the single most appropriate immediate tx?

- a. Insulin
- b. IV fluids
- c. Stop dexamethasone
- d. Stop sodium valproate and change to another anti-epileptic

Ans. The key is B. IV fluids. [This is stress induced hyperglycemia and not always needs insulin. As dehydration can cause worsening of hyperglycemia our immediate treatment is IV fluid (though it is mild). Later evaluation will be made whether insulin should be given or not].

1526. A mother brings her newborn to the hosp concerned about a blue patch on the buttocks. The newborn is of mixed race and was delivered normally. What is the most appropriate management?

- a. Reassurance
- b. CBC
- c. XR
- d. Plt count

Ans. The key is A. Reassurance. [The diagnosis is mongolian blue or spot. Mongolian spot refers to a macular blue-gray pigmentation usually on the sacral area of healthy infants. Mongolian spot is usually present at birth or appears within the first weeks of life. Mongolian spot typically disappears spontaneously within 4 years but can persist for life. It is a benign condition requiring no intervention].

1527. The ECG of a 65yo shows absent P waves, narrow QRS complex, ventricular rate of 120bpm and irregular R-R interval. What is the most probable dx?

- a. A-fib
- b. A-flutter
- c. SVT
- d. Mobitz type 1 2nd degree heart block
- e. Sinus tachycardia

Ans. The key is A. Atrial fibrillation. [In Atrial fibrillation fibrillatory f waves replaces p waves and R – R interval are irregular].

1528. The ECG of an 80yo pt of IHD shows sawtooth like waves, QRS complex of 80ms, ventricular rate of 150bpm and regular R-R interval. What is the most probable dx?

- a. A-fib
- b. A-flutter
- c. SVT
- d. Mobitz type 1 2nd degree heart block
- e. Sinus tachycardia

Ans. The key is B. Atrial flutter. [Sawtoothlike waves and regular R-R interval are diagnostic of atrial flutter].

1529. A man brings his wife into the ED after finding her unconscious at home. He says at breakfast time she had complained of sudden severe headache. What is the most appropriate inv?

- a. MRI
- b. XR
- c. CT brain
- d. Carotid Doppler

Ans. The key is C. CT brain. [Probable SAH. Among the given option most appropriate is CT brain].

1530. A 68yo lady with T2DM. Which drug should be prescribed?

- a. Biguanides
- b. Sulphonyl urea
- c. Insulin
- d. Lifestyle modifications

Ans. The key is A. Biguanide. [This is an incomplete question and BMI is needed to decide whether biguanide or sulphonylurea be prescribed].

1531. In a laparoscopic mesh repair for hernia, when the trochar is inserted at midpoint between umbilicus and ischial spine. What structure will be pierced?

- a. Linea alba
- b. Rectus muscle
- c. Conjoint tendon
- d. External and internal oblique muscles
- e. Inguinal ligament

Ans. The key is D. External and internal oblique muscles.

1532. A 48yo man has intermittent left sided lower abdominal pain and feels generally unwell. He has lost his appetite and has lost weight. Temp=38.3C and he has BP=190/100mmHg. What is the single inv most likely to lead to dx”?

- a. Colonoscopy
- b. Endomysial antibodies
- c. Fasting serum glucose conc
- d. TFT
- e. US abdomen

Ans. The key is E. US abdomen. [Probable diagnosis is diverticulitis and preferred investigation from given list is US abdomen].

1533. A man with DM comes to the ED after he collapsed at home. His GCS=10. What should be the next initial inv for this man?

- a. Capillary blood sugar
- b. MRI head
- c. CT head
- d. Serum electrolytes

Ans. The key is A. Capillary blood sugar. [It may be either hypoglycemic or hyperglycemic coma which can be detected by checking capillary blood sugar].

1534. A 60yo DM pt presented with easy fatigability, weakness and numbness of hands and swollen feet. Exam: pedal edema, sensory neuropathy and palpable liver and spleen. Urine: proteinuria. US abdomen: enlarged kidney. Renal biopsy: amorphous homogenous substance that stained red with congo-red. What is the dx?

- a. DM retinopathy
- b. Sarcoidosis
- c. Wilms tumor
- d. Amyloidosis
- e. Glycogen storage disease

Ans. The key is D. Amyloidosis [Amyloidosis is a common cause of organomegaly. Also in diabetic nephropathy kidneys may be enlarged].

1535. A 75yo man has urinary symptoms of hesitancy, frequency and nocturia. Rectal exam: large hard prostate. What is the most appropriate inv?

- a. CA 125
- b. CA 153
- c. CA 199
- d. CEA
- e. PSA

Ans. The key is E. PSA. [Urinary symptoms and hard prostate on PR suggests prostatic cancer for which PSA should be done].

1536. A child suffering from CF developed pneumonia. Which organism is responsible for this pneumonia?

- a. H. influenza
- b. Klebsiella
- c. S. aureus
- d. S. pneumonia
- e. Pseudomonas

Ans. The key is E. Pseudomonas. This is wrong key. Correct key is C. S. aureus. [During the first decade of life of CF patients, Staphylococcus aureus and Hemophilus influenzae are the most common bacteria isolated from the sputum, but in the second and third decade of life, Pseudomonas aeruginosa is the prevalent bacteria].

1537. An obese woman with hx of migraine presented with heavy bleeding during menstruation which is painful and needs contraception too. What is the best possible management for this pt?

- a. COCP
- b. Mirena coil
- c. Copper T
- d. UAE
- e. Depo provera

Ans. The key is B. Mirena coil.

1538. A 2yo fell on outstretched hand on playground. He presents with pain on base of the thumb. XR=no fx. What is the single most likely dx?

- a. Colles fx
- b. Head of radius
- c. Mellet finger
- d. Scaphoid fx
- e. No fx

Ans. The key is D. Scaphoid fx. [Scaphoid fracture is often missed in initial x-ray].

1539. A pt was admitted with increased frequency of passing urine, increased thirst, weakness and muscle cramps. What is the most probable dx?

- a. Conn's syndrome
- b. Cushing's syndrome
- c. Pheochromocytoma
- d. Hyperthyroidism
- e. Hypoparathyroidism

Ans. The key is A. Conn's syndrome. [There is hypokalemia in Conn's syndrome. Increased frequency of passing urine and increased thirst are from nephrogenic DI resulted from hypokalemia and hypokalemia also causes weakness and muscle cramps].

1540. A 69yo male presented with sudden onset of dysphagia. He is neither able to swallow liquid nor solid, he recently had a denture fitting. What is the most probable dx?

- a. Foreign body
- b. Plummer vinson syndrome
- c. Achalasia cardia
- d. Esophageal rupture
- e. Esophageal ca 1

Ans. The key is A. Foreign body. [Sudden onset of dysphagia to both liquid and solid and recent history of fitting denture suggests foreign body (denture) in oesophagus].

1541. A 62yo man with chronic schizophrenia presents with a mask like face and involuntary pill rolling movement in both hands. He complains of chronic cough and forgetfulness. He is on long term antipsychotic meds. What is the single most likely dx?

- a. Shy drager syndrome
- b. Parkinsonism
- c. Huntington's chorea
- d. Tardive dyskinesia
- e. Akathisia

Ans. The key is B. Parkinsonism. [Antipsychotic drugs can cause parkinsonism].

1542. A 34yo female presented with vomiting preceded by an occipital headache of acute onset. Exam: conscious and alert with photophobia but no neck stiffness. CT: normal. What is the most appropriate further management?

- a. CT brain with contrast
- b. Repeat CT brain in 24h
- c. CSF exam
- d. Cerebral angio
- e. MRI brain

Ans. The key is C. CSF exam. [Probable subarachnoid hemorrhage. CT may not show any abnormality in early stage in some instances and in that case we shall do CSF examination 12 hours later to see xanthochromia].

1543. A lady with post ileo-colectomy closure of stoma has a small 4cm swelling around the stoma. What is the most appropriate management of the swelling?

- a. Local exploration of swelling
- b. Exploratory laparotomy
- c. Open laparotomy and re-closure
- d. Abdominal binder
- e. Truss
- f. Laparotomy with mesh repair

Ans. The key is A. Local exploration of swelling.

1544. A 64yo woman has been brought by her son for psychiatric evaluation. She says that she has stopped living with her husband because she is convinced it is someone else posing to be him. What kind of delusions is she suffering from?

- a. Delusion of reference
- b. Delusion of control
- c. Delusion of guilt
- d. Delusion of persecution
- e. Delusion of doubles

Ans. The key is B. Delusion of control. This is a wrong key! The correct key is E. Delusion of doubles. [Delusion of control is a false belief that another person, group of people, or external force controls one's general thoughts, feelings, impulses, or behavior. The delusion of doubles, is a rare disorder in which a person holds a delusional belief that different people are in fact a single person who changes appearance or is in disguise].

1545. A 19yo man with known hx of OM presents with headache, lethargy, sweating and shivering. What is the single most likely dx?

- a. Furuncle
- b. Meningitis
- c. Myringitis
- d. Nasopharyngeal tumor
- e. OM

Ans. The key is B. Meningitis. [OM often can be a cause of intracranial extension leading to cerebral abscess or meningitis].

1546. A 46yo woman has gained weight. She has sensitivity to cold. Her pulse = regular at 50bpm and heart=enlarged. What is the single most likely underlying mechanism for this condition

- a. Autoimmune
- b. Degenerative
- c. Congenital
- d. Infective
- e. Nutritional

Ans. The key is E. Nutritional. This is a wrong key. Correct key is Autoimmune hypothyroidism. [The most common cause of hypothyroidism in UK is autoimmune hypothyroidism. In developing countries it is often nutritional (iodine deficiency).The diagnosis is autoimmune hypothyroidism (in hypothyroidism heart is often gets enlarged)].

1547. A 70yo man presents with a punched out ulcer between his toes. He is a heavy drinker and smoker. Exam: ulcer is yellow and the foot turns red when dangling off the bed. What is the single most likely dx?

- a. Arterial ischemia ulcer
- b. Malignancy
- c. Neuropathic ulcer
- d. Pressure ulcer
- e. Venous stasis ulcer

Ans. The key is A. Arterial ischemic ulcer.

1548. A 65yo woman complains of a painful discharging ulcer above her ankle on the inner side of her left lower leg. Exam: the base of the ulcer is red and covered by a yellow fibrous tissue. The border is irregular. The skin is tight. What is the single most likely dx?

- a. Arterial ischemia ulcer
- b. Malignancy
- c. Neuropathic ulcer
- d. Pressure ulcer
- e. Venous stasis ulcer

Ans. The key is E. Venous stasis ulcer. [Some people with venous insufficiency develop stasis dermatitis. Blood pools in the veins of the lower leg. Fluid and blood cells leak out of the veins into the skin. It is usually seen above ankle and inner side of leg].

1549. A 55yo woman suffered from an acute MI 5d ago. While she was in the hosp the pt developed features of pulmonary edema and heart failure. What is the most probable cause of her present condition?

- a. VSD
- b. Ruptured papillary muscle
- c. Pericarditis
- d. A-fib
- e. Re-infarction

Ans. The key is B. Ruptured papillary muscle. [Post MI rupture of papillary muscle is responsible for valve failure (mitral regurgitation) causing pulmonary oedema and heart failure].

1550. A 76yo woman presents with deep stroke 6h ago. What would the immediate tx be?

- a. Aspirin 75mg
- b. Aspirin 300mg
- c. Streptokinase
- d. IV heparin
- e. Dipyridamole 200mg

Ans. The key is B. Aspirin 300mg.

1551. A 19yo man accuses his friend of making his right arm swing out at a stranger. What is the best term to describe his condition?

- a. Control
- b. Persecution
- c. Guilt
- d. Reference
- e. Grandeur

Ans. The key is A. Control. [Delusion of control is a false belief that another person, group of people, or external force controls one's general thoughts, feelings, impulses, or behavior].

1552. A 26yo man with hx of hereditary hemorrhagic telangiectasia is planning to start a family. What is the mode of inheritance?

- a. AD with incomplete penetrance
- b. Autosomal co-dominant
- c. AR with incomplete penetrance
- d. AD
- e. AR

Ans. The key is D. AD [Hereditary hemorrhagic telangiectasia is of autosomal dominant mode of inheritance].

1553. A 50yo man with a known hx of stroke is unable to get out of his house because he can't find where the door is. He refuses help from his wife and says he is not blind. What is the single most likely defect?

- a. Paracentral scotoma
- b. Tunnel vision
- c. Total blindness
- d. Central scotoma
- e. Cortical blindness

Ans. The key is E. Cortical blindness. [Cortical blindness is the total or partial loss of vision in a normal-appearing eye caused by damage

to the brain's occipital cortex. Rarely, a patient with acquired cortical blindness may have little or no insight that they have lost vision, a phenomenon known as Anton-Babinski syndrome].

1554. An elderly lady presents with confusion. She is afebrile but complains of dysuria for 2d duration. What is the def dx inv?

- a. Blood culture
- b. Urine nitrates
- c. CT head
- d. ECG
- e. IVU

Ans. The key is B. Urine nitrates. [Dysuria is suggestive of UTI. UTI also can lead to confusion. Urine nitrates if positive is diagnostic of UTI].

1555. A 40yo woman on chemotherapy for metastatic breast carcinoma now presents with painful swallowing. Exam: she has white plaques on top of friable mucosa in her mouth and more seen on esophagoscopy. What is the most effective tx for this pt?

- a. Antispasmodic
- b. H2 blocker
- c. Antibiotics
- d. Antifungals
- e. I&D

Ans. The key is D. Antifungal. [Features are consistent with esophageal candidiasis which is treated with Oral fluconazole (200-400 mg daily) or IV fluconazole for 14-21 days].

1556. A 43yo woman has suffered with heavy periods for many years and has tried many medical tx without success. She is constantly flooding and at times can't leave her house due to heavy bleeding. She has completed her family of 5 children and her last blood test showed Hgb=8.9g/dl. She feels that she can't cope with the bleeding anymore and her husband is asking for a tx that can guarantee success. What is the most appropriate management to improve menorrhagia in this pt?

- a. Endometrial ablation
- b. Hysterectomy
- c. Hysteroscopic/Laser resection of fibroids
- d. Myomectomy
- e. UAE

Ans. The key is B. Hysterectomy. [As family is complete hysterectomy

is the best option to stop bleeding and it also helps not to get endometrial carcinoma].

1557. A man on antipsychotic meds develops features of retinitis pigmentosa. Which drug is most likely to cause these symptoms?

- a. Thioridazine
- b. Haloperidol
- c. Chlorpromazine
- d. Risperidone

Ans. The key is A. Thioridazine. [Thioridazine and other antipsychotics (neuroleptics, dopaminergic antagonists) can cause degenerative retinopathies with histological, electrophysiological and symptomatic features similar to those of primary retinitis pigmentosa].

1558. Pt with low Hgb, MCV=76, angular stomatitis, red tongue, and koilonychia. What is the most probable dx?

- a. Folate def
- b. B12 def
- c. Iron def
- d. Vit E def
- e. Hemolytic anemia

Ans. The key is C. Iron deficiency anemia. [Low MCV, angular stomatitis, red tongue and koilonychia are characteristic of iron deficiency anemia].

1559. A pt with sudden severe eye pain, red eye, visual blurring, acuity of only finger counting, nausea, vomiting with a shallow ant chamber that is hazy on shining a torch. What is the dx?

- a. CRVO
- b. Acute closed angle glaucoma
- c. Uveitis
- d. Iritis
- e. Open angle glaucoma

Ans. The key is E. Open angle glaucoma. This is a wrong key! The correct key is B. Acute closed angle glaucoma. [Sudden severe eye pain, red eye, visual blurring, acuity of only finger counting, nausea, vomiting, shallow anterior chamber that is hazy on shining torch are all classic presentation of acute closed angle glaucoma].

1560. A pt who works in a pet shop has temp=37.5C, dyspnea, chest pain and cough. CXR: patchy consolidation. What is the most suitable tx?

- a. Amoxicillin
- b. Tetracyclin
- c. Erythromycin
- d. Clarithromycin
- e. Penicillin

Ans. The key is A. Amoxicillin. This is a wrong key! Correct key is D. Clarithromycin. [OHCM, 9th edition].

1561. A 50yo man complains of dysphagia after eating bread. Barium swallow reveals a lower esophageal ring. What is the most appropriate tx?

- a. Reassurance
- b. Antispasmodics
- c. Dilatation of the LES
- d. Endoscopic diverticulectomy
- e. I&D

Ans. The key is C. Dilatation of the LES. [Patients with recurrent symptoms from esophageal rings and webs require repeat esophageal dilation. Repeat esophageal dilation is safe and can relieve symptoms in the long term].

1562. A 48yo nulliparous woman feels tired all the time. Her periods are regular but have always lasted for at least 10d. Choose the single most appropriate initial inv?

- a. High vaginal swab
- b. Serum Hgb conc
- c. TFT
- d. None
- e. Abdominal US

Ans. The key is B. Serum Hb conc. [Feeling tired all the time and prolonged period suggest anemia. So serum Hb should be done initially].

1563. A man got his hand caught in machinery at work. The fingers are swollen but the XR shows no fx. What is the most appropriate management?

- a. Splint
- b. Put in plaster
- c. Broad arm sling for 1wk

- d. Elevate in high sling for 2d
- e. Neighbor strapping

Ans. The key is D. Elevate in high sling for 2d. [Extravasation of blood caused this swelling along with inflammation for which best option is elevate in high sling for 2d which will help improve symptom by gravitational shift of fluid from hand].

1564. A 39yo woman presents with symptoms recurring annually characterized by depressed mood, being socially withdrawn hypersomnia, lack of enjoyment in life, last for several months. What is the most likely dx?

- a. Seasonal Affective Disorder
- b. Mod depression
- c. Dysthymia
- d. GAD
- e. Bipolar disorder

Ans. The key is A. Seasonal Affective Disorder. [Depression associated with late autumn and winter and thought to be caused by a lack of light].

1565. A 75yo man presents with ARF. He has been troubled by recurrent epistaxis but over the last 3wks he reports to have coughed up blood too. What is the single most likely positive antibody?

- a. pANCA
- b. cANCA
- c. Anti Ro
- d. Anti dsDNA
- e. Anti centromere

Ans. The key is B. cANCA. [ARF and recurrent epistaxis and hemoptysis suggests Wegener's granulomatosis for which cANCA is most specific].

1566. A woman is admitted to the hosp for elective abdominal hysterectomy. 2m ago she was dx with DVT and pulmonary embolism and was started on warfarin. What is the most appropriate preop measure you will take on this occasion?

- a. Continue warfarin
- b. Stop warfarin
- c. Stop warfarin and start heparin
- d. Increase warfarin dose
- e. Add heparin

Ans. The key is C. Stop warfarin and start heparin.

1567. This condition affects middle aged women more than men and is characterized by low mood, early morning waking, loss of libido, tiredness and suicidal intention last for at least 2wks. What is the most probable dx?

- a. Bipolar affective disorder
- b. Dysthymia
- c. Major depressive disorder
- d. Schizoaffective disorder
- e. Recurrent brief depression

Ans. The key is C. Major depressive disorder. [Given case is severe depression (major depressive disorder)].

Mild depression: i) Low mood ii) Anhedonia iii) Guilt iv) Hopelessness v) Worthlessness vi) Inability to concentrate. Tx CBT

Moderate depression: Features of mild + vii) Poor sleep viii) Poor Appetite ix) Poor libido x) Easy fatigability. Tx Antidepressants

Severe depression: Features of moderate + xi) Suicidal intentions. Tx ECT

Psychotic depression: Features of severe + xii) Hallucinations xiii) Delusions xiv) Guilt xv) Nihilistic delusion. Tx ECT].

1568. A 10yo boy has fallen from a tree and injured his right chest. He has pain and difficulty breathing. He is tachypenic and tender with an area of paradoxical chest wall movement on the right side. What is the single most likely dx?

- a. Diaphragmatic rupture
- b. Flail chest
- c. Fx ribs
- d. Hemothorax
- e. Tension pneumothorax

Ans. The key is B. Flail chest. [In flail chest multiple adjacent ribs are broken in multiple places, separating a segment, so a part of the chest wall moves independently. Pain, difficulty breathing, tachypnea and tender area of chest wall movement suggest flail chest].

1569. A 37yo woman had an elective LSCS 1d ago. You are called to see her as she becomes SOB with left sided chest pain and a cough. She has had 3 children, 2 born by LSCS. Exam: she has reduced air entry at left lung base. Her observations include sat=92% on air, BP=105/84mmHg, pulse=120bpm, temp=37.2C. Choose among the options which C-section complications has she developed?

- a. Aspiration pneumonia
- b. Aspiration pneumonitis
- c. Spontaneous pneumothorax
- d. Pulmonary embolism
- e. DVT

Ans. The key is D. Pulmonary embolism. [Absence of wheeze and near normal temperature makes aspiration as unlikely diagnosis and favours the diagnosis of pulmonary embolism].

1570. A pt presents with increasing retrosternal pain and dysphagia for both solids and liquids over 18m but denies weight loss. Chest is clear. What is the most likely dx?

- a. Achalasia
- b. Pharyngeal carcinoma
- c. Esophageal spasm
- d. Esophageal stricture

Ans. The key is C. Esophageal spasm. [DES manifests as intermittent difficulty swallowing (dysphagia) for solid foods and liquids, and atypical chest pain. The chest pain may appear similar to cardiac chest pain (angina pectoris). In achalasia there is chest findings of aspiration pneumonia and weight loss. So this is unlikely to be achalasia].

1571. A 70yo man presents with a fluctuant swelling of the scrotum which feels like worms when he is standing but regresses when he lies down. What is the most probable dx?

- a. Varicocele
- b. Hydrocele
- c. Testicular ca
- d. Epididymal cyst
- e. Saphena varix

Ans. The key is A. Varicocele. [Fluctuant swelling of the scrotum which feels like worms are suggestive of varicocele].

1572. A 52yo woman has had a swelling in the neck, hoarseness and stridor-both inspiratory and expiratory for 2m. What is the most probable dx?

- a. Ca larynx
- b. Ca thyroid
- c. Vocal chord nodules
- d. Ca bronchus
- e. Thyrotoxicosis

Ans. The key is B. Ca thyroid. [There is no features of hyperthyroidism. So it is not thyrotoxicosis but Ca thyroid].

1573. A woman became acutely SOB in the recovery bay and is coughing after GA. Auscultation: reduced air entry at the right lung base and diffuse wheeze. Observation: HR=88bpm, BP=112/76mmHg, temp=37.8C and sat=91% in air. Choose among the options which C-section complication has she developed?

- a. Aspiration pneumonitis
- b. Spontaneous pneumothorax
- c. Endometritis
- d. Pulmonary embolism
- e. Tension pneumothorax

Ans. The key is A. Aspiration pneumonitis. [Diffuse wheeze, reduced air entry at lung base and raised temperature favours the diagnosis of aspiration pneumonitis].

1574. A 23yo female presents with paresthesias and loss of distal pulses in her arms. She is noted to be hypertensive. She describes feeling unwell a month prior with fever and night sweats. What is the most probable dx?

- a. Kawasaki disease
- b. Takayasu arteritis
- c. Buerger's disease
- d. Embolism
- e. Raynaud's phenomenon

Ans. The key is B. Takayasu arteritis [Takayasu arteritis is a granulomatous inflammation of the aorta and its major branches. Criteria:

Age of 40 years or younger at disease onset

Claudication of the extremities

Decreased pulsation of 1 or both brachial arteries

Difference of at least 10 mm Hg in systolic blood pressure between arms

Bruit over 1 or both subclavian arteries or the abdominal aorta

Arteriographic narrowing or occlusion of the entire aorta, its primary branches, or large arteries in the upper or lower extremities that is not due to arteriosclerosis, fibromuscular dysplasia, or other causes].

1575. A 35yo woman presents with mass in the groin. Exam: mass found just below and lateral to the pubic tubercle. There is no cough impulse and it is irreducible. What is the most probable dx?

- a. Direct inguinal hernia
- b. Strangulated hernia
- c. Femoral hernia
- d. Saphenavarix
- e. Femoral aneurysm

Ans. The key is C. Femoral hernia. [Mass below and lateral to the pubic tubercle is suggestive of femoral hernia].

1576. A 30yo woman has injured her left lower chest in a RTA. She has BP=80/50mmHg, pulse=120bpm. Auscultation of chest=bowel sounds present. What is the single most likely dx?

- a. Diaphragmatic rupture
- b. Flail chest
- c. Fx ribs
- d. Ruptured esophagus
- e. Tension pneumothorax

Ans. The key is A. Diaphragmatic rupture. [Bowel sound present on auscultation of chest following RTA causing lower chest injury is suggestive of diaphragmatic rupture].

1577. A lady presents with a swelling below the groin crease that can be reduced. There is no med hx of note. What is the most probable dx?

- a. Inguinal hernia
- b. Strangulated hernia
- c. Testicular tumor
- d. Epididymal cyst
- e. Femoral hernia

Ans. The key is E. Femoral hernia.

1578. A 32yo woman of 38wks GA attends the antenatal day unit with pain in the suprapubic area that radiates to the upper thighs and perineum. It is worse on walking. Her urine dipstick showed a trace of protein but no white cells, nitrates or blood. What's the most likely dx?

- a. Braxton hicks contractions
- b. Round ligament stretching
- c. Symphysis pubis dysfunction
- d. Labor
- e. Complicated femoral hernia

Ans. The key is C. Symphysis pubis dysfunction.

[Symptoms can include:

pain over the pubic bone at the front in the centre

pain across one or both sides of lower back

pain in the area between vagina and anus (perineum)

Pain can also radiate to thighs.

Cause: stiffness of pelvic joints or the joints moving unevenly at either the back or front of pelvis during pregnancy. Physiotherapy is helpful]. [Ref: NHS]

1579. A 45yo mechanic presents with a reducible swelling in the groin, impulse on coughing is present. He has mild dragging pain in the abdomen, otherwise he's normal. What is the best management strategy?

- a. Truss
- b. Elective herniorrhaphy
- c. Urgent herniorrhaphy
- d. Elective herniotomy
- e. Reassure

Ans. The key is D. Elective herniotomy. This is wrong key! Correct key is B. Elective herniorrhaphy. [Usually before the age of 30, recurrence rate of hernia after herniotomy is much less but after 30 recurrence is high. So Herniotomy is done at the age less than 30. As the presenting case is of 45 yrs we should do herniorrhaphy in this patient].

1580. A 25yo man present with a mass in the groin after heavy lifting. Exam: mass is found just above and medial to the pubic tubercle. It is reducible. On applying pressure on the internal ring, cough impulse is still present. What is the most likely dx?

- a. Direct inguinal hernia
- b. Indirect inguinal hernia
- c. Femoral hernia
- d. Strangulated hernia
- e. Femoral aneurysm

Ans. The key is A. Direct inguinal hernia. [On occlusion of deep inguinal ring if cough impulse still present (visible cough impulse) on medial to occluded ring it is direct inguinal hernia].

[Cough impulse negative means after occluding deep ring there will be no visible cough impulse and positive means there will be visible cough impulse. Negative cough impulse=indirect hernia; positive cough impulse=direct inguinal hernia].

1581. A 35yo woman presents with a swelling in the neck. The swelling has increased in size gradually over the last two years and the patient feels she has difficulty with breathing. Exam: mass measures 8cm by 10 cm, soft and not warm to touch. It moves with deglutition. Which is the most appropriate management of this mass?

- a. Partial thyroidectomy
- b. Oral thyroxine
- c. Oral propylthiouracil
- d. Excision biopsy

Ans. The key is A. Partial thyroidectomy. [Gradually increased swelling in the neck which moves with deglutition is thyroid enlargement and as it is causing pressure symptom like difficulty in breathing a partial thyroidectomy should be performed].

1582. A 46yo laborer reports swelling in the right groin. The non-painful swelling is observable in both the erect and the recumbent positions. Exam: non-tender irreducible 4 cm mass in the right groin below and on the medial side of the inguinal ligament. Which is the most likely dx in this pt?

- a. Indirect inguinal hernia
- b. Femoral hernia
- c. Saphenous vein varicocele
- d. Hydrocoele

Ans. The key is C. Saphenous vein varicocele. This is a wrong key! Correct key is B. Femoral hernia. [Saphenous vein varicocele is readily reducible with recumbent position. So presented case is not sapha-

navarix. Usual location of femoral hernia is below and lateral to pubic tubercle but it is not absolute and it is possible for femoral hernia to present as mass below and medial to pubic tubercle. So the presented case is a case of femoral hernia].

1583. A camel rider sustained a kick to the lateral side of his right leg just below the knee caused by the camel stick. The site is slightly bruised and tender to touch. During physical examination, he is unable to either dorsiflex or evert the foot. There is loss of sensation over the front and outer half of the leg and dorsum of the foot. If these observations are the result of damage to a nerve bundle, which is the most likely nerve affected?

- a. Lateral popliteal
- b. Peroneal
- c. Tibia
- d. Sural

Ans. The key is B. Peroneal. [Inability of dorsiflex and foot eversion with sensory loss over front and outer half of leg and dorsum of foot are seen in peroneal nerve injury].

1584. A 46yo woman presents with sudden episode of abdominal pain which started about 2h ago. The pain is located in the epigastrium and radiates to her back. She has vomited twice since the onset of attack. The pain is made worse by lying flat on her back and she is more comfortable sitting up and bending forwards. She was informed of the presence of gallstones in her gall bladder four weeks earlier when she reported pain in the right hypochondrium. The oral temp=39C, BP=120/80mmHg and the radial pulse=118/min. There is no jaundice but there is marked tenderness in the epigastrium both on deep and superficial palpations. Which is the most appropriate inv for the cause of the patient's pain?

- a. Plain abdominal X-ray
- b. Serum Amylase
- c. Serum bilirubin
- d. Barium Swallow

Ans. The key is B. Serum amylase. [Epigastric pain radiating to back, worse on lying flat and comfort on bending forward are classic presentation of acute pancreatitis in which serum amylase is increased].

1585. A 75yo Japanese woman reports repeated episodes of vomiting of undigested food mixed with blood. She has lost 5 kgs in weight over the last one month. Clinical exam: shows a frail woman with mild conjunctival palor. Exam: non-tender slightly mobile mass in the epigastric region. Which is the most likely dx?

- a. Colon cancer
- b. Gastric cancer
- c. Gall bladder cancer
- d. Oesophageal cancer

Ans. The key is B. Gastric cancer. [Non-tender mass in epigastrium, conjunctival pallor (anemia), weight loss, vomiting of undigested food mixed with blood due to pyloric obstruction by cancer mass and particularly Japanese (highest incidence of gastric cancer due to taking smoked fish) are suggestive of gastric cancer].

1586. A 45yo man, known to be chronically addicted to alcohol, presents in the ED and reports two episodes of vomiting fresh bright red blood in the previous 6h. He estimated the volume blood vomited at each bout to be more than 500mls. Clinical exam: the radial pulse=120/min, BP=90/60mmHg. There is no mass or tenderness in the epigastrium. The liver is palpable for 3 cm below the costal margin and not tender. The patient is not jaundiced. The physician resuscitates the patient with oxygen by face mask, rapid infusion of intravenous normal saline while he requests for haemoglobin level and whole blood for transfusion. Which is next appropriate step in management?

- a. Barium Swallow
- b. Exploratory laparotomy
- c. CT scan of the abdomen
- d. Upper gastrointestinal endoscopy

Ans. The key is D. Uppergastrointestinal endoscopy. [The likely diagnosis is bleeding oesophageal varices which should be diagnosed by endoscopy and if needed stappling can be done with endoscope].

1587. A 42yo woman reports to the surgeon that she is worried about a lump that she feels the right breast. The surgeon observes a 2 cm by 3 cm mass in the right lower quadrant of the breast. There are no associated skin changes and the mass has limited mobility. There is no discharge from the nipple. There is no axillary lymph node enlargement. Examination of the left breast and axilla was completely normal. A mammogram report suggests the presence of microcalcifications. Which is the most appropriate next step in the management of this pt?

- a. Observation for one year and repeat the mammography
- b. A needle-guided biopsy of the breast
- c. Excision biopsy of the breast
- d. Partial mastectomy

Ans. The key is B. A needle-guided biopsy of the breast.

1588. A 45yo man presents with a mass on the right side of the face. The mass was first observed three months ago but has recently become visibly larger. He feels pain over the mass and is unable to blow a whistle. Clinical examination shows that the mass is likely to be the parotid gland. An oral examination shows a foul smelling discharge from the duct of the gland and gentle probing shows that it is stenosed at the meatus. Which of the following features suggests that the mass might be malignant?

- a. Presence of pain
- b. Recent enlargement
- c. Facial nerve palsy
- d. Stenosed duct meatus

Ans. The key is C. Facial nerve palsy. [Due to malignant infiltration].

1589. A 6yo boy presents with jaundice following treatment with sulphathiazole. Investigations suggest that the jaundice is due to haemolysis caused by G6DP deficiency. Which is true regarding etiology of G6DP deficiency?

- a. Inherited as autosomal dominant condition
- b. Inherited as sex-linked dominant condition
- c. Inherited as sex-linked recessive condition
- d. Results from auto-antibodies to red cell antigens

Ans. The key is C. Inherited as sex-linked recessive condition.

1590. A 5yo previously healthy child has a 1-day history of severe pain in the throat, breathing difficulties and fever. On examination you find an anxious, septic-looking child with drooling of saliva and stridor. Which is the most appropriate initial management?

- a. Intubation under general anaesthesia
- b. Insertion of nasogastric tube
- c. Fluid resuscitation and antibiotics IV
- d. Anteroposterior & lateral neck x-ray

Ans. The key is A. Intubation under general anaesthesia. [Acute epiglottitis. Should intubate to save from closure of airway].

1591. A 6yo boy has been noticed to have problems with co-ordinating his voluntary movements over the last two years. He has a waddling gait and needs to support himself on his hands when rising from the floor. He has larger calves than other boys but he runs more slowly. Which is the most likely dx?

- a. Myotonia
- b. Myasthenia gravis
- c. Duchenne muscular dystrophy
- d. Muscular atrophy

Ans. The key is C. Duchenne muscular dystrophy. [The child having difficulty with walking, running, jumping and climbing stairs. Walking may look different with a 'waddling' type of walk. The boy may be late in starting to walk (although many children without DMD also walk late).

When you pick the child up, you may feel as if he 'slips through your hands', due to looseness of the muscles around the shoulder.

The calf muscles may look bulky, although they are not strong.

As he gets older, the child may use his hands to help him get up, looking as if he is 'climbing up his legs'. This is called 'Gower's sign'].

1592. A previously healthy, 10m female child presents to your clinic with a 1-day history of high fever, runny nose and conjunctivitis. The child looks unwell and is irritable. Exam: child's oropharynx shows that it is inflamed and there are small white spots on the oral mucosa. Which is the most likely dx?

- a. Kawasaki disease
- b. Parvovirus infection
- c. Herpes zoster
- d. Measles

Ans. The key is D. Measles. [Koplick's spots are characteristic of measles].

1593. A 3d term, breast-fed infant is brought by the mother who reports that the child has not been active and not feeding well. She also notices jaundice, which was not present at birth and is increasing. Exam: the temp=35.4°C, and the liver is palpable 2 cm below the costal margin. Which is the most likely dx?

- a. Rhesus isoimmunisation
- b. Inadequate breast milk
- c. Congenital biliary tract obstruction.
- d. Sepsis

Ans. The key is D. Sepsis. [Not active, not feeding well, increasing new onset jaundice and hypothermia are suggestive of neonatal sepsis].

1594. A 65yo woman with DM, HTN and normal kidney function underwent a total right hip replacement. She had massive haemorrhage during the operation and was given 8 units of packed RBC. The blood pressure dropped to 60/40 mm Hg for about two hours before it was corrected with blood transfusion. Two days after the surgery the serum creatinine level rose to 4.2 mg/dl (normal <1.5 mg/dl), BUN was 50 mg/dl (normal 10-20 mg/dl) and potassium 5.0 mmol/L (normal 3.5-5.0 mmol/L). There were brown granular casts in the urine sediment. Which is the most likely cause of this complication?

- a. Diabetic nephropathy
- b. Malignant hypertension
- c. Acute tubular necrosis
- d. Interstitial nephritis

Ans. The key is C. Acute tubular necrosis. [Hypotension even for some minutes or few hours can readily lead to acute tubular necrosis which is evident here by uremia and further supported by brown granular cast in the urine sediment].

1995. A 78yo pt is diagnosed with metastatic lung cancer; there is no cure for his condition. His son tells the physician that in the case of a diagnosis of cancer, the physician must not tell his father. He wishes that his father does not suffer any psychological distress caused by the knowledge of a terminal diagnosis. Which one of the following ethical principles supports the son's request?

- a. Patient autonomy
- b. Beneficence
- c. Justice
- d. Non-maleficence

Ans. The key is D. Non-maleficence. [Nonmaleficence means non-harming or inflicting the least harm possible to reach a beneficial outcome].

1596. A 23yo single male was brought to Emergency exhausted and frightened. His father tells you that his son, who was previously healthy, had, for no apparent reason, a sudden attack of fear, dizziness, sweating, palpitations and the feeling that his heart is going to stop beating. The symptoms started to decrease gradually after about 10 minutes. Which is the most likely dx?

- a. Panic attack
- b. Delirious state
- c. Alcohol withdrawal phenomena
- d. Social phobia

Ans. The key is A. Panic attack. [a sudden feeling of acute and disabling anxiety; often fear of death].

1597. A 30yo woman, G2P1, at 37 weeks gestation mentions that her 3-year-old son has just developed chickenpox. She is not certain whether she has had the disease herself. Which is the next step in management?

- a. Administration of varicella-zoster immune globulin IM
- b. Measurement of varicella IgM level
- c. Acyclovir tablets orally
- d. Measurement of varicella IgG level

Ans. The key is D. Measurement of varicella IgG level. [If previous infection is doubtful do varicella IgG level].

1598. A 24yo primigravida presents to the ED with a history of 8-week amenorrhoea followed by heavy vaginal bleeding and severe, crampy abdominal pain. Exam: HR=110/min and BP=120/80mmHg. The uterus is bulky. The cervix is dilated and there is active bleeding from the cervical os, but no tissue has been expelled. Which of the following is the most likely dx?

- a. Inevitable abortion
- b. Threatened Abortion
- c. Incomplete abortion
- d. Missed Abortion

Ans. The key is A. Inevitable abortion. [when os is closed threatened and when os is opened inevitable abortion (No tissue has been expelled)].

1599. A 46yo woman comes for a routine gynaecological visit. On pelvic examination, a 1-cm red, granular lesion is noted on the posterior cervical lip, which is firm and bleeds on contact. Which is the next best step for establishing a dx?

- a. Cervical cytological smear
- b. Punch biopsy
- c. Transvaginal ultrasound
- d. Colposcopy

Ans. The key is B. Punch biopsy.

1600. A 31yo woman, G5P4, who has amenorrhoea for 12 weeks and a positive pregnancy test presents to the ED with vaginal bleeding. Symphysial-fundal height measurement corresponds to 22 weeks gestation. Ultrasound examination reveals bilateral cystic masses. No fetal parts are seen during the examination. The cervix is closed. Which is the most likely dx?

- a. Tubal pregnancy
- b. Endometriosis
- c. Hydatidiform mole
- d. Threatened abortion

Ans. The key is C. Hydatidiform mole. [In molar pregnancy uterus is more enlarged than gestational age and on US no fetal part but cystic masses are seen].

The final set (1601-1700) is done by DR. ARIF SIDDIQUI and EDITED by me. Thanks Dr. Siddiqui for his kind contribution!

1601. A married 25yo woman presents with 6h hx of abdominal pain located in the LIF. The pain is persistent, of increasing intensity and not radiating first experienced while she was lying down. She feels giddy when she tries to stand erect. The last menstrual period was 6 weeks ago. The radial pulse=130/min and BP=80/40 mmHg. Pelvic US shows free intra-peritoneal fluid. What is the most appropriate next step in management?

- a. Immediate laparoscopy.
- b. Immediate laparotomy.
- c. Pregnancy test (urine or serum).
- d. Observation for 24 hours in the ICU

Ans. The key is B. Immediate laparotomy. [As the patient is in shock it is ruptured ectopic pregnancy. So the next step is immediate laparotomy].

1602. A 40yo man has fallen off a roof. He is shocked and has chest pain. There is a delay between the radial and femoral pulse. His CXR=widening of the mediastinum. What is the single most likely dx?

- a. Cardiac tamponade
- b. Diaphragmatic rupture
- c. Fx ribs
- d. Tension pneumothorax
- e. Traumatic rupture of aorta

Ans. The key is E. Traumatic rupture of the aorta. [A traumatic aortic disruption is caused by a rapid acceleration (or deceleration) causing a tear in the aorta. Normally this is immediately fatal, but those who survive may show a widened mediastinum on CXR. This can be confirmed with CT scan or angiography of the aorta and requires prompt surgical correction. Stable the haemodynamics and surgical correction. Note: pts with diaphragmatic rupture usually presents days after trauma with vague symptoms, history is vital].

1603. A 36yo woman presents with swelling in the groin. Exam: swelling is diffuse and soft and lies below the inguinal ligament. It empties with minimal pressure and refills with release. There is a cough impulse and it disappears on lying down. On the calf of the same leg there are varicosities on the medial aspect. What is the most likely dx?

- a. Varicose vein
- b. Varicocele
- c. Saphena varix
- d. Femoral hernia
- e. Inguinal hernia

Ans. The key is C. Saphena Varix. [Below inguinal ligament, empties with minimal pressure and refills with release, presence of cough impulse and disappearance on lying down are suggestive of caphena varix supported by presence of varicosity in same leg].

1604. A man presents with a swelling above the groin crease in the abdomen. He has not had any med problems of note. What is the most probable dx?

- a. Inguinal hernia
- b. Spigelian hernia
- c. Testicular tumor
- d. Epididymal cyst
- e. Irreducible hernia

Ans. B. Spigelian Hernia. [A Spigelian hernia (or lateral ventral hernia) is a hernia through the spigelian fascia, which is the aponeurotic layer between the rectus abdominis muscle medially, and the semilunar line

laterally].

1605. A 70yo man presents with acutely painful, pale paralysed and pulseless left leg. He is noted to have a-fib. What is the most probable dx?

- a. Intermittent claudication
- b. Cardiovascular syphilis
- c. Buerger's disease
- d. Chronic limb ischemia
- e. Acute limb ischemia

Ans. The key is E. Acute limb ischemia. [AF may be the cause of thrombus leading to embolic acute limb ischemia].

1606. A 50yo woman complains of several months hx of weakness and difficulty climbing stairs. Exam: fissuring of the skin of her hands. CXR: pulmonary fibrosis. What is the single most likely positive antibody?

- a. Anti Jo1
- b. Anti Scl 70
- c. Anti Ro
- d. Anti dsDNA
- e. Anti centromere

Ans. A. Anti Jo1. [Anticentromere would be present in limited scleroderma and Anti-Scl 70 would be present in diffuse scleroderma. Anti-DSDNA would be positive in SLE, along with Anti-Ro. Anti-Ro is also positive in Sjogren's syndrome and scleroderma. This is a case of Polymyositis because none of the others would have the muscular weakness that is present in this case. The antibody of choice would be Anti Jo1 antibody].

1607. A 65yo woman complaining of symptoms suggestive of Raynaud's phenomenon and difficulty in swallowing. Exam: painful lesions on her finger tips and facial telangiectasis. What is the single most likely positive antibody?

- a. Anti Jo1
- b. Anti Scl 70
- c. Anti Ro
- d. Anti ds DNA
- e. Anti centromere

Key: Anti-Centromere (E)

Reason: Anti-centromere antibody would be present in CREST syndrome which is also called Limited scleroderma. Features of given case are consistent with CREST syndrome and hence the answer is E.

Anti centromere antibody].

1608. A 6yo boy presented about 4h ago with acute severe pain on the testis with the left half slightly higher than the right. Pain was not relieved by any strong analgesic. What is the initial management?

- a. Give strong analgesic
- b. IV NS and monitor vital signs
- c. Reassure
- d. Immediate surgical referral
- e. Cover with antibiotics

Ans. The key is D. Immediate surgical referral. [Dx torsion of testis].

1609. A 60yo man is brought to the ED in an agitated state. He is lashing out violently. Which drug in low dosage due to its relative lack of autonomic side effects is a drug of choice in the tx of agitation in this pt?

- a. Haloperidol
- b. Diazepam
- c. Fluoxetine
- d. Clozapine
- e. Chlorpromazine

Ans. The key is A. Haloperidol. It is a wrong key. Correct key is Diazepam. [Haloperidol has autonomic side effects].

1610. A 32yo woman of 40wks gestation attends the antenatal day unit with sudden onset epigastric pain with nausea and vomiting. She is clinically jaundiced. Her biochemistry results show a raised bilirubin, abnormal liver enzymes, high uric acid and hypoglycemia. What's the most likely dx?

- a. Acute fatty liver of pregnancy
- b. Obstetric cholestasis
- c. Cholecystitis
- d. HELLP syndrome
- e. Acute hepatitis

Ans. The key is A. Acute Fatty Liver of Pregnancy. [When jaundice is present in pregnancy, AFLP should be high on the differential. Pain, nausea, vomiting, jaundice, fever with elevated liver enzymes and bilirubin are indicative of AFLP. Also can have elevated INR, TLC and hypoglycaemia.

1611. A 24yo man believes his bowels are blocked and his life is in ruin. What kind of delusion is he suffering from?

- a. Persecutory
- b. Factitious
- c. Guilt
- d. Nihilistic
- e. Hypochondriacal

Ans. The key is D. Nihilistic. [The man believes his bowels are blocked and his life is ruined is an example of nihilistic delusion].

1612. A 75yo man with declining vision, cornea and pupils are normal, fundus shows obscured margins. What is the single most likely dx?

- a. Macular degeneration
- b. HTN retinopathy
- c. MS
- d. DM background
- e. Proliferative DM retinopathy

Ans. The key is A. Macular degeneration. [In a 75yrs old man with normal cornea and pupils and papilloedema suggests macular degeneration].

1613. A man under psychiatric tx develops GI distress and tremors. Which drug is most likely to cause these symptoms?

- a. Lithium
- b. Diazepam
- c. Citalopram
- d. Clozapine
- e. Imipramine

Ans. The key is A. Lithium. [Lithium causes tremor, GI distress (vomiting) along with Diabetes insipidus].

1614. A 24yo man presents with painless hematuria. No other complaint and no abnormality is found on physical exam. What is the most appropriate initial inv which is helpful to get a dx?

- a. Coag screening
- b. MSU
- c. Cystoscopy
- d. MRI spine
- e. Abdominal US

Ans. The key is E. Abdominal US. [Painless hematuria in a young male without any other findings on history or examination often suggests

Polycystic Kidney Disease].

1615. A 29yo woman presents to her GP with troublesome heavy periods. The med tx that she has tried have made little difference. She is known to have large uterine intramural fibroids. You confirm that she is currently trying for more children. Select the most appropriate management for menorrhagia in this pt?

- a. Danazol
- b. Endometrial ablation
- c. Hysterectomy
- d. Hysteroscopic resection of fibroids
- e. Myomectomy

Ans. E. Myomectomy. [Chance of subsequent pregnancies is better after myomectomy].

1616. A 30yo schizophrenic female attacks her mother believing that aliens have replaced her with an exact double. What condition is she suffering from?

- a. Capgras syndrome
- b. Ganser syndrome
- c. Todd syndrome
- d. Fregoli syndrome
- e. Cotard syndrome

Ans. Capgras Syndrome. [Capgras syndrome is an irrational belief that a familiar person or place has been replaced by a duplicate.

Ganser syndrome is a fictitious disorder in which a patient deliberately acts as if he has a physical or mental illness when he doesn't have it.

Todd syndrome/Alice In Wonderland syndrome/Lilliputian syndrome is a disorienting neurological condition affecting human perception of size, shape and time.

Fregoli syndrome is a delusion of doubles, a delusional belief that different ppl are in fact a single person in disguise or change appearance.

Cotard's syndrome/Nihilistic delusions is 'walking corpse syndrome', the person think they are dead or that one of their organs has stopped functioning].

1617. A 38yo man has just returned from a holiday where he went swimming everyday. For the last few days he has had irritation in both ears. Now his right ear is hot, red, swollen and acutely painful. What is the single most likely dx?

- a. Foreign body
- b. Impacted earwax
- c. OE
- d. OM
- e. Perforation of eardrum

Ans. C. Otitis Externa. [The swimming history, irritation in both ears and ear being hot, red, swollen and painful indicates inflammation of the external acoustic meatus called Otitis Externa. It isn't otitis media because of the lack of Tympanic membrane signs].

1618. A healthy 2yo boy is brought to the ED having cut his hand playing in the garden. He has a 2cm clean laceration. He has not received any routine immunizations as his parents are concerned about possible side effects. There are no contraindications to immunizations. What is the single most appropriate follow up inv?

- a. Courses of DPT vaccine
- b. Courses of DT
- c. Single inj of DPT vaccine
- d. Single inj of DT
- e. Single inj of tetanus Ig

Ans. A. Courses of DPT Vaccine. [The child is unimmunized and has no contraindication to vaccination. Keeping in mind his age, single injections would be useless and would not help the patient. Courses of DPT vaccine would be the best choice in this case].

1619. A 6wk child has hx of frequent vomiting which became worse during the last weeks. He has no fever, recently he has passed stool only once every 2-3d. What inv will you do to confirm the dx?

- a. Abdominal US
- b. Barium meal
- c. Erect XR abdomen
- d. Feed test
- e. Reassure

Ans. The key is A. Abdominal US. [The age and symptoms points towards pyloric stenosis].

1620. A 30yo woman had an IUCD inserted 8-9m ago. Now on routine follow up the thread is missing. Uterine US showed no IUCD in the uterus. What is the best management?

- a. Laparoscopy
- b. Pelvic CT
- c. Laparotomy
- d. Pelvic XR

Ans. The key is D. Pelvic XR. [Ultrasound should be arranged to locate the device. If ultrasound does not locate the device and there is no definite history of expulsion then abdominal X-ray should be performed to look for an extrauterine device].

1621. A pt comes with weight loss and sleep disturbance has mild depression. He has a hx of MI. What is the single most appropriate tx?

- a. Diazepam
- b. ECT
- c. Imipramine
- d. Lithium
- e. Antipsychotics

Ans. The key is A. Diazepam. [Treatment for mild depression is CBT. As the patient has MI imipramine is not suitable and in mild depression antidepressant is usually not given. As the patient has sleep disturbance diazepam can be given].

1622. A pt. comes back from India and presents with night sweats and lymphadenopathy. XR: Cavitation. What investigation should be done next?

- a. CT scan
- b. AFB stain
- c. Blood culture
- d. Bronchoscopy

Ans. AFB Stain [The symptoms and arrival from an endemic area for Pulmonary TB suggests the best course of action would be to go for AFB staining via ZN stain].

1623. A 45yo woman has been extensively investigated for a lump she believes to be cancer. She doesn't think doctors take her seriously and demands another referral. What term best describes her condition?

- a. Munchausen syndrome
- b. Munchausen's by proxy
- c. Hypochondriasis
- d. Malingering
- e. Phobia

Ans. The key is C. Hypochondriasis. [Worry about having a serious illness. This debilitating condition is the result of an inaccurate perception of the condition of body or mind despite the absence of an actual medical condition].

1624. A 15yo man presents with bitemporal hemianopia and spade-like hands. What is the definite test to confirm the dx?

- a. Early morning growth hormone
- b. Insulin tolerance test
- c. OGTT with growth hormone measurements
- d. Random insulin-like growth factor (IGF-1)
- e. Short ACTH test

Ans. The key is C. OGTT with growth hormone measurements. [The bitemporal hemianopia and spade-like hands point towards acromegaly. The best initial test is insulin like growth factors but the definitive test that confirms the diagnosis is OGTT with serial growth hormone measurements].

1625. A 22yo man has had an acute, painful, red right eye with blurring of vision for one day. He had a similar episode 1y ago and has had episodic back pain and stiffness relieved by exercise and diclofenac for four years. What is the SINGLE most likely cause of his red eye?

- a. Chorioretinitis
- b. Conjunctivitis
- c. Episcleritis
- d. Iritis
- e. Keratitis

Ans. The key is D. Iritis. [The symptoms described are characteristic of ankylosing spondylitis (lower back pain and stiffness which gets better after moving around and taking NSAIDs) the extra articular manifestations of AS is iritis].

1626. A 40yo divorced man with bipolar affective disorder attends hospital following an OD of 30 TCA tablets. His new partner has left him and he has stopped taking his medicine and begun drinking heavily. He appears depressed, feels hopeless and is ambivalent about being alive. He is now fit for discharge from the medical ward and acknowledges the benefits of previous tx. What is the SINGLE most appropriate next management?

- a. Admission to the psychiatry ward
- b. Arrange psychiatric outpatient follow-up
- c. Discharge to the care of the general practitioner
- d. Referral to local alcohol treatment team
- e. Referral to clinical psychologist

Ans. The key is A. Admission to the psychiatry ward. [To save the patient from another overdose].

1627. A healthy baby boy is born at term to a woman who was unwell with confirmed acute hep B during pregnancy. The mother is very concerned that she may have infected the baby with hep B. What SINGLE preventative intervention should be given to the baby?

- a. Full course of hepatitis B vaccine
- b. Hepatitis B immunoglobulin alone
- c. Hepatitis B vaccine and hepatitis B immunoglobulin
- d. Hepatitis B vaccine as single dose
- e. None until hepatitis B status confirmed

Ans. The key is C. Hepatitis B vaccine and hepatitis B immunoglobulin. [Babies born to mothers infected with hepatitis B have a high risk of acquiring infection, which can be prevented by vaccination at birth. All babies with seropositive mothers should have the full primary course of hepatitis B immunisation and should also have HBIG within 24 hours of birth].

1628. A previously well 15yo girl had an acute onset of fever, sweating, bruising and petechiae. A blood count showed: Hgb=63g/L, WBC=1.1mg/L, Neutrophils=0.1, plt=14. No abnormal white cells were seen on the blood film. She was transfused and given IV antibiotics and her condition improved. 3wks later her blood count has returned to a similar picture. What is the SINGLE most likely underlying dx?

- a. ALL
- b. AML
- c. Aplastic anemia
- d. CML
- e. Pernicious anemia

Ans. The key is C. Aplastic Anaemia. [The age of the patient and pancytopenic picture give us a clinical diagnosis of Aplastic anemia.

Normal WBC morphology rules out ALL, AML and pernicious anaemia while the age rules out CML as a diagnosis].

1629. An 83yo woman admitted with a chest infection becomes confused with impaired attention and poor concentration. She is restless and frightened. She is verbally abusive and has perceptual abnormalities. There is no significant prv psychiatric hx. What is the SINGLE most likely dx?

- a. Delirium
- b. Drug induced psychosis
- c. Lewy body dementia
- d. Multi-infarct dementia
- e. Psychotic depression

Ans. The key is A. Delirium. [Delirium or Acute Confusional States happen in the elderly in response to stressors like acute infections and this is most likely brought on by the chest infection that has developed].

1630. A town has a population of 500,000. In a five year period there are 1250 cases of bladder cancer diagnosed at the only hospital. During the same period the occupational health department diagnosed a further 500 cases. What is the annual incidence per million of bladder cancer in this population?

- a. 2100
- b. 1750
- c. 1400
- d. 700
- e. 350

Ans. The key is D. 700.

1631. A 28yo woman who has had a prv pulmonary embolism in pregnancy wishes to discuss contraception. She has menorrhagia but is otherwise well. What is the SINGLE most suitable contraceptive method for this patient?

- a. COCP
- b. Copper IUCD
- c. Levonorgestrel intra-uterine system
- d. Progestogen implant
- e. POP

Ans. The key is C. Levonorgestrel Intra-Uterine System. [The woman has a history of thromboembolic disease, which essentially contraindicates COCP. LNG-IUS (Mirena) is the hormone releasing device that is

most suitable in this patient with thrombophilia and menorrhagia.

1632. An 8yo girl has had left earache for 2d. The earache subsided about 2h ago with the onset of a purulent discharge which relieved the pain. Her temperature is 39.2C. What is the SINGLE most appropriate antibiotic?

- a. Amoxicillin
- b. Ciprofloxacin
- c. Clindamycin
- d. Erythromycin
- e. Flucloxacillin

Ans. The key is A. Amoxicillin. [This is the picture of Acute Otitis Media which has led to tympanic membrane perforation. PO Amoxicillin for 7 days is the antibiotic of choice].

1633. A 38yo man has disturbing thoughts about his house being infected by germs. He is anxious about safety and checks the locks of his doors repeatedly before going to bed. For the last 8wks he has been washing his hands every time he touches the lock, 20-30 times a day. What is the SINGLE most appropriate management?

- a. Antidepressant
- b. Antipsychotic
- c. Anxiolytic
- d. CBT
- e. Psychodynamic psychotherapy

Ans. The key is D. CBT

Reason: This scenario describes a case of OCD for which the best management is CBT followed by SSRIs or TCAs].

1634. A 65yo man had closure of colostomy performed 5d ago. He is not systemically unwell. There is a tender, localised fluctuant swelling 4 cm in diameter in the wound. What is the SINGLE most appropriate management?

- a. Abdominal support
- b. Antibiotics
- c. Laparotomy and re-suture wound
- d. Local exploration of wound
- e. Observation

Ans. The key is D. Local exploration of wound.

1635. A 32yo woman has had a febrile illness and swelling of the small joints of her hands, feet, wrists and knees for two days. She has a maculopapular rash and a few palpable, small cervical lymph nodes. She was previously well. There is no history of relevant travel outside the UK. She has two young children. What is the SINGLE most likely dx?

- a. Psoriasis
- b. Reactive arthritis
- c. Rheumatoid arthritis
- d. Sarcoidosis
- e. SLE

Ans. The key is B. Reactive arthritis. [This is GMC sample question and given key is B. Reactive arthritis].

1636. A 16yo girl has had an enlarging mass in the right side of her neck for the last 6wks. She has had no other symptoms. She has a 2 x 2 cm enlarged LN in the anterior triangle of the neck with several smaller associated LN palpable. Oropharyngeal examination shows tonsillar membranes. What is the SINGLE most likely dx?

- a. Infectious mononucleosis
- b. Leukaemia
- c. Lymphoma
- d. Sarcoidosis
- e. Tuberculosis

Ans. The key is A. Infectious mononucleosis. [Though in infectious mononucleosis lymph nodes are usually seen in posterior triangle but can be seen in whole body including anterior triangle also].

1637. A 60yo man has had increasing pain in both buttocks, thighs and calves on walking for three months. He has also recently developed impotence. Femoral and distal pulses are absent in both limbs. What is the SINGLE most likely site of arterial obstruction?

- a. Aorto iliac
- b. External iliac
- c. Femoropopliteal
- d. Internal iliac
- e. Tibial

Ans. The key is A. Aorto iliac. [saddle embolus; surgical intervention].

Page 718 OHCM 9th edition.

Patient is suffering from Leriche's syndrome.

Classic triad of:

- Pain and claudication of buttock and thighs (pale cold leg)
- Erectile dysfunction from aorto iliac occlusive disease
- Absent femoral and distal pulse.

1638. A 78yo man has collapsed. He has had a severe headache for 12 hours and had an URTI 3d ago. He has a temp=39.2C, pulse=122bpm, BP=84/60mmHg and RR=34bpm but his chest is clear. He has a GCS=10 and some neck stiffness. He has been started on high-flow oxygen. What is the SINGLE most appropriate immediate management?

- a. IV antibiotic; CT brain scan
- b. IV antibiotic; LP
- c. IV fluids; CT brain scan
- d. IV fluids; IV antibiotic
- e. IV fluids; LP

Ans. The key is D. IV Fluids; IV antibiotic [This is GMC sample question. GMC given key is D. IV fluids; IV antibiotic].

1639. A 16yo boy was brought to hospital in a comatose state having taken methadone belonging to his sister. He was given naloxone and rapidly became alert. Some hours later, he gradually becomes semi-conscious again. What is the SINGLE most likely reason for this patient becoming semi-conscious again in hospital?

- a. Methadone hepatotoxicity has caused acute liver failure
- b. Methadone is eliminated from the body more slowly than naloxone
- c. Naloxone is a partial agonist at the central nervous system opioid receptor
- d. The pt has misused another substance that has caused an intracranial bleed
- e. The pt has misused another substance that is absorbed more slowly than methadone

Ans. The key is B. Methadone is eliminated from the body more slowly than naloxone (short t_{1/2})

1640. A 27yo woman who takes the COCP has had painless vaginal spotting and discharge for 3 days. Her last menstrual period, which lasted four days, finished 10 days ago. Her last cervical smear two years ago was normal. Abdominal and vaginal examinations are normal apart from a mild ectropion with contact bleeding. What is the SINGLE most appropriate initial inv?

- a. Cervical smear
- b. Colposcopy
- c. Endocervical swab
- d. Endometrial biopsy
- e. Pelvic US

Ans. The key is C. Endocervical swab. [As her cervical smear and examination of abdomen and vagina are normal, next would be to exclude a STD for which Endocervical swab is taken].

1641. A 72yo man being investigated for anaemia is booked for a colonoscopy in 24 hours. What is the SINGLE most appropriate management the night before the procedure?

- a. Bisacodyl tablets
- b. Glycerine suppository
- c. Lactulose syrup
- d. Magnesium citrate (orally)
- e. Senna tablets

Ans. The key is D. Magnesium Citrate (Orally)

1642. A 19yo woman has had progressive bilateral iliac fossa pain and dyspareunia for 3days. She has an offensive vaginal discharge and feels unwell and feverish. Her temp=39C. An initial antimicrobial regimen is commenced. What SINGLE set of organisms are the most appropriate for the antimicrobial regimen to cover?

- a. Neisseria gonorrhoeae and Candida albicans
- b. Neisseria gonorrhoeae and Candida albicans and Gardnerellavaginalia
- c. Neisseria gonorrhoeae and Chlamydia trachomatis
- d. Neisseria gonorrhoeae and Chlamydia trachomatis and Candida albicans
- e. Neisseria gonorrhoeae and Chlamydia trachomatis and Gardnerellavaginalis

Ans. The key is C. Neisseria gonorrhoeae and Chlamydia trachomatis [GMC sample question].

1643. A 48yo man with renal cancer had radiotherapy for metastatic spinal cord compression at the 11th thoracic vertebra 4wks ago. He has retained sensation but is unable to stand. He has pain in a band around his lower trunk controlled by regular oral morphine. He is distressed by increasingly frequent episodes of painful muscle spasms in his right leg. What is the SINGLE most appropriate management of his symptoms?

- a. Amitriptyline
- b. Baclofen
- c. Fentanyl patch
- d. Gabapentin
- e. Increase morphine dose

Ans. The key is B: Baclofen. [Muscle relaxant].

1644. A 4yo girl has had a temp=38.5C for 2days and has not wanted to eat her food. Yesterday she developed a sore throat and small, painful ulcers inside her mouth. Today she has small blisters on the palms of her hands and soles of her feet which are painful but not itchy. What is the SINGLE most likely underlying cause?

- a. Coxsackie virus
- b. Herpes simplex virus
- c. Staphylococcus aureus
- d. Streptococcus pneumonia
- e. Varicella zoster virus

Ans. The key is A: coxsackie virus

Patient is suffering from HFMD (Hand, Foot and Mouth Disease)

• HFMD is due to an infection that usually causes a typical illness, including a typical rash. It is most commonly caused by the Coxsackie A16 virus

• HFMD most commonly affects children under 10 years of age

• This might include a high temperature (fever). After this, a sore throat commonly occurs, quickly followed by small spots that develop inside the mouth. These soon progress into small mouth ulcers

• In many cases, spots also develop on the skin. This is typically a day or so after the mouth ulcers develop. The spots are small lumps that are a few millimetres in diameter and usually appear on the hands and feet, they are not usually itchy but sometimes they can be a little bit sore.

Treatment:

• There is no treatment that will take away the virus

1645. A 32yo woman has had 3 episodes of slurred speech and 2 episodes of transient weakness of both legs in the past 5yrs. Each episode has resolved in 3m. What is the SINGLE most likely dx?

- a. Meningioma
- b. Migraine
- c. Multiple sclerosis
- d. Stroke
- e. Transient ischaemic attack

Ans. The key is C. Multiple sclerosis.

1646. An 8yo girl is complying with her asthma treatment of low-dose inhaled corticosteroid prophylaxis and short-acting bronchodilators as required. Her inhaler technique is good. She now has a frequent night cough and mild exercise-induced wheeze. What would be the SINGLE most appropriate change in her treatment?

- a. Add leukotriene antagonist
- b. Add oral theophylline
- c. Add regular long-acting bronchodilator
- d. Increase dose of inhaled corticosteroid
- e. Short course of oral corticosteroid

Ans. The key is D. Increase dose of inhaled corticosteroid. This is a wrong key. Correct key is C. Add regular long-acting bronchodilator.

1647. A 38yo man with longstanding alcohol dependence has vertigo and a tremor every morning. What is the SINGLE most likely dx?

- a. Anxiety
- b. Benign positional vertigo
- c. Cerebellar degeneration
- d. Optic neuritis
- e. Temporal lobe epilepsy

Ans. The key is C. Cerebellar degeneration. [chronic alcohol abuse that leads to temporary or permanent cerebellar damage].

1648. An 84yo woman with Alzheimer's dementia has recently become incontinent and more confused than usual. What is the SINGLE most likely dx?

- a. Detrusor overactivity
- b. Neuropathic bladder
- c. Nocturnal enuresis
- d. UTI
- e. Uterine prolapse

Ans. The key is D. UTI. [In UTI there may be incontinence of urine and confusion].

1649. A 4yo boy complains of pain around his right eye. He is unwell, febrile and also suffers from pain on the right side of his face. What is the most probable dx?

- a. Allergic reaction
- b. Furuncle
- c. Folliculitis
- d. Foreign body
- e. Periorbital cellulitis

Ans. The key is E. Periorbital cellulitis.

1650. A pt presents with irregularly irregular pulse of 162bpm. What drug is most useful initially?

- a. Amiodarone
- b. Digoxin
- c. Bisoprolol
- d. Warfarin
- e. Heparin

Ans. The key is C. Bisoprolol (most likely its acute AF and 1st line is verapamil/bisoprolol, 2nd line digoxin/amiodarone)

1651. A 59yo man has shown a change in his mood and personality over a 9m period. He has subsequently developed difficulty with memory and conc, and then progressive fidgety movements of his limbs and facial musculature. By the time of medical assessment he has frank choreiform movements and a mini-mental state exam of 21/30. Other exam is normal. He was adopted and therefore no information on his famhx is available. He has 3 adult children (27, 30, 33) of whom the 2 youngest are asymptomatic. However, the oldest son has recently been inv by the neurology dept for slightly erratic behavior and fidgety restless movements of both legs. Based on the likely clinical dx, which one of the following genetic patterns is most likely?

- a. AD inheritance with anticipation
- b. AD with variable penetrance
- c. AR
- d. X-linked
- e. Mitochondrial disorder

Ans. The key is A. AD inheritance with anticipation. [Patient is suffering from Huntingtons disease and that is autosomal dominant with

anticipation which means a genetic disorder is passed on to the next generation, the symptoms of the genetic disorder become apparent at an earlier age with each generation].

1652. A 35yo pt has been dx with schizophrenia. He mimics the doctors and attendants – doing the same physical actions as them. What symptom does this pt have?

- a. Echopraxia
- b. Echolalia
- c. Perseveration
- d. Apraxia
- e. Anosognosia

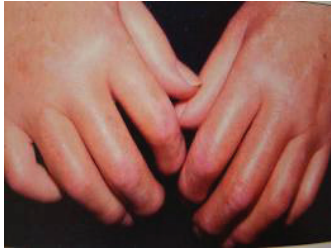Ans. The key is A. Echopraxia. [Echopraxia is the involuntary repetition or imitation of another person's actions. Similar to echolalia, which is the involuntary repetition of sounds and language. Echopraxia has long been recognized as a core feature of Tourette syndrome, and is considered a complex tic, but it also occurs in autism spectrum disorders, schizophrenia and catatonia].

1653. A pt has loss of sensation on the tip of her tongue and the inner aspect of the lip. Which nerve is most likely to be involved?

- a. Vagus nerve
- b. Glossopharyngeal nerve
- c. Lingual nerve
- d. Buccal nerve
- e. Facial nerve

Ans. The key is C. Lingual Nerve.

1654. A 51yo woman complains of difficulty swallowing and also reddish dots on her skin. A pic of her hand is seen. What is the most appropriate term for the condition you would expect to see?



- a. Sclerodactyly
- b. RA
- c. Swan neck deformity
- d. Polydactyly
- e. Ulnar deformity

Ans. The key is A. sclerodactyly. [Patient is suffering from crest syndrome, sclerodactyly is one of the features].

1655. A 37yo female working as a healthcare assistant in a nursing home comes to the ED with complaints of severe itching all over her body. On asking she replies that she had applied cream on the body of a resident in the nursing home who had similar itches. What is the mechanism of itching?

- a. Allergic reaction
- b. Inflammation of keratinocytes
- c. Allergic reaction developed due to use of topical steroid creams
- d. Subcutaneous bleeding
- e. None

Ans. The key is A. allergic reaction.

1656. A 65yo pt who had MI 1yr ago now comes to the ED complaining that his neighbor is conspiring against him. When his son is asked, he denies it and also narrates that sometimes his father says that everybody in his office is always talking about him, which is not the case. What is the most appropriate med?

- a. TCA
- b. Clozapine
- c. Olanzapine
- d. Lorazepam

Ans. The key is C. Olanzapine. [Schizophrenia treated with olanzapine].

1657. You suspect Cushing's disease in a 50yo woman who has attended clinic with glycosuria, HTN and a suggestive body habitus. Initial inv point you towards a dx of Cushing's disease. Which of the following findings would be against this dx?

- a. A normal 8am cortisol
- b. Failure to suppress morning cortisol with dexamethasone
- c. HTN requiring >2 antihypertensive agents
- d. Impaired growth hormone response to glucose loading
- e. Unilateral adrenal enlargement

Ans. The key is E. Unilateral adrenal enlargement.

Cushing's disease

Bilateral adrenal hyperplasia from an ACTH secreting pituitary adenoma.

Peak age 30-50 years, male female ratio 1:1

A low dose dexamethasone test leads to no change in plasma cortisol but 8 mg may be enough

1658. Which finding, on clinical examination of the pulse, suggests a diagnosis of hypertrophic obstructive cardiomyopathy (HOCM)?

- a. Irregularly irregular pulse suggesting A-fib
- b. Pulsus alternans
- c. Pulsus bigeminus
- d. Pulsus bisferiens
- e. Pulsus paradoxus

Ans. The key is D. Pulsus bisferiens. [Pulsus bisferiens, is a sign where, on palpation of the pulse, a double peak per cardiac cycle can be appreciated. Bisferious means striking twice. Classically, it is detected when aortic insufficiency exists in association with aortic stenosis, [1] but may also be found in hypertrophic obstructive cardiomyopathy].

1659. A 60yo male is admitted with a 2d hx of lower abdominal pain and marked vomiting. On examination he has abdominal swelling, guarding and numerous audible bowel sounds. What is the likely dx?

- a. Gallstone ileus
- b. Ischemic colitis
- c. Large bowel obstruction
- d. Sigmoid volvulus
- e. Small bowel obstruction

Key is D: sigmoid volvulus [History is not suggestive of ischemic colitis. There are no bowel sounds heard in gallstone ileus. Small bowel obstruction causes central abdominal pain, So given features with lower abdominal pain makes it more likely to be sigmoid volvulus].

1660. A 17-year-old boy is diagnosed with scabies. Which of the following statements regarding scabies is correct?

- a. Is best treated by salicylate emulsion
- b. It can be spread by a droplet infection
- c. It causes itchiness in the skin even where there is no obvious lesion to be seen
- d. It is caused by Staphylococcus aureus
- e. Typically affects the face

Ans. The key is C. It causes itchiness in the skin even where there is no obvious lesion to be seen.

1661. An anemic young man is found to have a macrocytosis of 90%. The most likely cause is?

- a. Zieve's syndrome
- b. Thalassemia minor
- c. Chronic renal disease
- d. IDA
- e. Folate def
- f. Chronic liver disease
- g. HUS
- h. Cytotoxic chemotherapy
- i. Phenytoin

Ans. The key is E. Folate deficiency.

[Zieve's syndrome is an acute metabolic condition that can occur during withdrawal from prolonged alcohol abuse. It is defined by hemolytic anemia (with spur cells and acanthocytes), hyperlipoproteinaemia (excessive blood lipoprotein), jaundice, and abdominal pain. The underlying cause is liver delipidization].

1662. An association with HPV is a most characteristic feature of?

- a. Torus
- b. Exostosis
- c. Pleomorphic adenoma
- d. Verruca vulgaris
- e. Fibroma
- f. Epulis fissuratum
- g. Mucocele
- h. Pyogenic granuloma
- i. Parulis
- j. Ranula

Ans. The key is D. Verruca vulgaris. [It is most commonly associated with warts or verruca vulgaris].

1663. For the following type of surgery what is the most likely agent that may cause post-operative infection -- aorto-iliofemoral reconstruction with a Dacron vascular prosthesis?

- a. Proteus
- b. E.coli
- c. Bacteroides fragilis
- d. Staphylococcus aureus
- e. Staphylococcus epidermis
- f. C.perfringens
- g. Pseudomonas aeruginosa
- h. Streptococcus fecalis
- i. Streptococcus pneumonia
- j. Brucella melitensis

Ans. The key is E. Staphylococcus epidermidis. [Staphylococcus epidermidis is most common cause of infections in prosthesis].

1664. A primigravida in the 17th week of her symptomless gestation is found, on US, to have evidence of placental tissue covering the cervical os. By the end of her pregnancy she is likely to develop?

- a. Placental migration
- b. Uterine myoma
- c. Uterine rupture
- d. Choriocarcinoma
- e. Chorangioma
- f. Vasa previa
- g. Subplacental abruption placenta
- h. Subchorionic abruption placenta
- i. Placenta accrete
- j. Placenta previa

Ans. The key is A. Placental migration. [In 90% of pregnancies, an initial low lying placenta will be pulled upwards by the growing uterus and assume a normal position in the upper segment. This phenomenon is referred to as Migration].

1665. An elderly lady with COPD has chronic SOB. She is listed for cataract extraction. What is the anaesthetic of choice?

- a. Facial nerve block
- b. Bupivacaine infiltration of the peri-orbital skin
- c. IV midazolam
- d. Peribulbar acupuncture
- e. Peribulbar lignocaine infiltration
- f. Topical xylocaine
- g. IV alfentanil
- h. Epidural anesthesia
- i. General anesthesia

j. Retrobulbar xylocaine Inj

Ans. The key is E. Peribulbar lignocaine. [The most used mode of anaesthesia in ophthalmic feild is peribulbar lignocaine].

1666. A 55yo chronic alcoholic with known hepatic cirrhosis has been on a heavy bout of alcohol the night before and was brought home by friends after falling several times in the pub. While being taken up the stairs to his bedroom he falls down the flight of 5 steps but sustains no obvious injury. His wife calls the ED the next day because she could not rouse him in the morning. He is brought in in a comatose state and both pupils appear dilated. Skull vault XR appears normal.

- a. Hepatic encephalopathy
- b. Intracerebral hematoma
- c. Brain stem injury
- d. Extradural hematoma
- e. Chronic subdural hemorrhage
- f. Despressed skull fx
- g. Vertebrobasilar ischemia
- h. Acute subdural hematoma
- i. SAH
- j. Severe migraine attack

Ans. The key is H. Acute subdural hematoma. [Acute subdural hematoma, typical history of alcoholics, falls and usually debilliated or elderly, hepatic cirrhosis increases coagulopathy and chances for bleed].

1667. A 58yo man complains of nose disfigurement. He has a hx of facial erythema particularly of the cheeks and nose. Papules and pustules have been erupting at intervals over the last 10yrs. He admits to a moderate regular consumption of alcohol. Exam: noted to have rhinophyma. The most likely dx is?

- a. Eczema
- b. Herpes simplex
- c. Epidermolysis bullosa
- d. Dermatomyositis
- e. Tinea versicolor
- f. Pemphigus vulgaris
- g. Acne rosacea
- h. Malignant melanoma
- i. Psoriasis
- j. Atopic dermatitis

Ans. The key is G. Acne Rosacea. [Acne Rosacea is characterised by recurrent episodes of facial flushing with persistent erythema, telangiectasia, papules and pustules.It is a chronic acneform disorder of the facial pilosebaceous glands with an increased reactivity of capillaries

to heat, causing flushing and eventually telangiectasia.Rhinophyma is an enlarged nose associated with rosacea which occurs almost exclusively in men].

1668. A 60yo man who presented with metastatic adenocarcinoma of unknown source. He developed rapidly progressive weakness of his arms and was found to have a deposit of tumour in his cervical spine. This was emergently treated with radiation. He developed considerable nausea and vomiting during his therapy and at the end of the course began to have bloody vomiting. Following resuscitation with 6 units of blood, what is the next test of choice?

- a. Apt test
- b. Neck, chest, abdominal XR
- c. 24h esophageal pH probe test
- d. CT abdomen
- e. US abdomen
- f. MRI abdomen
- g. Barium swallow
- h. Angiography
- i. Nuclear scan
- j. Endoscopy

Ans. The key is J. Endoscopy. [Whenever there hemetemesis endoscopy should be carried out immediately if the patients condition allows or it should be delayed till resucitation ,Underlying cause for hemetemesis needs to be sorted out.(High dose radiation is a cause Ulceration and any active bleeders must be treated)].

1669. A pt has fine nail pitting, small yellow-brown areas of discoloration in the nailbed involving the nails on both hands. These findings are commonly associated with?

- a. Yellow nail syndrome
- b. Leukonychia
- c. Onychomycosis
- d. Lichen planus
- e. Pellagra
- f. Thallium toxicity
- g. Contact dermatitis
- h. Zinc deficiency
- i. Hypoalbuminemia
- j. Psoriasis

Ans. The key is J. Psoriasis. [Characteristic nail changes include pitting, discolouration, subungual hyperkeratosis, crumbling of the nail plate, and onycholysis].

1670. A young man develops nonfluent, effortful speech with dysarthria. He is able to understand speech. He fails to repeat the sentence. What would you do next?

- a. XR skull
- b. Non-contrast CT brain
- c. Contrast CT brain
- d. Contrast MRI optic nerves
- e. 4-vessel cerebral angiogram
- f. Single vessel cerebral

- angiogram
- g. Cerebral angiography
- h. MRI frontal lobe
- i. MRI pituitary gland
- j. MRI temporal lobe

Ans. The key is H. MRI Frontal lobe. (Broca's area). [Production (Broca's) dysphasia/aphasia - lesions are located in the left pre-central areas. This is a non-fluent or expressive aphasia since there are deficits in speech production, prosody and syntactic comprehension. Patients will typically exhibit slow and halting speech but with good semantic content. Comprehension is usually good. Unlike Wernicke's aphasia, Broca's patients are aware of their language difficulties. Prosody is the study of the meter of verse. Here it means the rhythm of speech.

Sensory (Wernicke's) dysphasia/aphasia - lesions are located in the left posterior perisylvian region and primary symptoms are general comprehension deficits, word retrieval deficits and semantic paraphasias. Lesions in this area damage the semantic content of language while leaving the language production function intact. The consequence is a fluent or receptive aphasia in which speech is fluent but lacking in content. Patients lack awareness of their speech difficulties. Semantics is the meaning of words. Semantic paraphrasia is the substitution of a semantically related but incorrect word].

1671. A pt being sedated with fentanyl develops severe respiratory depression. This is best reversed using?

- a. Ethanol
- b. Naloxone
- c. Phystigmine
- d. Atropine
- e. Methylene blue
- f. Diphenhydramine
- g. Calcium disodium ethylene

- diamine tetra-acetic acid
- h. Deferoxamine mesylate
- i. Flumazenil
- j. Folic acid

Ans. The key is B. Naloxone. [Opioid Antagonist, reverses the effects of fentanyl, though it has to be administered for a longer period of time due to long half life of fentanyl].

1672. A pt presented with the following blood work,

MCV: Decreased
 Serum ferritin: Decreased
 Total iron binding capacity: Increased
 Serum iron: Decreased
 Marrow iron: Absent.
 What is your dx?

- a. Thalassemia trait
- b. Hypoparathyroidism
- c. Hereditary sideroblastic anemia
- d. Protein energy malnutrition
- e. Chronic renal failure
- f. Anemia of chronic disease
- g. Acute blood loss
- h. IDA
- i. Oral contraceptives
- j. Megaloblastic anemia

Ans. The key is H. Iron deficiency Anemia (IDA). [S/S pallor, koilonychia, angular cheilitis, atrophic glossitis, IN marked Anemia (Cardiac enlargement, Flow Murmurs, ankle oedema and heart failure)]

Inv: FBC : shows microcytic hypochromic anemia, Serum ferritin Level reduced, normal 12-15 mcg/L, (serum ferritin is falsely raised during infections), Anisocytosis and poikilocytosis. Total iron binding capacity is increased.

Treatment: Iron supplementation with B12 and folic acid].

1673. A 20yo previously healthy woman presents with general malaise, severe cough and breathlessness which has not improved with a seven day course of amoxicillin. There is nothing significant to find on examination. The x-ray shows patchy shadowing throughout the lung fields. The blood film shows clumping of red cells with suggestion of cold agglutinins.

- a. Mycobacterium avium complex
- b. Coxiella burnetii
- c. Escherichia coli (Gram -ve)
- d. Haemophilus influenza
- e. Legionella pneumophila
- f. Strep pneumococcus
- g. TB
- h. Mycoplasma pneumonia
- i. PCP
- j. Staph aureus

Ans. The key is H. Mycoplasma pneumonia. [Inability to respond to a seven day course of amoxicillin suggests atypical pneumonia, patchy shadows throughout lung fields and cold agglutination points towards mycoplasma].

1674. An 18yo male works in a company where lunches are often catered. One day, the water at the company facility is not working, but they manage to have the lunch anyway. 2wks later, he becomes sick. He develops anorexia, nausea, malaise and jaundice. During the course of the next 4wks, 7 people who shared in the lunch become ill with similar symptoms. After a few wks, each of the 7 people completely recovers and they replace their caterer. What is a likely dx?

- a. Pancreatic ca
- b. Hemochromatosis
- c. Laennec's cirrhosis
- d. Hep A
- e. HCC
- f. Rotor's syndrome
- g. Primary biliary cirrhosis
- h. Gilbert's syndrome
- i. Hep B
- j. Hemolysis

Ans. The key is D. Hepatitis A. [Symptoms of Hepatitis A range from mild nausea to liver failure (very rare). Spread is normally by the faecal-oral route although there are occasional outbreaks through food sources. Hand washing and good hygiene around food and drink prevent spread of infection. Increasing age is a direct determinant of disease severity].

1675. A 35yo 1st time donor suddenly passes out as she is donating blood. Which of the following steps would be least useful in managing this adverse event?

- a. Ensure donor is adequately hydrated and has not skipped a meal
- b. Elevating the donor's legs as this is usually due to a vasovagal syncope
- c. Haemoglobin of the donor meets the minimum requirement for donation
- d. The donation is usually continued along with simultaneous normal saline infusion.
- e. The donor should be encouraged to mobilise after they have recovered

Ans. The key is C. Haemoglobin of the donor meets the minimum requirement for donation. [If syncope then we can continue donation giving simultaneous normal saline to the donor.(option D). Option C. Haemoglobin of the donor meets the minimum requirement for donation [as it is routinely done in every donor prior to donation and therefore this has no impact on syncope!!].

1676. An infant is being examined as part of a routine examination. The child can hold its head up and lifts its chest off a table. He has a palmer and rooting reflex as well as a social smile. He is not afraid of strangers. What is the most likely age of this child?

- a. neonate
- b. 2 months
- c. 6 months
- d. one year
- e. one and a half years
- f. two years
- g. four years
- h. seven years
- i. ten years
- j. fourteen year

Ans. The key is C. 6 months.

1677. A mother is concerned because her 1m boy has a swelling in his scrotum. He was born prematurely. On examination the swelling is seen to transilluminate. The likely cause is?

- a. Lymphogranuloma Venereum
- b. Testicular Torsion
- c. Hydrocele
- d. Epididymitis
- e. Seminoma
- f. Mature teratoma
- g. Varicocele
- h. Lymphoma
- i. Orchitis
- j. Spermatocele

Ans. The key is C. Hydrocele. [Transilluminating scrotal swelling is likely a case of hydrocele. 1-2% neonates present with congenital hydrocele which disappears by 1-2 years].

1678. A 2m girl has an ante-natal diagnosis of right hydronephrosis. Postnatal serial US exams revealed increasing dilatation of the right pelvicalyceal system. No reflux was demonstrated on a MUCC. Appropriate management should include?

- a. Surgical repair
- b. Intermittent catheterization
- c. Diuresis renography
- d. Anticholinergic agents
- e. Phenylpropanolamine
- f. Gellhorn pessary
- g. Biofeedback-assisted behavioral treatment
- h. Oral Estrogen therapy
- i. Vaginal Estrogen therapy
- j. Ring pessary

Ans. The key is C. Diuresis renography.

1679. Jean is a 72yo woman with recurrent bowel cancer following a hemi-colectomy 2y ago. She is known to have both local recurrence and liver mets and her pain has been under control on MST 90mg bd. She has had quite severe pain in the RUQ for the past hour despite having taken her normal dose of MST. You find that she has an enlarged liver which is hard and irregular. There is marked localised tenderness over the right lobe of her liver. Her abdomen is otherwise soft and non-tender and the bowel sounds are normal. She is apyrexial. The tx of choice would be?

- a. Oral NSAIDs
- b. TENS
- c. radio therapy to the liver
- d. IM diamorphine
- e. Paracetamol
- f. Prednisolone
- g. Physiotherapy
- h. epidural anaesthetic
- i. Pitocin
- j. Aspirin

Ans. The key is D. IM diamorphine.

1680. Titubation is a feature of disease involving the?

- a. Cerebellum
- b. Basal ganglia
- c. Corpus callosum
- d. Pons
- e. Temporal lobe
- f. Occipital lobe
- g. Optic chiasma
- h. 3rd ventricle
- i. Hypothalamus
- j. Pituitary gland

Ans. The key is A. Cerebellum [Titubations (head/body nodding) mostly occur due to cerebellar lesions].

1681. A 50yo farmer complains of pain in his left arm. Exam: he appears to have a neuropathy affecting isolated nerves in multiple, random areas of his left arm. He also has a palpable purpura and tender nodules on both of his upper and lower limbs. A likely diagnosis is?

- a. Carpal tunnel syndrome
- b. Polyarteritis nodosa
- c. Angina Pectoris
- d. Gout
- e. Cellulitis
- f. Rheumatoid arthritis
- g. Erysipelas
- h. Fascitis
- i. Reiter's Syndrome
- j. Polymyalgia Rheumatica

Ans. B. Polyarteritis nodosa. [Presentation: Peripheral nerves and skin are the most frequently affected tissues. PURPURA, LIVEDOID, SUBCUTANEOUS NODULES and NECROTIC ULCERS. Neurologically, MONONEURITIS MULTIPLEX>...involvement of CNS, GIT, kidneys and heart means higher mortality. RENAL INVOLVEMENT: hypertension, Renal failure, GIT: necrosis, perforation. Myalgia].

1682. A patient with chronic neutropenia develops a chronic cough. A CXR reveals a cavitating intrapulmonary lesion containing a movable rounded ball lesion. A likely dx is?

- a. Tuberculosis
- b. Bronchiectasis
- c. Cystic fibrosis
- d. Pulmonary hemosiderosis
- e. Mitral stenosis
- f. Aspergillosis
- g. Wegener's granulomatosis
- h. Goodpasture's syndrome
- i. Pulmonary embolism
- j. Non-SCLC

Ans. The key is F. Aspergillosis. [Mostly affects people with reduced immunity, reduced neutrophil count is also predilection for aspergillosis].

1683. A mother brings her 1yo infant to her pediatrician. She describes that following a common cold her child's voice has become hoarse and has developed a cough that sounds harsh and brassy and was worse at night. Exam: the child was noted to have trouble drawing air into its lungs between coughs and had trouble drawing air into its lungs. There was visible stridor on inhalation. The cause is most likely to be?

- a. EBV
- b. Rhinovirus
- c. Parainfluenza
- d. Flavivirus
- e. HIV
- f. Rotavirus
- g. CMV
- h. Kemerovo
- i. Creutzfeld-Jacob
- j. Rubella

Ans: Parainfluenza. [Parainfluenza virus causes croup. A rough barking cough with hoarseness and wheezing, labored breathing, runny nose, fever, cough, decreased appetite are common features].

Investigation: Viral culture of secretions.

Treatment: Symptomatic supportive treatment

Antibiotics in case of secondary infection.

1684. INR: Normal, APTT: Elevated, Thrombin time: Elevated, Plt count: Normal, Bleeding time: Normal. A likely aetiology is?

- a. Waldenström's macroglobulinaemia
- b. Heparin
- c. Sézary cell leukaemia
- d. Pelger-Huet anomaly
- e. von Willebrand's disease
- f. Haemophilia
- g. HIV infection
- h. DIC
- i. Acanthocytosis
- j. Vit K deficiency

Ans: Heparin

1685. An infant has diarrhea for 3d with weight loss from 10 kg to 9 kg. Exam: he is noted to have dry mucous membranes, poor skin turgor, markedly decreased urine output, and tachycardia. His BP=normal and compression-release of the nail beds shows satisfactory refilling. Appropriate treatment would include?

- a. Plasmapheresis and plasma infusion
- b. 0.5% Normal Saline
- c. Lactated Ringer's injection
- d. Packed cells
- e. Whole blood
- f. Platelets
- g. FFP
- h. double strength Normal Saline
- i. 5% dextrose in 0.5N saline solution
- j. IV heparin

Ans. The key is C. Lactated Ringer's injection.

1686. A 4yo boy has the sudden onset of bone pain. He begins experiencing bleeding of his gums and frequent bloody noses. His mother takes him to his pediatrician. Exam: he is pale and has numerous petechiae over his body, with lymphadenopathy and hepatosplenomegaly. He has WBC=100,000/mm and numerous circulating blast cells. He is admitted to the hospital. A bone marrow biopsy=35% blast cells. Which of the following is most likely?

- a. Mantle cell lymphoma
- b. Infectious lymphocytosis
- c. Waldenström's macroglobulinemia
- d. CML
- e. CLL
- f. Burkitt lymphoma
- g. ALL
- h. Mycosis fungoides
- i. Hairy cell leukemia
- j. AML

Ans. The key is ALL. This is wrong key! Correct key is AML. [s/s are suggestive of AML short Hx, wbc 100000, petechiae, with lymphadenopathy, very high blast cell count, nose bleeds and hepatosplenomegaly. Clinically it is very difficult to differentiate between CML and ALL. Lymphocytic means it develops from early (immature) forms of lymphocytes, a type of white blood cell. This is different from acute myeloid leukemia (AML), which develops in other blood cell types found in the bone marrow].

1687. A 63yo male has anal canal carcinoma with no evidence of spread to the pelvic wall, pelvic muscles or lymph nodes. This is typically managed by?

- a. Resection of the sigmoid colon
- b. Right hemicolectomy
- c. Left hemicolectomy
- d. Transverse colectomy
- e. Internal sphincterotomy
- f. CT guided drainage
- g. Diverticulectomy
- h. Transverse colostomy
- i. Chemotherapy and radiotherapy
- j. Abdominal perineal resection

Ans. The key is I. Chemotherapy and radiotherapy. [This is T1 N0 MO that is stage 1 cancer. (http://www.cancer.gov/types/anal/hp/anal-treatment-pdq#section/_45).

BUT we don't have tumor size here and sphincter information. However surgery can be avoided To preserve sphincter. Chemo radiation is preferred ohcm 633; 9th ed].

1688. A 2m baby develops a life-threatening anemia. Blood tests show a normal serum iron, ferritin and TIBC. Hemoglobin electrophoresis reveals a markedly decreased Hemoglobin A content and an increased hemoglobin F content. This baby's anemia is likely to be secondary to?

- a. Failure of alpha chain production
- b. Failure of beta chain production
- c. Deficiency d. Lead poisoning of B12
- e. IDA
- f. Presence of hemoglobin S
- g. Presence of hemoglobin M
- h. Deficiency of folate
- i. Bone marrow failure
- j. Inability to manufacture heme

Ans. The key is B. Failure of beta chain production.

1689. A 30yo caucasian man presented with a 2wk hx of gradually worsening vision in his left eye. The patient had been seen once by a neurologist 2yrs prv for flashes. At that time a head CT was normal. The patient was lost to follow up with the neurologist, but the flashes had continued for the 2yr period. The patient did not experience visual changes with activity or movement. The patient reported continued decreasing vision. Goldmann visual fields were done and showed a central scotoma. A MRI was done at this time and showed inflammation of the left optic nerve. A likely diagnosis is?

- a. Pseudotumor
- b. Orbital teratoma
- c. Optic neuritis
- d. Sarcoidosis
- e. Optic glioma
- f. Lymphangioma
- g. Rhabdomyosarcoma
- h. Retinal vascular shunts
- i. Retinoblastoma
- j. Mucormycosis

Ans. The key is C. Optic neuritis [Possible diagnosis is MS. Scotoma, 2yr Hx, age race are suggestive except more in females than males].

1690. A pregnant woman in an early stage of labour expresses the wish to have pain relief during labour. The anesthetist describes that if the patient wishes he can use medication as a local anesthetic to block the pain sensations of labour. Into which space should the local anaesthetic be normally injected?

- a. Anterior pararenal space
- b. Aryepiglottic space
- c. Vestibule space
- d. Epidural space
- e. Sub-arachnoid space
- f. Space of Disse
- g. Middle ear
- h. Posterior pararenal space
- i. Supraglottic space j. Lesser sac

Ans. The key is D. Epidural space.

1691. A 29yo Afro-Caribbean man presents with a non-productive cough mild aches in the ankles. The symptoms have been present for 2m. His ESR is elevated. Ca: 2.69 mmol/l; PO4 -: 1.20 mmol/l; ALP: 80 iu/L. Serum 25(OH) D: 180 nmol/l

Normal values for Calcium: 2.12-2.65mmol/l; Phosphate: 0.8-1.45mmol/l; ALP 30-300iu/L; Serum 25(OH) D: 20-105nmol/l; Urea: 2.5-6.7mmol/l; Creatinine: 70-120µmol/l

- a. Osteoporosis
- b. Thiazide diuretics
- c. Skeletal metastases
- d. Primary hyperparathyroidism
- e. Hypoparathyroidism
- f. Osteomalacia
- g. Multiple myeloma
- h. Paget's disease of bone
- i. Sarcoidosis
- j. Hyperthyroidism

Ans. The key is I. Sarcoidosis.

1692. A 22yo has had recent chickenpox. He now presents with confusion. He is noted to have low urine output and large petechiae all over his body. CXR: a large patch of consolidation is seen. The management of choice should be :

- a. Ventilatory support
- b. Open surgical debridement
- c. Resection of superficial

petechiae with wide margin

- d. Booster vaccine
- e. TENS
- f. Lontophoresis
- g. Nephrostomy
- h. Oral Corticosteroids
- i. Brivudin
- j. IV acyclovir

Ans. The key is J. IV acyclovir.

1693. A young girl with a psychiatric hx on med tx is brought to the dermatologist by her mother because of recurrent patchy hair loss. Exam: the hair shafts revealed twisting and fractures. This suggests the following pathology:

- a. Infection with *Trichophyton tonsurans*
- b. Infection with *Microsporum canis*
- c. Alopecia areata
- d. Telogen Effluvium
- e. Androgenetic Alopecia
- f. Lichen planus
- g. Traction Alopecia
- h. Alopecia totalis
- i. Trichorrhexis nodosa
- j. Trichotillomania

Ans. The key is J. Trichotillomania.

1694. Syphilis typically causes

- a. Lymphogranuloma Venereum
- b. Testicular Torsion
- c. Hydrocele
- d. Epididymitis
- e. Seminoma
- f. Mature teratoma
- g. Varicocele
- h. Lymphoma
- i. Orchitis
- j. Spermatocoele

Ans. The key is I. Orchitis.

1695. A middle aged woman has severe collapse of the right femoral head requiring replacement. The removed femoral head is sent for pathology and is found to contain enlarged fat cells. The pathologist explains that this is the likely cause of the patient's femoral head collapse. A likely aetiology is

- a. Septic emboli
- b. Impaired venous drainage
- c. Hgb SS disease
- d. Steroid use
- e. Alcoholism
- f. Gaucher's disease
- g. missed fracture
- h. Cushing's disease
- i. Radiation
- j. Vasculitis

Ans. The key is F. Gaucher's disease. [Couldn't get much reliable info about this question!]

1696. A 7yo boy with frequent episodic asthma is on tx with sodium cromoglycate. His physician wants to add a non-steroid preventer. The mother of the boy, a teacher, has just read about a nonsteroidal medication which acts on the mast cells, stopping them from releasing harmful chemicals. Her physician agrees to add this medication to the boy's drug regimen. Which medication is the physician most likely to add to the boy's treatment?

- a. Inhaled short acting bronchodilator
- b. SC adrenaline
- c. Nedocromil Sodium
- d. Inhaled long acting bronchodilator
- e. Inhaled sodium cromoglycate
- f. Inhaled steroids
- g. Inhaled SABA
- h. Oral steroids
- i. Nebulised bronchodilators
- j. Oral theophylline

Ans. The key is C. Nedocromil Sodium.

1697. A 3yo boy is playing with his brother when he falls. He cries immediately and refuses to walk. His mother carries him to hospital. He had a full term NVD with no neonatal complications. His immunisations are up to date. Exam: looks well and well-nourished, no dysmorphic features. He has slight swelling, warmth and discomfort on the lower 1/3 of the left tibia, and refuses to weight bear. AP and lateral x rays of the tibia are normal. What is the most likely dx?

- a. Ankle fx
- b. Ankle sprain
- c. Fibular fx
- d. Knee dislocation
- e. Tibial fx

Ans. The key is E. Tibial fx.

[Toddler's fracture

• Undisplaced spiral fractures of the tibial shaft in children under 7 years old often follow minimal trauma and may not be visible on initial X-ray.

• Can be difficult to diagnose but should be suspected whenever a child presents with a limp or fails to bear weight on the leg.

• Treatment consists of immobilisation for a few weeks to protect the limb and to relieve pain.

• Subperiosteal bone formation is usually apparent on X-rays by two weeks].

1698. Which one of the following electrocardiographic changes is found in hypercalcaemia?

- a. Increased QRS interval
- b. Prolonged Q-T interval
- c. Short P-R interval
- d. Short Q-T interval

Ans. The key is D. Short Q-T interval. [Short Q-T interval secondary to a shortened ST segment].

1699. An elderly male pt with prior hx of hematemesis is having hx of long term use of aspirin and other drugs, now presents with severe epigastric pain, dysphagia and vomiting. He was connected to vital monitors which were not reassuring. What is the management?

- a. Oral antacids
- b. IV PPI
- c. Oral PPI
- d. Endoscopy
- e. Analgesia

Ans. The key is D. Endoscopy. [Long term use of an nsaid predisposes to peptic ulcers. There may cause considerable bleeding leading to shock].

1700. A 68yo man presents with bruising and hx of falls. He is found to have a mask-like face, pillrolling tremor and shuffling gait. EEG=normal. Which of the following conditions is he most likely being treated for?

- a. HTN
- b. DM
- c. Psychosis
- d. TIA
- e. Complex partial seizure

Ans. The key is C. Psychosis. [Antipsychotics can lead to parkinsonism].

1701. A 45yo woman presents with easy fatigability, even on no exertion, chronic headaches and body aches and severe physical and mental exhaustion. She has no underlying conditions and all inv are non-conclusive. What is the most likely dx?

- a. Somatization
- b. Chronic fatigue syndrome
- c. Polymyalgia rheumatic
- d. GCA
- e. Depression

Ans. The key is B. Chronic fatigue syndrome. [Chronic fatigue syndrome (CFS) causes persistent fatigue (exhaustion) that affects everyday life and doesn't go away with sleep or rest].

1702. A 23yo male presents to his GP 2wks after a RTA concerned about increasing anxiety lethargy and headache. At the time he had a CT brain after banging his head on the steering wheel, which revealed no abnormality. 6m following this episode his symptoms have resolved. What did his original symptoms likely represent?

- a. Conversion disorder
- b. PTSD
- c. Somatization disorder
- d. GAD
- e. Post-concussion syndrome

Ans. The key is E. Post concussion syndrome. [Post concussion syndrome is a set of symptoms that may continue for weeks, months, or a year or more after a concussion – a minor form of traumatic brain injury].

1703. A 34yo man had a 4mm ureteric stone which he passed in urine. This time he presents withh 3cm stone in the right kidney. Single most appropriate treatment?

- a. No treatment
- b. ESWL
- c. Laparotomy
- d. Observe
- e. Operative stone removal

Ans. The key is E. Operative stone removal.

[Stones < 5mm: pass spontaneously, Inc fluid intake

Stones 5mm-1cm /pain not resolving: medical expulsive therapy---> Nifedipine or Tamsulosin(and/or prednisolone)

Stones 1cm-2cm: ESWL or Ureteroscopy using dormia basket

Stones > 2cm/large/multiple/complex: Percutaneous nephrolithoto-

my].

1704. An 18m girl who has had single UTI is seen in the OPD. She has fever and vomiting but these improved with course of trimethoprim. Subsequently, MCUG showed bilateral vesicoureteric reflux. Single most appropriate mgmt?

- a. Prophylactic antibiotics
- b. Reassure
- c. No treatment
- d. Ureteric surgery

Ans. The key is D. Ureteric surgery. This is wrong key. Correct key is prophylactic antibiotics. [Usually most of the cases of VUR (even though bilateral) cures with advancing age with antibiotic prophylaxis and only a minority need surgery. But for bilateral disease success rate with prophylactic antibiotic is much less than unilateral disease].

1705. A 22yo says she has taken about 40 tabs of paracetamol 3h ago. Her HR=110bpm, BP=110/80mmHg and RR=22bpm. What's the initial management?

- a. Activated charcoal
- b. N-acetyl cysteine
- c. Gastric lavage
- d. Wait for 4h paracetamol level

Ans. The key is D. Wait for 4h paracetamol level.

1706. A 35yo man skidded on a wet road while riding his motorbike at a speed of 70mph. He has a large hematoma on temporal scalp, some bruises on chest wall and abdomen and a deformed thigh. GCS 11/15. High flow oxygen via mask given. Most immediate radiological inv required during initial resuscitation phase?

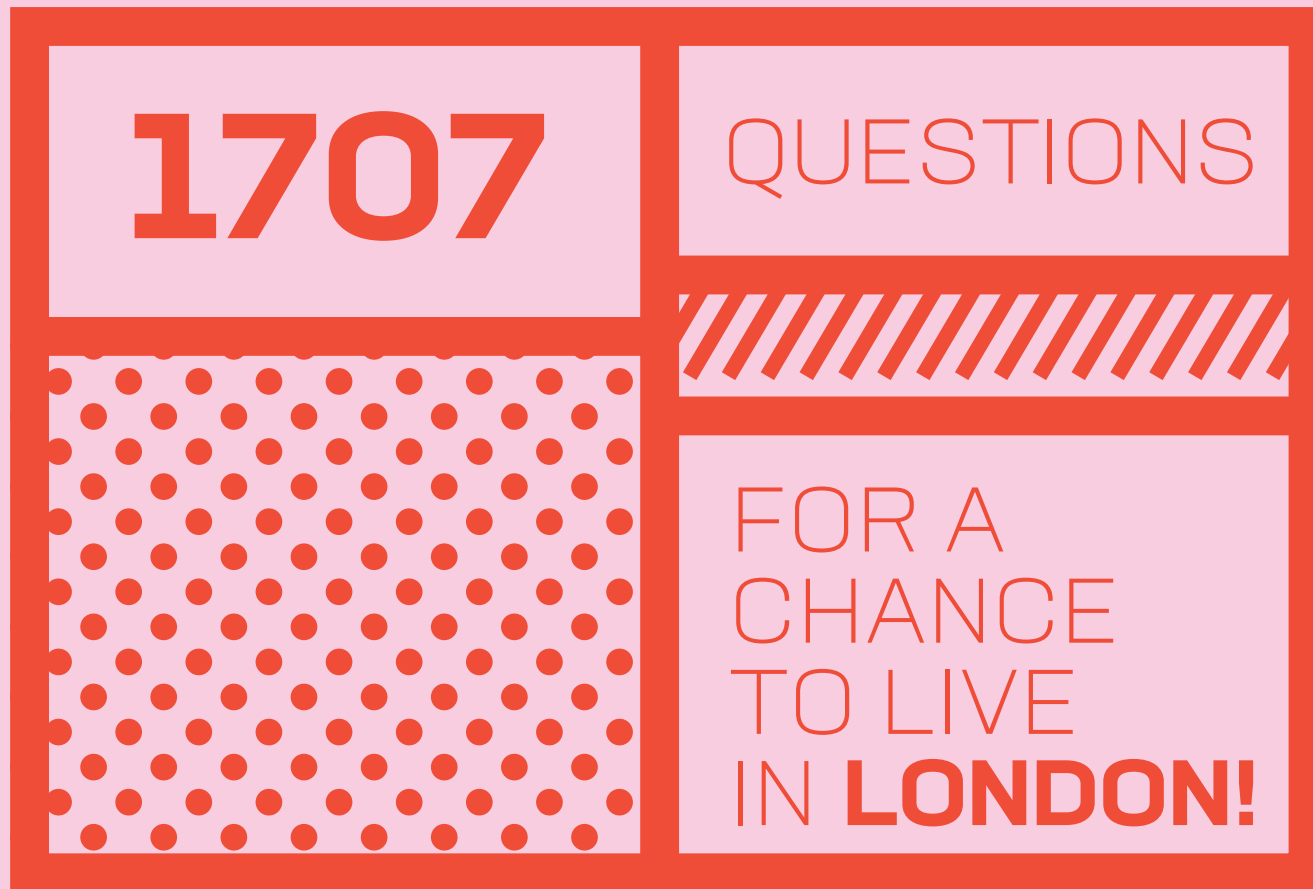- a. CXR
- b. CT brain
- c. CT abdomen
- d. XR femur

Ans. The key is A. CXR. [CXR may reveal possible chest structure trauma requiring urgent attention which may be life saving while brain lesion need time consuming CT and tx and fracture femur may be managed taking more time].

1707. A 4yo baby has a generalized tonic-clonic convulsions and fever of 39C. His mother informs you that this has happened 3-4 times ebfore. What is the most probable dx?

- a. Febrile convulsion
- b. Absence seizures
- c. Epilepsy
- d. Partial complex seizure

Ans. The key is A. Febrile convulsion.



BEST WISHES

Redesigned by Cagdas Ilke Unal
Behance

2018

The original document was 500 pages long. This document is 185 pages long.
Print less, protect more.