201. An occlusal approaching clasp TIP:

A. Should occupy a predetermined undercut.
B. Contact the tooth under the survey line.
C. Rigid.

Answer: A.

202. Regarding the tip of the retention arm of the retainer in a partial denture, what is true?

A. It should engage the predetermined undercut.
B. It should engage the maximum undercut available.
C. It should not engage any undercuts.

Answer: A.

203. In the construction of partial denture the surveyor is not used to:

A. Contour the wax as part of the fabrication of the working cast.
B. Locate the guide planes.
C. Determine the location of indirect retainers.
D. Identify any undesirable undercuts.

Answer: C.

204. The advantage of the silicone in soft relining material over ..... rubber is:

A. Retains high flow.
B. Prevents the colonization of Candida Albicans.
C. Resilient in long run.
D. Better bond strength.

Answer: C.

205. As a result of wrong use of tooth brush the patient MOST probable complaint will be when:

A. Spontaneous pain or discomfort.
B. Occasional pain during brushing of the teeth.
C. Occasional pain during consumption of sweets.

Answer: C.

206. In regards to dentine strength, which is the right sequence?

A. Affected dentine> Sound dentine> Infected dentine.
B. Sound dentine> Affected dentine> Infected dentine.

Answer: B.

207. Symptoms free patient comes to you after four weeks of an endodontic treatment and you find on radiograph the canal is over filled with what it seems to be a cone of Gutta Percha 1mm beyond the apex with a radiolucent small area. What is your initial management?

A. Start apiectomy through a flap and surgery.

B. Obturate the root canal.

C. Ask for a recall and observe in three month time.

D. Seal the pulp chamber and keep it under observation.

Answer: C.

208. After obturation and on X-ray you notice the obturation materials are 1mm beyond apex. What is your first management?

A. Refill the canal.

B. Pull the GP cone about 1mm out and take a new X-ray.

C. Leave it as it.

Answer: A.

This question is different from previous one. If we notice that GP is overextended on the same visit of obuturation, we have to remove it and do refilling since the sealer still not set and we can remove it easily. In addition it is the dentist responsibility to give the best treatment to the patient. BUT if we notice that GP is overextended on later visit, the best option is to leave it and observe.

Correcting Obturation Problems

Occasionally, voids or length problems will be apparent on the radiograph taken during or after obturation. These should be corrected *now*, before the sealer sets.

For voids, gutta-percha is removed with hot pluggers until the spreader can be reinserted just beyond the void or discrepancy. Then, a fresh mix of sealer is prepared. Lateral compaction is performed as described previously; sealer is added back to the canal by coating each accessory cone.

An advantage of making an obturation verification radiograph before the excess gutta-percha is seared off is that the entire mass can usually be removed by grasping the cones with the fingers. Fitting a new master cone and reobturation is then possible.

If the excess gutta-percha has been seared off, an overfill can sometimes be corrected before the sealer sets by removing all gutta-percha with files or broaches. When extruded beyond the apex, the overfilled gutta-percha is difficult to recover through the canal, particularly after the sealer sets. Extruded sealer can only be retrieved surgically.

Obturating materials extruded beyond the apex are irritants and affect healing, but generally they do not completely prevent resolution unless there is gross overfill of core material. ZnOE-based sealers often absorb from periapical tissues over time.[79] These situations should not be treated surgically unless failure to heal is evident on recall examination.

209. 2.21mg NaF contains:

A. 1mg fluoride.

B. 2 mg fluoride.

C. 0.5 mg fluoride.

Answer: A.

210. The requirement for crown and root length is:

A. 2:3.

B. 1:1.

C. 1:2.

Answer: A.

211. Stiffness of material are measured by:

A. Proportional unit.

B. Modules of elasticity.

C. Stress/ strain.

Answer: B.

212. What is the purpose of making a record of protrusive relation and what function does it serve after it is made?

A. To register the condylar path and to adjust the inclination of the incisal guidance.

B. To aid in determining the freeway space and to adjust the inclination of the incisal guidance.

C. To register the condylar path and to adjust the condylar guides of the articulator so that they are equivalent to the condylar paths of the patient.

D. To aid in establishing the occlusal vertical dimension and to adjust the condylar guides of the articulator so that they are equivalent to the condylar paths of the patient.

E. To aid in establishing balance occlusion and to adjust the condylar guides of articulator so that are equivalent to occlusion of patient.

Answer: C.

213. Four years kid shows at your clinic with open bite as a result of thumb sucking, you notice a delayed speech ability. What would be your first management?

A. Refer to a speech therapist.

B. Apply a removable habit inhibitor denture.

C. Apply a removable habit inhibitor denture and educate the parents about it so the kid will not be taking it off so often.

Answer: A.

No need to do anything at this age, if there is an option for NONE OF THE ABOVE is the best. The patient is 4 years old and can overcome this habit and once the permanent incisors erupt he will manage the difficulty of speech. In case that he cannot stop this habit after permanent teeth eruption, we have to use habit breaker.

214. Two central incisors on a radiograph are showing with what looks like eye drop radiolucency. You decided to start endodontic treatment on these teeth but you tried to open access to the root canal you find clearly closed orifices with what look like secondary dentine. What is your initial management?

A. Leave as it and start a permanent restoration.

B. Start systemic antibiotic.

C. Try to ream and file canals.

Answer: C.

The localization of patent canals and their complete debridement and sealing in full extension is a paramount for successful RCT with obliterated canals. A certain protocols has to follow to avoid of unnecessary cutting of dentin and perforation of the teeth like using very small reamers and file moisted with EDTA and teased slightly into a narrow canals. The results of many studies reinforce the importance of centered and angulated radiographs to evaluate the depth reached by the modified instrument, slow speed burs and ultrasonic tips. Additionally the use of operating microscope and teeth morphology knowledge are also important components of endodontic treatment of obliterated canals.

215. A patient with no positive history came along for scaling. The moment you pick up the scaler you punch your finger, what should you do?

A. Complete the procedure as nothing has happened.

B. Check patient's blood for Hepatitis B antibody HBsAb.

C. Check patient's blood for Hepatitis B antigen HBsAg.

D. Check dentist's blood for Hepatitis B antibody HBsAb and HIV antigen HIVAg.

E. Check dentist's blood for Hepatitis B antigen HBsAg and HIV antibody HIVAb.

F. Dentist should go and take a HBsAb vaccine.

Answer: A.

The patient has no positive history, and the question says the moment you pick up the scaler, so no scaling was done. The scaler tip is still sterilized and has punched into your finger.

But if they do not mentioned "THE MOMENT YOU PICK UP THE SCALER" and there is patient's blood on the tip, D will be the correct answer because sometimes patient aren't aware of their diseases. The usual regime as mentioned in the picture.

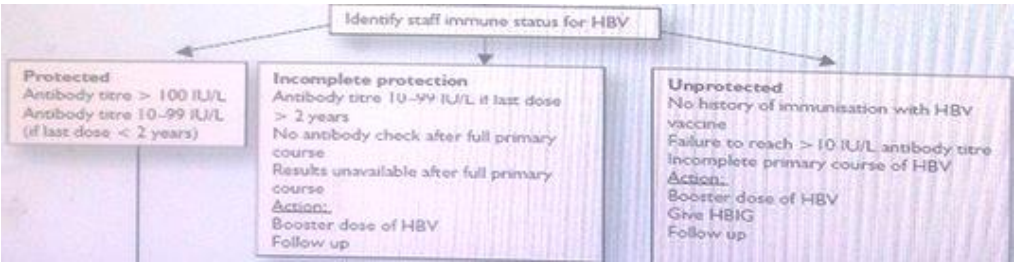

216. When probing a healthy gingival sulcus with a 20g force, the tip of the periodontal probe is most likely located:

A. Coronal to the junctional epithelium.

B. At the level of the junctional epithelium.

C. At the level of the supra crestal fibers.

D. Apical to the junctional epithelium.

Answer: A.

Image 1 of 7
Figure 1 Probing depth of < 3 mm, with the tip of the probe coronal to the junctional epithelium in healthy gingiva..

217. When probing for periodontal disease the tip of the probe will be:

A. At the coronal end of junctional epithelium.

B. At the top of the gingival calculus.

Answer: A.

In this question they have to mention other options as this one seems to be incorrect. The tip of periodontal probe in periodontal disease will be apical to the junctional epithelium.

Image 2 of 7
Figure 2 Probing depth of 6 mm, with the tip of the probe apical to the coronal attachment of the junctional epithelium in inflamed gingival tissue.

218. Which is wrong in regards to (water jet spray) hydrotherapy?

A. Does not harm gingivae.

B. Removes plaque.

C. Removes required pellicle.

Answer: B.

supragingival irrigation with water has only limited effects on plaque scores-that is, supragingival plaque mass or the composition of the subgingival microflora. Water jet irrigation bit can be assumed that through supragingival irrigation, there is a dilution or a removal of bacterial toxins, an interference with plaque maturation, or a possibility that the unattached plaque may be washed away. One may also speculate that the additional bacteremia caused by supragingival irrigation may stimulate the production of specific antibodies directed against periodontal pathogens. Recently, other types of supragingival tips enhanced with soft, tapered bristles have been introduced and shown to be effective in increasing the removal of plaque.

219. After the initial development stage and in the absence of pathology, a the size of the pulp chamber has been reduced by:

A. Deposition of primary dentine.
B. Deposition of secondary dentine.
C. Pulp fibrosis.
D. Deposition of reparative dentine.

Answer: B.

220. The most desirable outcome of endodontic treatment is (Following root canal therapy, the most desirable form of tissue response at the apical foramen is):

A. Healing of the alveolar bone.
B. Deposition of cementum at the apex.
C. Formation of fibrous capsule around the apex (connective tissue capsule formation).
D. Epithelium proliferation from the periodontal ligament.
E. Dentin deposition at the apex.

Answer: B.

221. What is NOT related to the normal aging process?

A. Progressive bone loss.
B. Reduced elasticity of muscles.
C. Decreased elasticity of the skin.
D. Lower pain threshold.

Answer: D.

222. As far as localized alveolar osteitis is concerned; which one of the following is true?

A. The incidence in the mandible and maxilla is similar.
B. The prophylactic prescription of antibiotics prior to extraction reduces the incidence.
C. Excessive fibrinolysis is the likely aetiology.
D. Purulent exudate must be seen for a diagnosis and irrigation is mandatory.
E. ZOE and alvogyl dressing promote a rapid bone growth.

Answer: C.

223. The most accurate finding of pulpal pathology is: (Cawson's Q)

A. Radiolucency on the apical region.
B. Pain on hot or cold drinks.
C. The absence of response to pulp testing.

Answer: A.

224. EARLIEST apical radiographic change seen in a pulpally involved tooth is:

A. Resorption of bone.
B. Loss of lamina dura.
C. External root resorption.
D. Hyper-cementosis.
E. Widening of the periodontal ligament space.

Answer: E.

Radiography

In all endodontic cases, a good intra-oral parallel radiograph of the root and periapical region is mandatory. Radiography is the most reliable of all the diagnostic tests and provides the most valuable information. However, it must be emphasised that a poor quality radiograph not only fails to yield diagnostic information, but also, and more seriously, causes unnecessary radiation of the patient. The use of film holders, recommended by the National Radiographic Guidelines[3] and illustrated in Part 4, has two distinct advantages. Firstly a true image of the tooth, its length and anatomical features, is obtained (Fig. 3), and, secondly, subsequent films taken with the same holder can be more accurately compared, particularly at subsequent review when assessing the degree of healing of a periradicular lesion.

A radiograph may be the first indication of the presence of pathology (Fig. 4). A disadvantage of the use of radiography in diagnosis, however, can be that the early stages of pulpitis are not normally evident on the radiograph.

If a sinus is present and patent, a small-sized (about #40) gutta-percha point should be

225. For dental caries to progress in dentine,

A. The dentine must contain soluble collagen.
B. Enamel must contain glycoproteins.
C. Diet must contain simple carbohydrate.
D. Diet must contain polysaccharides.
E. Pulp must contain complement.

Answer: C.

226. Signs and symptoms that commonly suggest cardiac failure in a patient being assessed for oral surgery are,

A. Elevated temperature and nausea.
B. Palpitations and malaise.
C. Ankle oedema and dyspnea.
D. Erythema and pain.
E. Pallor and tremor.

Answer: C.

227. In the inferior alveolar block the needle goes through or close to which muscles buccinator and:

A. Superior pharyngeal constrictor.
B. Medial pharyngeal constrictor.
C. Anterior pharyngeal constrictor.

Answer: A.

Interdigitation of the tendons of these two muscles constitutes pterygomandibular raphe.

228. The nerve supplying the TMJ is,

A. Auriculotemporal Nerve.
B. Nerve to masseter.
C. Facial nerve.

Answer: A.

229. How would you extract lower pre molar?

A. Rotation only.
B. Lingually.
C. Labially.

Answer: A.

230. In an X-ray the mesiobuccal root of upper first molars is elongated because of:

A. Mesio angular horizontal.
B. Too big vertical angulation.
C. Too small vertical angulation.
D. High angulation.

Answer: C.

Vertical angulation of the X-ray tubehead

The angle formed by continuing the line of the central ray until it meets the occlusal plane determines the *vertical angulation* of the X-ray beam to the occlusal plane (see Fig. 8.13).

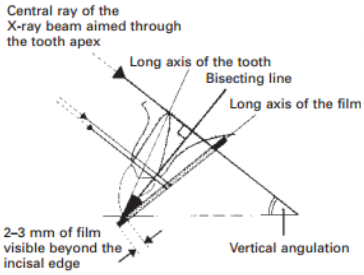

Fig. 8.13 Theoretical basis of the bisected angle technique. The angle between the long axes of the tooth and film is bisected and X-ray beam aimed at right angles to this line, through the apex of the tooth. With this geometrical arrangement, the length of the tooth in the mouth is equal to the length of the image of the tooth on the film, but, as shown, the periodontal bone levels will not be represented accurately.

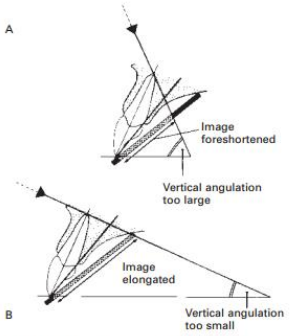

Fig. 8.17 Diagrams showing the effects of incorrect vertical tubehead positioning. **A** Foreshortening of the image. **B** Elongation of the image.

231. Density of film is decreased by increasing the:

A. MA.
B. Exposure time.
C. Developing time.
D. Rinsing time.
E. Patient tube distance.

Answer: E.

(ii) Density is in direct proportion to milliamperage and kilo voltage and is inversely proportional to focal spot (target) film distance

$$d = \frac{mA \times kVp}{Fsfd \times Filtration \times collimation}$$

(iii) Exposure time is inversely proportional to milli amperage and kVp. It is directly proportional to square of the focal spot film distance

$$T = \frac{(Fsfd)^2}{kVp \times mA}$$

232. An Increase in which of the following will decrease density of Radiograph?

A. Milliampere.
B. Time.
C. Kilovoltage.
D. Object-film distance.
E. Focal spot-object distance.

Answer: E.

233. Selection of the appropriate kilovoltage for dental films is influenced by:

A. Line voltage fluctuation.
B. Diameter of the primary beam of radiation.
C. Type of timer.
D. Tissue density.
E. Filter thickness.

Answer: D.

234. Which of the following is TRUE?

A. Antibiotics are useful in the treatment of ANUG.
B. Trauma of occlusal factors causes cleft or fibrous thickening of marginal gingivae.
C. All periodotal pockets can be detected by X-rays.
D. Periodontitis is the most common problem in teenage.
E. Perio disease is a primary cause of loss of teeth after 35 years of age.
F. None of the above.

Answer: E.

235. In severe periodontitis, the probe:

A. Gets stopped by calculus.
B. Goes beyond connective tissues of junctional epithelium.
C. Touches coronal end of junctional epithelium.
D. Touches the middle of junctional epithelium.
E. Touches sulculuar epithelium.
F. Cone shape and length.

Answer: B.

236. Which of the following is NOT characteristicof Down's syndrome?

A. Decreased neutrophil function.
B. Macroglossia.
C. Macrodontia.
D. An increased susceptibility to periodontal disease.
E. Congenitally missing teeth.

Answer: C.

237. Which gives the best prognosis?

A. Supra bone defect.
B. 1 walled pocket.
C. 2 walled pocket.
D. 3 walled pocket.

Answer: D.

3 walled has the best prognosis as it is surrounded on three sides by cancellous bone and one side by the cementum of the root surface (Oxford pg 184).

238. Lethal dose of paracetamol 500mg if taken once is:

A. 25 tabs.

B. 20 tabs.

C. 15 tabs.

Answer: B.

239. Who is responsible to manage bleeding socket, when patient reports after normal business hours?

A. The dentist who extracted the teeth.

B. The emergency doctor in the hospital.

C. The dentist on duty in hospital.

Answer: A.

If the patient unable to contact dentist who extracted the tooth, then duty doctor in emergency hospital (TG).

240. A patient reports to you with an exophytic lesion on the tongue and a raised white blood cell count of 2 x 109 per ml. You would:

A. Do a biopsy.

B. Refer for serologic testing.

C. Give acyclovir

Answer: A.

241. Blood test for INR should be undertaken:

A. 24 hours prior to the surgery.

B. 48 hours prior to the surgery.

C. 72 hours prior to the surgery.

D. On the day of the surgery.

Answer: A.

Organize blood test for INR within 24 hours before surgery. On the day of surgery it has to be checked again. INR 2.2 and less, proceed with the surgery without any need for tranexamic acid mouthwash, but if it is between 2.2-4.00, the procedure can be done but with this mouth wash. If INR is more than 4.00, do not proceed with surgery and refer the patient to his medical practioner. DO NOT CEASE WARFARIN.

242. Salivary patho diagnosis method least used:

A. Biochemical analyses.

B. MRI.

Answer: A.

243. A patient on the dental chair has cardiac arrest which is INCORRECT?

A. Observing the vital signs and check that the air way is clear is at high importance.

B. Expired air has 15% O2 only, and cardiac compressions achieve 30-40% of cardiac output.

C. Intermittent positive pressure at the rate of 40/min will reduce the chances of cerebral hypoxia.

D. Intermittent positive pressure is better than mouth to mouth when it has been given at the same rate.

Answer: C.

As far as ventilation is concerned in CPCR, there are various methods like mouth to mouth breathing (exhaled air is given that contains 15-17% O2, So B is also correct), Bag Valve Mask (device used mechanically to pump air, pumps room air that contains approximately 21% O2) and there are mechanical ventilators which can give Intermittent Positive airway pressure (IPAP) or Continuous Positive airway pressure (CPAP) of 100% O2, thus are preferred over manual breathing so D is also correct, the rate at which IPAP is given is about 10-15 ml O2/ min.

244. The best method to take X-ray of the maxillary sinus is:

A. Periapical radiograph.

B. Panoramic view.

C. Lateral cephaloghraph.

D. Occipitomental view (Water view).

E. Reverse Towne's view.

Answer: D.

245. Which of the following is not a part of the fully formed enamel organ?

A. Outer enamel epithelium.

B. Inner enamel epithelium.

C. Stellate reticulum.

D. Dental papilla.

Answer: D.

Enamel organ has for parts: outer enamel epithelium, inner enamel epithelium, stellate reticulum and stratum intermedium.

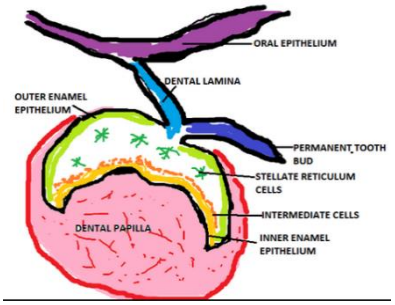

246. 18 years old female her weight is 52Kg and she is 163cm tall. On dental examination erosion of teeth on the most of her lingual surfaces is clearly showing. Dietary history revealed a daily rate of 5000 to 7000 Kcal/day. What is most probable would be her case?

A. Alcoholism.

B. Drug abuse.

C. Bulimia.

D. Excessive smoking.

E. Diabetic mellitus type I.

Answer: C.

Chronic, excessive vomiting has long been recognized as causing erosion of the teeth. The patient with an eating disorder such as anorexia nervosa or bulimia is the classic example.

247. Which one of the following is true in regards to osseointegration implants in dentistry?

A. Fibrous tissues are formed and integrated directly between titanium and bone.

B. Following insertion, implants can be immediately loaded without problem.

C. The success of the implants is directly proportional to its area of contact with bone.

D. The success of the implants depends mostly on low torque preparation and insertion of the fixture.

E. The success of integration is accurately investigated by immediate radiographic examination.

Answer: C.

248. Generalised loss of tooth structure by chemical means called:

A. Erosion.

B. Attrition.

Answer: A.

249. On X-ray, the buccal roots of 16 is considerably elongated; this is a result of,

A. Too great vertical angulation.

B. Inadequate vertical angulation.

C. Excessive object film distance.

Answer: B.

250. The principle muscle responsible for the opening of the mouth is:

A. Mylohyoid.

B. Anterior temporal.

C. Posterior temporal.

D. Anterior belly of digastric.

Answer: D.

251. Denture stomatitis is commonly associated with:

A. The continuous wearing of removable orthodontic appliances in otherwise healthy patient.

B. The proliferation of hypertrophic tissue at the denture periphery.

C. The overgrowth of some constituents of oral normal microflora.

D. Allergy to denture base material.

Answer: C.

en.m.wikipedia.org

uncommon. An orthodontic appliance may uncommonly produce a similar result.[2] However, mucosal trauma is thought increase the ability of *C. albicans* to invade the tissues.[5]

Aside from infection and mechanical trauma, inflammatory reactions of the mucosa beneath a denture can also result from irritation or allergy (allergic contact stomatitis) caused by the materials in the denture itself (acrylic, cobalt, chromium), or in response to substances within denture adhesives. Incomplete curing of the acrylic resin (the prosthetic material) may also be an involved factor.[1]

Denture stomatitis is usually associated with candidiasis that is caused by OVERGROWTH of candida yeast cells which are present in a few number in normal oral flora.

Since they have said COMMONLY associated with denture stomatitis so C is the answer. Denture stomatitis is not commonly associated with removable appliances.it happens, but is uncommon.

252. Which is NOT usually related to gingival inflammation in children?

A. Endocrine disturbance.
B. Viral infection.
C. Mouth breathing.
D. Spirochetal infection.
E. Streptococcal infection.

Answer: D.

253. Which of the following is the best evidence that a previous periodontal treatment is successful?

A. The patient keeps a 3 month recall appointment.
B. There is no extrinsic stain.
C. The patient demonstrates good understanding of brushing and flossing techniques.
D. There is no bleeding on probing.

Answer: D.

254. When do we start RCT after re implantation of immature tooth?

A. After 2 weeks.
B. Same appointment that we remove splint.
C. At future visit when signs of necrosis present.
D. Before replantation of tooth.

Answer: C.

255. Which of the following is included in the posterior limit of a maxillary denture?

A. Hamular notch.
B. Fovea palantini.
C. External oblique ridge.

Answer: A.

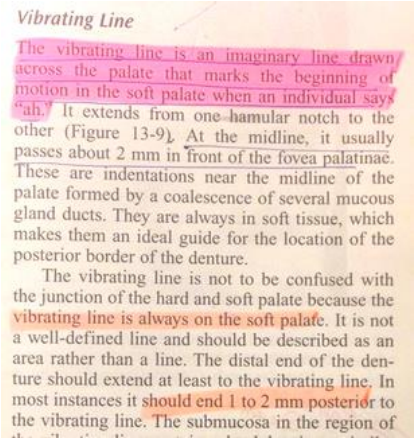

Vibrating Line

The vibrating line is an imaginary line drawn across the palate that marks the beginning of motion in the soft palate when an individual says "ah." It extends from one hamular notch to the other (Figure 13-9). At the midline, it usually passes about 2 mm in front of the fovea palatinae. These are indentations near the midline of the palate formed by a coalescence of several mucous gland ducts. They are always in soft tissue, which makes them an ideal guide for the location of the posterior border of the denture.

The vibrating line is not to be confused with the junction of the hard and soft palate because the vibrating line is always on the soft palate. It is not a well-defined line and should be described as an area rather than a line. The distal end of the denture should extend at least to the vibrating line. In most instances it should end 1 to 2 mm posterior to the vibrating line. The submucosa in the region of

256. What is the advantage of fixed-fixed bridge?

A. It can be used in inclined teeth with large pulp.
B. It can be used in a long span.
C. It can be used in over tapered abutment.
D. It can be used when there are different paths of insertion.

Answer: C.

Option C is correct because with the tapered abutment, retention can be increased by parallelism, or retentive means like groove and box.

B is right because you can have a 5 or more unit fixed bridge in case of a long span.

For tilted molar, (Shillingburg, 97), the best choice is to do orthodontic uprighting to make sure that the occlusal forces will be directed parallel with long axis of that tooth. Furthermore to avoid the other complicated solutions. If orthodontic correction is not possible:

1. Fixed-Fixed partial denture can still be made.
- Proximal half-crown on the most distal abutment but the tooth should not be affected by caries distally or the patient has high caries index.
- Telescopic crown on the distal abutment.
2. Fixed-Movable partial denture. Non-rigid connector is placed on the distal abutment after a full crown is done with full path of insertion parallel with long axis of the tilted tooth.

NOTE: the presence of dowel core or DO amalgam filling on the premolar would favor placement of non-rigid connector on that tooth, while extensive facial and/or lingual restoration on the tilted molar would call for the use of a telescopic crown.

257. How would you come to diagnosis of carious exposure in immature upper incisor?

A. Clinical appearance and thermal test.
B. Radiograph and thermal test.
C. Clinical appearance and radiograph.
D. Patient's history.

Answer: C.

Because for immature teeth, pulp sensibility test does not give reliable results.

258. In which of the following conditions is a calcium hydroxide root dressing contraindicated?

A. Internal resorption.
B. Vertical root fracture.
C. Lateral-external resorption.
D. Root caries.

Answer: D.

Treatment of Vertical Root Fracture

It involves extraction in most of the cases. In multirooted teeth root, resection or hemisection can be tried.

Other treatment options include retention of the fractured fragment and placement of calcium hydroxide or cementation of the fractured fragments.

Recently, repair of root fracture have been tried by binding them with the help of adhesive resins, glass ionomers and lasers. But to date, no successful technique has been reported to correct this problem **(Flow chart 32.1)**.

The question mentioned ROOT CALAN DRESSING that mean the tooth is nonvital, in D root caries means the tooth is still vital and no need to put endodontic dressing but CaOH can be used as indirect or direct pulp capping material for deep root caries.

Option B, CaOH can used as root dressing for one of the strategy to deal with vertical root fracture as mentioned in the attached picture.

Option A and C means that resportion occurs as a response to the inflammation of the pulp (inflammatory reportion) or trauma respectively, so once the inflamed pulp is removed the process will stop.

The two most important reasons for using CaOH in endodontics for permanent teeth are its antimicrobial effect and the potential to stimulate mineralized repair of pulp and periapical tissues. However, the usage of calcium hydroxide is not routinely recommended for primary dentition because its application frequently results in the development of chronic pulpal inflammation and internal root resorption.

259. For the definitive restorations, biologic width is important for:

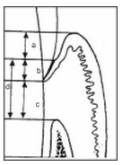

Figure 1
(a) Histological sulcus (0.69 mm), (b) Epithelial attachment (0.97 mm), (c) Connective tissue attachment (1.07 mm), (d) Biologic width (b+c)

A. Margin placement.
B. Proper gingival height.
C. Correct emergence profile.
D. All of the above.

Answer: A (Appendix I)

The biologic width is essential for preservation of periodontal health and removal of irritation that might damage the periodontium (prosthetic restorations, for example). The millimeter that is needed from the bottom of the junctional epithelium to the tip of the alveolar bone is held responsible for the lack of inflammation and bone resorption, and as such the development of periodontitis. The dimension of biologic width is not constant, it depends on the location of the tooth in the alveolus, varies from tooth to tooth, and also from the aspect of the tooth. It has been shown that 3 mm between the preparation margin and alveolar bone maintains periodontal health for 4 to 6 months. This 3 mm constitutes for 1 mm supracrestal connective tissue attachment, 1 mm junctional epithelium and 1 mm for gingival sulcus on an average. This allows for adequate biologic width even when the restoration margins are placed 0.5 mm within the gingival sulcus.

260. External root resorption can be caused by:

A. Calcium hydroxide.
B. Pulp necrosis.
C. Pulp infection.

Answer: C.

Pulp infection causes external root resorption by stimulating the clastic activity inflammatory reaction, pulp necrosis alone cannot cause periapical response unless it is infected that in turn causes external resorption.

261. A tooth to restore with gold inlay has a weakened cusp, what will u do for the weakened cusp?

A. Reduce the cusp then restore with an onlay.
B. Complete coverage prosthesis.

Answer:A..

262. After the placement of a restoration the patient comes back to you after week complaining of pain on biting and bleeding gums; what is the first thing you would look at?

A. Occlusal height.
B. Contacts areas.

Answer: B.

A would have been the choice if gingival bleeding wasn't there, but since there is bleeding. It might be because of gingival overhang of restoration, hence the contact area. Or pain after a week of restoration is commonly due to food impaction in the contact area.

263. What is correct in regard to cobalt chromium circumferential clasp?

A. They have round profile in cross section.
B. Rigid two third above the survey line and flexible one third below the survey line.
C. One third above and two third below the survey line.
D. Engages deepest area of the undercut for maximum retention.

Answer: B.

264. For an onlay prep during the restoration of a tooth, which one of the following is the most effective means for verifying adequate occlusal clearance?

A. Wax bite chew in.
B. Proper depth cuts.
C. Visual inspection.
D. Articulating paper.

Answer: A.

265. Root surface fracture most favorable prognosis in:

A. Apical third.
B. Coronal third.
C. Middle third.

Answer: A. (Appendix II)
Root canal therapy is not recommended on the tooth with horizontal root fracture in the apical third, because research has demonstrated that the pulp will remain vital in most cases with high percentage of successful healing without receiving endodontic treatments.

266. The non-rigid connector is placed:

A. Mesial to the distal retainer.
B. Distal to anterior retainer.
C. On anterior teeth.

Answer: B.

267. The freeway space:

A. Can be measured accurately in dentulous patients.
B. Sets to 2-4mm in the edentulous patient.
C. Is OVD minus VD at rest.

Answer: B.

268. Failure of denture is commonly due to:

A. Increased occlusal plane.
B. Decreased vertical dimension.
C. Insufficient denture bearing area.
D. Wrong freeway space.

Answer: D.

269. Precavitated lesion on enamel which is correct in the following:

A. The area can sometimes be remineralised completely.
B. It is not able to reharden the white lesion.
C. High concentration of fluorides at the area will effectively incorporate calcium & phosphate ions.
D. A & C.

Answer: D.

Fluoride can increase the superstauration of saliva in relation to calcium and phosphate thus accelerate the rate of mineralization. In addition the presence of fluoride will form fluoroapetite crystals that are more acid resistant to caries than hydroxyapatite.

270. The 11 year old patient patient fell of his kickboard and hit his upper anterior teeth against a fence. He felt a bits of his tooth #8 in his mouth but didn't save them. He presented at his dentist's office 25 minute after the trauma. The initial examination revealed a complicated fracture of tooth #8 with grade 2 mobility and percussion sensitivity. Tooth #9 had a chipped incisal edge involving the dentine grade with 1 mobility and slight percussion to sensitivity.

(Cameron 170 to the end of the chapter)

I. Considering the time elapsed since trauma:
A. Tooth #8 should be extracted immediately.
B. The pulp is likely to have become necrotic and should be extirepated.
C. The pulp tissue in this case is superficially contaminated.
D. The pulp tissue is unaltered and no treatment is necessary.
E. Treatment can be delayed without consequences.

Answer: C.

II. Unaltered tooth position and grade 2 mobility combined with percussion sensitivity will most likely be diagnosed as :
A. Lateral luxation.
B. Concussion.
C. Intrusion.
D. grade1.
E. Alveolar fracture limited to facial cortical plate.
F. Chronic apical periodontitis.

Answer: A.

III. The most adequate treatment in this case is:
A. Build up and crown placement as soon as possible.
B. pulpectomy and immediate root canal filling to avoid contamination.
C. Partial pulpotomy and composite build up.
D. pulpotomy followed by aminimum of 90 days of CaOH.
E. pulpectomy followed by aminimum of 90 days of CaOH.

Answer: C.

271. ***(Self-made question by Eshan Verma)*** *A 14 years old boy was injured while playing who reported to your clinics within an hours after injury. Picture given is the radiographic finding of the patient. There are no other significant clinical finding and electric pulp testing is positive.*

Answer the following questions: (**Appendix III**)

I. What is the most common cause of dental injuries in the permanent dentition?

A. Traffic injuries.

B. Falls.

C. Violence.

D. Sports.

Answer: B.

II. What type is dental injury this boy is suffering from?

A. Subluxation.

B. Lateral luxation.

C. Extrusive luxation.

D. Intrusive luxation.

Answer: B.

III. Which of the following is the most expected pulpal outcome in this patient?

A. Pulp survival.

B. Pulp canal obliteration.

C. Pulp necrosis.

D. All of the above.

Answer: C.

IV. Had this patient been 8 years old, what would be the most expected pulpal outcome?

A. Pulp survival.

B. Pulp canal obliteration.

C. Pulp necrosis.

D. All of the above.

Answer: B.

V. What is the most expected PDL response in this patient?

A. Normal.

B. Surface resoption.

C. Inflammatory resorption.

D. Replacement resorption.

E. All except A.

Answer: A.

VI. What is the most common periodontal healing complication expected in this patient?

A. Repair related resorption.

B. Infection related resorption.

C. Ankylosis related resorption.

D. Transient marginal breakdown.

Answer: A.

VII. Considering splinting in this case, which of the following is recommended?

A. Rigid for 10 days.

B. Non rigid for 10 days.

C. Rigid for 3-4 weeks.

D. Non rigid for 3-4 weeks.

Answer: D.

VIII. When the follow-up radiograph was taken at 1 month there was loss of lamina Dura in the previously injured area and clinically a granulation tissue was seen in the gingival area what does it indicate and what intervention is needed?

A. It is transient marginal breakdown that Will resolve later most probably. So no intervention is needed at this visit.

B. It is apical breakdown and will require curettage of granulation tissue at this visit.

C. It is marginal breakdown and will require curettage of granulation tissue at this visit.

D. It is transient apical breakdown and will resolve later so do nothing at this visit.

Answer: A.

272. Hybrid shed is used in posterior because:

A. Of its surface characteristics.
B. modulous of elasticity is better to resist occlusal forces.

Answer: B.

273. Prostho:enamel shell crack most common reason is OR Contraindication of Porcelain shell crown:

A. Edge to edge bite.
B. Class II div1.
C. Class II div2.
D. Class 3.

Answer: A.

274. What is the advantage of acrylic resin over Cr-Co?

A. Cost.
B. Plaque control.
C. Ease of adding teeth.
D. Better thermal conductivity.

Answer: C.

275. Taking impression with elastomers for maxillary fixed bridge using custom tray, the special tray should be:

A. Perforated.
B. Having space of 3mm.
C. Having space of 5mm.
D. Tray can be flexed.
E. Adhesive not required.

Answer: B.

276. Patient wears complete denture in upper jaw for 20 years, opposing only few lower ant teeth, no posterior prosthesis in the lower jaw. What will be the effect?

A. Rapid palatal resorption.
B. Lower ant teeth mobility.

Answer: B.

This is called combination syndrome. Typical case of the combination syndrome patient with a complete edentulous maxilla opposed by the anterior mandibular teeth and a distal-extension removable partial denture: a severe resorption of the anterior maxillary alveolar ridge, super-eruption of unopposed 6 mandibular anterior teeth, and overgrowth of maxillary tuberosities.

In this case the occlusal forces are concentrated exclusively on the premaxillary region that if left uncorrected will lead to bone resorption and replacement by mobile, hyperplastic tissue. These destructive region changes in this region allow displacement of denture superiorly, and the resultant change in the occlusal plane can allow a down growth of the maxillary tuberosities. Other problem for that patient, the pattern in bone resorption is different between both arches leading lead to discrepancy in the size between maxilla and mandible after resortipon. If the maxillary arch left edentouls for a long time without wearing prosthesis causes the maxilla to be smaller than the mandible, making the establishment of correct occlusal plane in some cases is impossible. The same problem happens if the occlusal plane of the maxillary arch is not uniform because of different time of extraction and other factors related to surgical procedures.

277. What determines the limits of the inferior border of the lingual component of an RPD (lower RPD major connector)?

A. Elevation of anterior floor of the mouth.
B. Space of the tongue.
C. Sub Mandibular duct opening.
D. Anterior crowding.
E. Whether lingual plate or lingual bar is used.

Answer: A.

278. Attrition in elderly people doesn't cause loss of contact. The reason is:

A. Deposition of bone around a fundus.
B. Deposition of cementum at apical area.
C. Both A & B.

Answer: C.

279. What is incorrect about facial paralysis after mandibular nerve block?

A. Inability to blink.
B. Inability to smile.
C. Incorrect method.
D. Injury to facial nerve.

Answer: D.

280. Facial paralysis after inferior alveolar nerve block is due to:

A. Injection into the parotid gland.
B. Aberrant facial nerve.
C. Sympathetic stimulation.
D. All of the above.

Answer: D.

281. Immediately following an inferior alveolar nerve block, the patient exhibits facial paralysis. The needle has penetrated through which ligament?

A. Stylohyoid.
B. Stylomandibular.
C. Sphenomandibular.
D. Ptrygomandibular.

Answer: C.

282. Which of the following is TRUE in regards to high risk patient?

A. 0.1ml of blood from Hepatitis B carrier is less infective than 0.1ml of blood from HIV patient.
B. 0.1ml of blood from Hepatitis B carrier is more infective than 0.1ml of blood from HIV patient.
C. Level of virus are similar in the blood and saliva of HIV patient.
D. Level of virus in the saliva is not significant for Hepatitis B patient.
E. The presence of Hepatitis B core Antigen in the blood means that active disease is not present.

Answer: B.

283. X ray shows teeth that are just 'eroded' stumps leftover in anterior region. The patient says that he drinks 3 glasses of wine and has 40 cigarettes per day. He was diabetic type 1 and over weight. He needed to raise the bite to restore ant. Teeth. When he came back after that he quit smoking and lost weight. (Odell, case 60&61)

I. He is suffering from:
   A. Erosion.
   B. Abrasion.
   C. Abfraction.
   D. Attrition.

Answer: A.

II. How will you know the process is still active?
   A. Shiny well demarcated facets.
   B. Dentine is stained.
   C. Dentine is unstained.
   D. Restoration margins elevated with dentine exposed.

Answer: C.

III. Management of this case:
   A. Treatment of underlying condition.
   B. Seal exposed dentine to prevent injury to the pulp.
   C. night guard
   D. temporary restoration
   E. Dahl appliance.

Answer: A.

IV. Considering that his underlying condition is controlled, you tell him the various treatment options including increasing his vertical dimension to a restorable state, however cost is a factor and he opts for direct composite restorations, what would have been the best replacement of his missing teeth?
   A. Removable partial denture (confirmatory approach).
   B. Anterior and posterior composite on the occlusal surface adjusting his bite.
   C. Posterior Dahl Appliance.

Answer: A.

V. He returns to your clinic with a very optimistic approach. What best signifies the reason for his newly found confidence? (What is the most significant change in his management)?

A. An improvement in his general systemic health.
B. Better appearance of his teeth as shown in the photograph.
C. .
D. .
E. .

Answer: A. (Quitting smoking).

*284. There was a picture in which the patient had large composite fillings in 34 and 44 ...33 to 43 were present. You had to give her a lower denture and you decided to give an immediate RPD. Somewhere in the case it said that you had to extract certain teeth coz they were mobile (and i never understood afterwards if he had talked about the mobile lateral to lateral .... because if these were the teeth being extracted, the question with lingual plate would be affected... check below) *** please edit*

1. It was about the treatment planning (as remembered)
   A. Give full crown coverage on 34 and 44 and then give the RPD.
   B. Composite are strong enough and clasps could be places as such..etc etc

   Answer: B.
2. If you decide to give acrylic denture, what would u explain the patient, why is acrylic better than the cobalt chromium?
   A. one of the choices was that teeth could be added later to acrylic

   Answer A.
3. If you decide to give cobalt chromium RPD. What does patient need to know?
   A. The denture will need relining and sometime might have to be remade.
   B. This denture will give minimum discomfort to the extraction sockets.

   Answer: A.
4. During impression taking, you will do so with:
   A. Alginate.
   B. Zinc oxide eugenol.
   C. Rubber based (polyvinyl silicone.
   D. Polyether.

   Answer: A.
5. If u decide to give lingual plate along with RPD, What would be the purpose of lingual plate?
   A. stabalise the anterior teeth
   B. indirect retention

Answer: B.

6. How to gain stability?
   A. By denture extension to cover ridge ** question not complete

   Answer:

285. Most stable impression is:

A. Polyether.
B. Hydrocolloid.
C. Polyvinyl siloxane.
D. Agar.

Answer: C.
Polyether needs special humidity control because it is hydrophilic.

286. Impression material for making final impression for implant prosthesis is:

A. Additional silicone.
B. Condensation silicones.
C. Polyether.
D. Polysulphides.

Answer: A.

287. In regards of Polyvinyl siloxane, it has the following characteristics except:

A. Should be poured after an hour if palladium is not involved.
B. Should be immediately poured.
C. Dimensionally stable until a week.
D. Suitable for intrasulcular impressions.
E. Refrigeration increases its working time.
F. Can be sterilized.

Answer: B.

Several authors have reported hydrogen gas bubble formation on the surface of gypsum dies poured immediately from polyvinyl siloxane impressions. Manufacturers have now eliminated the possibility of this side reaction by proper purification and accurate proportioning of the materials, and by the addition of palladium to the pastes as a hydrogen absorber. It is no longer necessary to wait for one hour before pouring these impressions.

288. Which material has the longest shelf- life?

A. Polyvinyl-siloxane.
B. Polysulfide.
C. Zinc oxide.
D. Polyether.

Answer: D.

289. Which impression material is the best when more than one cast is to be poured?

A. Condensation silicones.
B. Polysulfide.
C. Polyether.
D. Additional silicones.

Answer: D.

Polyether is stable material but it is hydrophilic and absorbs water from setting plaster and stone.
Condensation silicone and polysulfide are not suitable for more than one pouring.
Addition silicone is hydrophobic material and dimensionally stable.

290. When should pour polyether impression material?

A. Within 24 hours after taking impression.
B. Within 30 minutes after taking impression.
C. Should be stored dry and then poured.
D. Should be stored in humid place.

Answer: C.

Dental DECKS

- Condensation silicone, wait for 20-30 minutes for stress relaxation.
- Polysulfide, wait for 1 hour to pour for stress relaxation.
- Addition silicone, wait for 1 week to pour because of hydrogen gas release occur if a reaction between moisture and residual hydrides of the base polymer occurs. The result is a cast with small voids if the impression is poured too soon after removal from the mouth.
- Polyether can be poured immediately but should be kept dry and then poured because it is hydrophilic.

291. A well-made full crown, constructed by the indirect technique, from a silicone impression that has been allowed to bench set for 24 hours, will probably show the following characteristic when tried in the patients mouth:

A. It will seat on the preparation well but will be too tight in the interproximal areas.
B. Its interproximal contacts will be slightly open and the occlusal surface will be in supra-occlusion.
C. It will have open margins even though it fits the die well.
D. I will fit the preparation well but the occlusal surface will be in infraocclusion.

Answer: C.
Due to shrinkage towards the tray the die made from this impression whill be wider and shorter, since die is made from this impression and the restoration on this die, it will fit the die will, however will have open margins(wider due to shrinkage towards the tray).

292. In comparing polysulfide, polyether and addition cured silicone impression materials, which of the following statements is true?

A. All three of the materials contract slightly during curing.
B. All the materials expand slightly upon cooling from mouth temperature to room temperature.
C. After one week, addition cured silicones will undergo more distortion than polysulfides.
D. Lead oxide is used as an activator in silicones.

Answer: A.

NDEB question

- All 3 materials have thermal contraction which results in negative volume change.
- Polysulfide is very unstable on storage while a silicone is extremely stable.
- Lead oxide is the activator of polysulfide make it very messy in use.
- Polysulfide and condensation silicone contract due to vaporization of reaction products. Addition silicone and polyether polymerize and are dimensionally stable.

293. The purpose of post-treatment retention of an orthodontic case is:

A. To allow bony changes.
B. To prevent tongue thrusting.
C. To let the patient get used to the new functional position of the teeth.
D. To encourage space closure.

Answer: A.
Bone biology dictates that resorption is faster than deposition. Therefore we need retention more importantly for the bone to settle down.

294. Correction of an inadequate zone of attached gingiva on several adjacent teeth is best accomplished with:

A. Apically repositioned flap.
B. Laterally positioned sliding flap.
C. Double-papilla pedicle graft.
D. coronally positioned flap.
E. Free gingival graft.

Answer: E. (Odell, 21)

295. The stiffness of gold alloy is determined by its:

A. Proportional limit.
B. Modulus of elasticity.
C. Ultimate tensile strength.

D. Flow.

Answer: B.

Stiffness=Rigidity

296. Pulp has been extirpated, root canal debrided and a dressing has been sealed in the canal. The tooth later develops apical periodontitis. This condition may be due to:

A. Mechanical irritation of the PA area through instrumentation.
B. Chemical irritation by drugs used in the canal.
C. Presence of microbes.
D. Any one of the combination of the above.

Answer: D. (Boucher)

297. Following the removal of a vital pulp, the root canal is medicated and sealed. The patient return with apical periodontitis. The most common cause is:

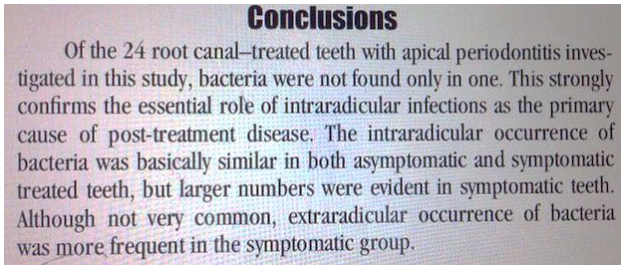

Conclusions

Of the 24 root canal–treated teeth with apical periodontitis investigated in this study, bacteria were not found only in one. This strongly confirms the essential role of intraradicular infections as the primary cause of post-treatment disease. The intraradicular occurrence of bacteria was basically similar in both asymptomatic and symptomatic treated teeth, but larger numbers were evident in symptomatic teeth. Although not very common, extraradicular occurrence of bacteria was more frequent in the symptomatic group.

A. Overinstrumentaion.
B. Lateral perforation.
C. Incprrect medication.
D. Pulp tisse left in the root canal.
E. Infection.

Answer: A.

For necrotic pulp or infected pulp, the most common cause of apical disease after RCT is infection or presence of microbes inside the canal. While for vital pulp, the most common cause of apical disease after RCT is overinstrumention since there is no previous infection inside the canal.

298. Patient reported to you 30 min after trauma to central incisor. Patient is 10 years old and there is traumatic exposure of pulp. What will be the line of treatment?

A. Coronal pulpotomy and CaOH base and then permanent filling.
B. CaOH base and permanent filling.
C. 1-2 mm. of coronal pulp extirpated and CaOH and then permanent filling.
D. Pulpectomy.

Answer: C.

C-vek Pulpotomy because during 30 minutes, the superficial layer of the pulp gets contaminated, at least by saliva. And to decide for direct pulp capping the tooth must be isolated by rubber Dam during the exposure time. Moreover, Pulpotomy is the golden treatment for apixogenesis which is required in this case.

299. A 12 year old girl damaged her upper anterior teeth in school. There are no extra oral injuries but both upper central incisors are mobile and palatally displaced. (Cameron, 181)

Table 1. Recommended Splinting Times

Type of injury	Splinting time	Splint type
Subluxation	2 weeks	Flexible
Extrusive luxation	2 weeks	Flexible
Avulsion	2-4 weeks	Flexible
Lateral luxation	4 weeks	Flexible
Root fracture (middle third)	4 weeks	Rigid
Alveolar fracture*	4 weeks	Rigid
Root fracture (cervical third)	4 months	Rigid

* In cases, when teeth are not present (avulsion), fixation may be obtained by using firm pressure to realign the bone fragments and stabilizing the area by suturing the gingival tissues.

I. What tests would you perform?

A. Vitality tests for all upper and lower incisors.
B. Vitality tests for only upper incisors.
C. Vitality tests for all the teeth.

Answer: A. (baseline reading for future assessment)

II. A fracture in the tooth occurred in the middle third of the root. Ideal treatment would be:
   A. Rigid splinting for 2-3 weeks.
   B. Rigid splinting for 6 weeks.
   C. Flexible splinting for 2-3 weeks.
   D. Flexible splinting for 6 weeks.

Answer: A.

III. If the coronal portion becomes non-vital, what would the treatment be?
   A. Entire pulp should be extirpated.
   B. Pulp should be extirpated till fracture line and guttapercha placed.
   C. Pulp extirpated till the fracture line and calcium hydroxide placed to induce barrier formation.
   D. None of the above.

Answer: C.

300. You re-implant the avulsed tooth and splint it. When should the endodontic treatment be commenced in this case?(Cameron, 195)

A. After 1 week.
B. Immediately after re-implantation.
C. After 2-3 weeks.
D. After one month.

Answer: A.
Endodontic therapy involving obturation with gutta percha or the placement of calcium hydroxide dressings
At the time of replantation delays periodontal healing and hastens replacement resorption in mature teeth.
Endodontic therapy should be delayed until the initial period of soft tissue healing takes place. However, since revascularization rarely occurs in mature teeth, and as pulp necrosis contributes to inflammatory root resorption, it has been recommended that in mature teeth pulps should be extirpated as soon as possible74 or after initial periodontal healing has occurred (seven to 10 days).
The only teeth that has a chance of revascularization is the immature tooth with open apex replanted within 30-45 min. All other teeth should be extirpated in 7-10 days. (Odell)

301. High content copper amalgam: (Mount&Hume, 221)

A. Generally requires greater energy to accomplish trituration.
B. Should be placed rapidly in large increments.
C. Continues to leak since the corrosion products do not formed.
D. Does not cause galvanism in oral environment.
E. Is equally effective as conventional alloys in clinical studies.

Answer: E.

302. Amalgam:

1. Spherical alloys shrink slightly when setting.
2. Lathe cut alloys expand slightly when setting.
3. Admix alloys are dimensionally stable when setting.
4. High copper content alloys have improved resistance to tarnish and corrosion.
   A. (1) (2) (3).
   B. (1) and (3).
   C. (2) and (4).
   D. (4) only.
   E. All of the above.

Answer: D.

303. Marginal breakdown is greater in amalgam:

A. Containing Zn and Zn free alloys.
B. With high creep characteristics.

Answer: B *(Mount&Hume, 221)*.

304. When amalgam shows fracture?

A. The wider is the gap the higher is the chance of a secondary caries.
B. You can seal the margin with fissure sealant to prevent further breakdown.
C. Secondary caries may develop.

Answer: A.
Wider the gap, more penetration of plaque, more cariogenic action.
It is self-sealing, corrosion products will form as the restoration ages, it will seal the narrow gaps but difficult to cure wider on. As the gap increases so are the chances for caries

305. Most important function of matrix is:

A. Contouring and shaping.
B. Prevent excess material into gingiva.
C. To separate from adjacent tooth.
D. Prevent marginal leakage.

Answer: A.

306. A patient wearing denture complains of pain in lower premolar region spreading to lower lip, which is sharp. The most possible cause is:

A. Change in occlusion.
B. Altered vertical dimension.
C. Trigeminal neuralgia.

Answer: A.

307. When a patient wearing a complete dentures makes a whistling sound while enunciating the (S) sound, it is caused by:

A. The anterior teeth being placed too far labially.
B. The anterior teeth being placed too far lingually.
C. Too great a vertical overlap.
D. The palatal vault being too high and narrow.

Answer: D.

308. What is the main function of EDTA in endodontics?

A. Decalcification of dentine.
B. Cleaning debris from root canal.
C. Lubrication of canal.
D. All of above.

Answer: A.
In dentistry, chelating agents bind with calcium and carry it out of the canal. The chelating agent most used in endodontics is EDTA. The smear layer, which covers the dentinal tubules, is created during the instrumentation procedure and is composed of dentin, liquid from the irrigants, and tissue debris. Removal of the smear layer from the root canal wall is a key step in endodontics. We would like to remove the smear layer and expose the dentinal tubules for 2 reasons. One reason is to allow the endodontic sealer to penetrate into the tubules for a more intimate fit, hopefully better sealing of the canal. Secondly, by removing the smear layer, and consequently opening up the tubules, we can

expose the bacteria that are living there and causing apical periodontitis. Once exposed, the bacteria are susceptible to the disinfecting irrigants we use.

309. In removable partial denture, the principle of an indirect retainer is that:

A. stabilize against lateral movement.
B. prevent settling of major connectors.
C. restrict tissue movement at the distal extension base of the partial denture.
D. minimize movement of the base away from the supporting tissue.

Answer: D.

310. Transmission of fluid in dentinal tubules is by:

A. Hydrodynamic pressure (Osmotic).
B. Mechanical.

Answer: A.

311. A Patient with lower denture complaining of paresthesia of the lower lip, the most common cause is:

A. Pressure on mental foramen.
B. Pressure on the genioglossus.
C. Pressure on mylohyoid muscles.

Answer: A.

312. The minimal labial tooth reduction for satisfactory aesthetics with porcelain fused to metal crown is:

A. 1mm.
B. The full thickness of enamel.
C. 1.5 mm.
D. 2.5mm.
E. One third of the dentine thickness.

Answer: C.

313. The first molars are extracted in both arches:

A. The bone resorption will be the same for both arches.
B. Resorption is more on the palatal side of maxillary molars.
C. Resorption is more on lingual side of mandibular molars.
D. The ridge height resorbs more in maxilla than mandible.

Answer: C.

314. Patient with overjet 6mm and canine and molar class 2 relation:

A. lower arch well alined teeth with tx?.
B. Bionator.
C. Extration of upper two premolar.

Answer: C.

If the patient is a growing patient (up to 15 years), Bionator appliance is used but if older extract upper first premolars.

A removable functional appliance (Bionator) is the same as twin block or monoblock but different shape. All used in class 2 treatment in growing patients alone if the patient has normal maxilla and deficient mandible and with head gear if the patient has prognathic maxilla.

315. A fixed partial denture is to be constructed for the mandibular arch of a 35 year-old female. The opposing permanent maxillary first molar is extruded 3mm beyond the plane of occlusion. The best way to correct this situation is to:

A. reduce and reshape occlusal length of the tooth by 3mm.
B. extract the opposing tooth and replace it with a fixed partial denture.
C. crown restoration of the maxillary molar to a satisfactory plane of occlusion with a cast restoration.
D. cut the maxillary extruded molar off the working cast, construct a mandibular fixed prosthesis and equilibrate the maxillary molar to the new occlusal plane after the prosthesis is cemented.

Answer: C.

316. A contraindication for serial extraction is:

A. Class I skeletal pattern
B. Deep bite.
C. Mixed dentition stage of dental development.
D. Severe crowding.

Answer: B.
(Cameron, 421 Stryder Martini).
Stryder Martini idea behind serial extraction is to let the upper premolar erupt ahead of the canine so that it can be extracted to allow compensation for crowding. But Serial extractions cause lingual tipping of the lower anterior teeth, hence contrainicated in deep bites as they worsen the bite. Extractions lead to a lower occlusal table in the posteriors.
We do serial extractions on mixed dentition period and the good candidate for it is those with class one Malocclusion including crowding.
<u>Contraindications of serial extraction:</u>

- Class 2 and class 3 malocclusion with skeletal abnormalities.
- Patients with adequate spacing in dentition.
- Cases of anodontia/oligodontia.
- Patients with open bite and deep bite.
- In cases of midline diastema.
- Class 1 malocclusion with minimal space deficiency.
- Unerupted malformed teeth e.g. dilacerations.
- Extensive caries or heavily filled first permanent molars.
- Mild disproportion between arch length and tooth material that can be treated by proximal stripping.

317. Following loss of a permanent mandibular first molar at age 8, which of the following changes are likely to occur?

1. Distal drift of second premolar.
2. No movement of second premolar.
3. Mesial drift of second permanent molar.
4. No movement of second permanent molar.

A. (1) (2) (3).
B. (1) and (3).
C. (2) and (4).
D. (4) only.
E. All of the above.

Answer: B.
<u>Ideal timing of first permanent molar extraction</u>
In the upper arch, the developmental position of an unerupted second permanent molar generally ensures that this tooth will achieve a good occlusal position following extraction of the first

permanent molar. In the lower arch, achieving a good occlusion is more dependent upon the timing of the first permanent molar extraction. Generally, whenever practical the lower first molar should be extracted when there is radiographic evidence of early dentine calcification within the second molar root bifurcation. This usually occurs within a chronological age range of 8 to 10 years.
If the first molar is extracted before the age of eight years, there is often no radiographic evidence of third molar development. In addition, in the lower arch:

- The second premolar can drift distally into the extraction space, tip and rotate.
- The labial segments can retrocline with an accompanying increase in the overbite.

If the first molar is extracted during the later stages of second molar eruption:

- The second molar may tip mesially and rotate mesio-lingually, producing spacing and poor occlusal contacts.
- The erupted second premolar can migrate distally.

318. An 8 year old patient has a permanent maxillary right first molar extracted because of caries. The most appropriate management to prevent a malocclusion is to:

A. place a space maintainer.
B. wait for the second molar to erupt into the space.
C. extract the permanent mandibular right first molar to equalize the tooth size ratio on the right side.
D. extract the permanent maxillary left first molar to maintain symmetry in the upper arch.

Answer: B.

319. A mandibular permanent first molar had to be extracted, this will affect:

A. Adjacent teeth.
B. Teeth in the same quadrant.
C. Both arches the same side.
D. Full mouth.

Answer: D.

320. Ankylotic primary second molar in the mandible is not always a good space maintainer because of:

A. mesial inclination of the 1st permanent molar.
B. It does not keep up with the rest of occlusion.
C. Dull on percussion.

Answer: B.

321. The most appropriate treatment following the extraction of a first primary molar in a 4 -year old child is:

A. regular assessment of arch development.
B. to perform space analysis.
C. insertion of a space maintainer.
D. extraction of the contra-lateral molar.
E. extraction of the opposing molar.

Answer: C. (Cameron, 417)

322. What is the ideal length for a post in post-core in an endodontically treated tooth?

A. 2/3 of the root length.
B. ½ of the tooth length.
C. 1.5 times that of the crown.
D. Same as the anticipated crown.

Answer: C.
Ideal length is 1.5 and minimum should be the same as crown or 2/3 of root length, with 4-5mm of guttapercha apically.

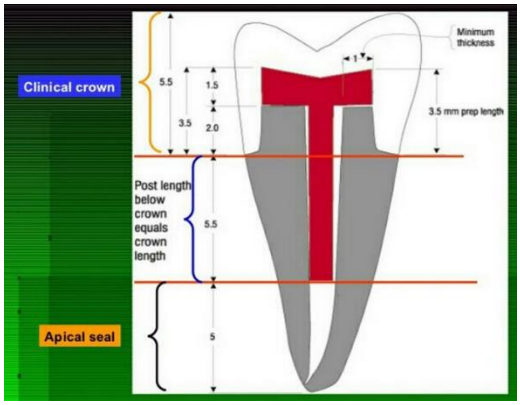

becomes a distinct possibility. If a dowel is used, its extension into the root must at least equal the length of the crown for optimum stress distribution[63] and maximum retention, or the dowel should be two-thirds the length of the root, whichever is greater (Fig 13-33). A minimum length of 4.0 mm of gutta-percha, and more if possible, should remain at the apex to prevent dislodgment and subsequent leakage. If it is not possible to meet these

The longer the dowel, the greater its retention. A tooth with dowel that is three-quarters the length of the crown or shorter has less chance for success than a tooth that had no dowel at all. However, the success rate of dowel-treated teeth can increase to more than 97.5% when the dowel length equals or exceeds the length of the crown (Schillingburg, 195). Dowel diameter should be no more than one third the root diameter at CEJ and at least 2mm less than the crown diameter in the midroot (Schillingburg, 203).

Most endodontic texts advocate maintaining a 5-mm apical seal, however, if a post is shorter than the coronal height of the clinical crown of the tooth, the prognosis is considered unfavorable, because stress is distributed over a smaller surface area, thereby increasing the probability of radicular fracture. This means that length the same as the crown is the minimal accepted below it will mostly fail (Rosenstiel)

323. The ideal length of core in the fabrication of crown and core ofendodontically treated tooth is:

A. 1.5 of crown length.
B. The length of the crown.
C. 2/3 tooth/root length.
D. ½ root length.

Answer: Notice that the question is regarding the length of CORE that should be obviously shorter than crown and thus none of the option seems to be correct, the core length should be same as crown preparation to receive the crown.
The length of the post should be 1.5 of the core, or the post should be 2/3 of the root length as a minimum requirement.

324. The objective of pulpotomy is to:

A. Preserve vitality of coronal pulp.
B. Preserve vitality of entire pulp.
C. Preserve vitality of radicular pulp.
D. Regenerate a degenerated and necrotic pulp.
E. Pulp capping will promote secondary dentine.

Answer: C.

325. The objective of pulp capping is to:

A. preserve vitality of coronal pulp.
B. preserve vitality of entire pulp.

C. preserve vitality of radicular pulp.
D. regenerate a degenerated and necrotic pulp.
E. none of the above.

Answer: B.

326. Vertical dimension at rest:

A. Varies with posture.
B. Increases on tooth extraction.

Answer: A.

Vertical dimension (at rest) is physiological rest position, changes with age, changes with attrition and head posture. When head is tilted back it increases and mandible is more retruded, and when head is tilted front it decreases and mandible is more forward. For this reason, one must record it with head straight and eyes looking at horizon. VDR is the position of mandible when forces pulling the mandible (elevator muscles) up and pulling it down (depressors + gravity) are in equilibrium, and therefore have minimal muscle tone (not zero). Obviously, if u keep lower denture in the mouth while recording VDR, due to the weight of the denture, the gravity will be more and hence, the equilibrium will be at more increased VDR. In CD we first record VDR and reduce the rims by 2-4 mm (freeway space) to calculate VDO.

327. What is TRUE about vertical dimension?

A. Does not change for the whole life.
B. Decreases when head is tilted back.
C. Increases when a lower denture is placed in mouth.

Answer: C.

328. When considering the reestablishment of the proper vertical dimension of occlusion (VDO), which statement is true?

A. VDO is the vertical length of the face as measured between 2 arbitrary points selected above and below the mouth when natural teeth or wax rims are in contact in centric.
B. The VDO is always greater than vertical dimension of rest VDR.
C. The VDO and the interocclusal distance are not equal to VDR.
D. VDO is also known as freeway space.

Answer: A.

329. The physiologic rest position of the mandible is:

1. a position determined by the musculature.
2. a fairly constant position throughout life.
3. used in determining occlusal vertical dimension.
4. used when making a centric interocclusal record.

A. (1) (2) (3)
B. (1) and (3)
C. (2) and (4)
D. (4) only
E. All of the above.

Answer: B.

330. Which of the following is true regarding TMJ dysfunction?

A. It is always due to arthritis, should be treated with NSAIDS before attempting surgery.
B. Raising bite increases the space in the joint and should be attempted before surgery.

C. It is mostly due to the medial movement of the condylar head over the glenoid fossa.

Answer: B.

331. Resting face height in edentulous patients:

A. decreases when head is tilted back.
B. increases when lower denture is inserted.
C. does not change over time.

Answer: B.

332. In patient suffering with angina, pain will not be felt at:

A. Jaw.
B. Neck.
C. Centre of chest.
D. Over the heart.

Answer: D.

333. Radiograph for periodontal diagnosis:

A. Bitewing.
B. IOPA.
C. OPG.

Answer: A.

334. Bone regeneration surgery done for:

A. Infrabony.
B. suprabony

Answer: A.

335. Deepest zone in dentinal caries would be:

A. sclerotic area.
B. softenes dentin.
C. demineralized area.

Answer: A.

336. The biting load of denture base to tissues compared to teeth is:

A. Ten times more.
B. Ten times less.
C. Equal.
D. Under compression.

Answer: B.

337. What is true about partial dentures?

A. They cause immediate changes in the oral plaque behavior.
B. Night wearing of dentures reduces plaque accumulation.
C. Relieving the gingival area reduces the gingival enlargement.

Answer: A.

338. What is not true about pemphigus?

A. Biopsy of fixed tissue gives straightforward diagnosis.
B. Autoimmune reaction affecting basal cell.
C. Level of autoantibodies can be assessed and used for regulating the dose and disease progress.
D. Can be cured with topical steroids.

Answer: B. (Odell, 193)

339. Which of the following is seen in benign mucosal membrane pemphigoid?

A. Tzanck cells.
B. Intraepithelial vesicles.
C. Scarring of conjunctiva.
D. Histology like aphthus ulcer.

Answer: C.

Cicatricial pemphigoid, another commonly used name for this process, is derived from the word cicatrix, meaning scar. When the conjunctival mucosa is affected, the scarring that results is the most significant aspect of this disorder because it invariably results in blindness unless the condition is recognized and treated. Interestingly, the oral lesions seldom exhibit this tendency for scar formation.

The pemphigoid blister forms in a subepithelial location, producing a thicker, stronger roof than the intraepithelial, the same feature could be seen with pemphigus but there is acantholytic pemphigus blister.

Biopsy of perilesional mucosa shows a split between the surface epithelium and the underlying connective tissue in the region of the basement membrane.

Tzanck cell refers to a free-floating epithelial cell in any INTRAEPITHELIAL vesicle (Neville).

340. Chlorhexidine 0.2% - culture S. Sanguis in active planktonian. If compare with plaque culture – how the growth occurs in plaque?

A. Faster.
B. Slower.
C. No change.

Answer: A.

chlorhexidine disrupts plank faster than plaque.

Free-floating bacteria existing in an aqueous environment, the so called planktonic form of microorganisms, are a prerequisite for biofilm formation. Biofilms may thus become established on any organic or inorganic surface substrate where planktonic microorganisms prevail in a water-based solution. In dental contexts, a well-known and extensively studied biofilm structure is established during the attachment of bacteria to teeth to form dental plaque. Here, bacteria free in saliva (planktonic organisms) serve as the primary source of organisms for the organization of this specific biofilm

341. Advice about prevention.

A. Raw and white sugar are cariogenic.
B. Water is not effective.
C. Professional applications are the most effective method for prevention.

Answer: A.

Diet modification, although often given minimal attention by dental practitioners, diet is probably the single most important factor in caries risk (Cameron)

342. Which of the following "in office" preventive procedures is most practical and effective for an uncooperative 4 year old patient from noncompliant family?

A. Oral hygiene instruction.
B. Dietary counselling.
C. Fluoride varnish every six months.
D. Fluoride supplements.

E. Pit and fissure sealants on all primary molar.

Answer: E.

Ideally primary prevention is educating the patient/parent. C, D, E are secondary preventive measures. Since the question mentioned non-compliance family, it would be assumed that previous oral health care instructions have not been followed.

E, Pit and fissure sealant would be for the best interest of the child.

C, requires compliant parent to bring the child 6 monthly which cannot be guaranteed.

D, fluoride supplement is not recommended for "increased risk" patients.

343. What can see on occlusal radiograph?

1. Fracture of teeth.
2. Bone growth around teeth.
3. Bone expansion – maxilla and mandible.
4. The position and direction of impacted teeth.
   A. All of the above.
   B. 1,2,3

Answer: A.

Occlusal radiograph is used with other radiographic view that should be perpendicular to detect the correct position of either the fracture or impacted tooth.

344. A true occlusal radiograph is most useful in:

1. view of buccal and lingual bone formation.
2. salivary calculus in the submandibular duct and gland.
3. position of teeth in the arch.
4. fractures in anterior teeth.
5. bone deposition around the tooth.
   A. All of the above.
   B. 1,2,3,4.
   C. 1,2,3,5.
   D. 1,2,4,5.
   E. 2,3,4,5.

Answer: B or A.

B, There is no evidence of bone deposition around the teeth could be seen by occlusal radiograph (W&F,158-164).

A, depending on previous question 343.

345. Which is incorrect in regards to elevator?

A. It can be used to aid in splitting the roots of third molar.
B. It can be used when adjacent teeth is present.
C. The best point to use straight elevator (Warwick James) is at furcation of mandibular molar.
D. It is best used in last maxillary molar.

Answer: A.

We can use Warwick James elevator at buccal bifuraction of mandibular molars after raising a flap and if there is no natural notch in the root we can create one with a round bur then we can use this elevator.

346. A 25 years female in her third trimester of pregnany presents with an acute dental infection. Which of the following is contraindicated for this patient?

A. Prescription of clindamycin.
B. Presecription of penicillin V.
C. Extraction using 2% lidocaine with 1:100000 epinephrine.

D. Prescription of ibubrofen.

Answer: D.

NSAIDS could cause premature closure of the ductus arteriosus.

347. A 25 year old female in her first trimester of pregnancy presents with an acute dental infection. Which of the following is CONTRAINDICATED for this patient?

A. Prescription of a radiograph.
B. Prescription of penicillin V.
C. Extraction using 2% xylocaine with 1:100,000 epinephrine.
D. Acetylsalicylic acid for pain management.

Answer: D.

The answer is D because it is mentioned it is for pain management that is mean the dose is from 150 to 300 mg and this is contraindicated in pregnancy.

348. Most common drug for dental pain is:

A. over the counter NSAID.
B. over the counter paracetamol.
C. Prescribed only NSAID.
D. prescribed only paracetamol.

Answer: A.

If the question asks about what is the best drug for dental pain - prescribed NSAID, if the question asks about what is the most common drug for dental pain -answer is over the counter NSAID. But if the pain is very tense we combine paracetamol with ibuprofen (NSAID).

349. Which category of drugs does not affect blood clotting and can be given in patients on warferin therapy?

A. Salicylates.
B. NSAIDS (ibuprofen,naproxen,etc).
C. Aspirin.
D. COX-2 inhibitors (Rofecoxib,Eterocoxib,etc).

Answer: None of the above, all of them has antiplatelet effect.

350. Which is the most potent according to third molar model?

A. Aspirin.
B. Paracetamol.
C. Codiene.
D. Ibuprufen

Answer: D.

351. Max dose of Aspirin that can be taken in a day by healthy adult is:

A. 1800mg.
B. 1000mg.
C. 3600mg.
D. 2400 mg.
E. 2000 mg

Answer: C.

352. In a patient having acute herpetic gingivostomatitis, what will you do?

A. Give penicillin.
B. Treat palliatively.
C. Give corticosteroids.
D. Give antibiotic.

Answer: B.

353. What to do with instruments used for known Hepatitis B patient?

A. Soak them in hypochlorite solution "Milton".
B. Clean, scrub and sterilize.
C. Handle them with two pairs of household rubber gloves.
D. Scrub them with iodine surgical solution.
E. Sterilize for double cycle.

Answer: B.

354. Patient during dental treatment feels light headed, sweating and unconscious. What is diagnosis?

A. Shock.
B. Syncope.
C. Asthma.

Answer: B.

355. What is correct regarding oral melanoma?

A. Palate in the most uncommon oral site.
B. The incidence is same in both oral and cutaneous melanoma.
C. Prognosis is survival of less than 20 percent over 5 years.

Answer: C.

356. Ibuprofen is:

A. safe during 1st and 2nd trimester, not 3rd.
B. safe during 2nd and 3rd, not 1st.
C. safe during 3rd and 1st, not 2nd.
D. safe during all trimesters.

Answer: A.

357. Maximum dose of ibuprofen that can be taken in a day by healthy adult?

A. 1800mg.
B. 1000mg.
C. 2400mg.
D. 2000mg.

Answer: C.

For adults: The recommended daily dose of ibuprofen in adults is 1200 to 1800 mg per day in divided doses. Usually a dose of 600 to 1200 mg per day is sufficient and the total daily dose should not exceed 2400 mg. The highest possible dose should only be taken in cases of acute and severe pain and only until the acute phase has been brought under control. Once the acute pain has passed, the dose should be reduced to the usual recommended daily dose.

For children: In children, the daily recommended dose for ibuprofen is 20 mg per kg of body weight in divided doses. In children with severe pain caused by juvenile arthritis, for example, a dose of up to

40 mg per kg of body weight in divided doses may be allowed. For children weighing less than 30 kg the total dose per day should not exceed 500 mg per day.

For elderly patients: The elderly are at an increased risk of the adverse side effects associated with ibuprofen and doses should be administered with great caution in this age group, especially among those with impaired liver or kidney function.

358. *Which of the following medications increases a patient's risk for intraoral candidiasis?*

A. Warfarin (Coumadin®).
B. Cyclosporine.
C. Pentobarbital.
D. Ibuprofen.
E. Pilocarpine.

Answer: B.

Cyclosporine is immunosuppresivedrug.

359. Which of the following is incorrect/ with the action of NSAIDS?

A. It acts mainly peripherally.
B. It acts centrally & peripherally.
C. It acts mainly centrally.
D. It interacts with ACE inhibitors or captopril.
E. GIT symptoms are common.

Answer: C.

360. One week following extraction of teeth 1.8 and 4.8, an 18 year old male returns to the dental office complaining of persistent bleeding from the extraction reaction sites. The medical history was unremarkable, except for episodes of bruising and joint swelling as a child. Subsequent blood tests showed normal bleeding g time and a factor VIII level of 14%. The most likely cause would be:

A. dry socket.
B. ibuprofen intake.
C. Hemophilia A.
D. cirrhosis.
E. Vitamin K deficiency.

Answer: C.

361. Most commonly used OTC analgesic in Australia is:

A. Panadol.
B. NSAID.
C. Codiene and paracetamol.
D. Aspirin.

Answer: B.

362. Which is not true?

A. An impacted third molar should always be extracted.
B. An impacted third molar should be extracted in teenagers and young adult.
C. An impacted third molar with repeated pericoronotits should be extracted or there is imbication of anterior teeth.

Answer: A.

363. Trismus is caused by which of the following during administered of inferior alveolar nerve block (IANB)?

A. Injection into medial pterygoid muscle.
B. Injection into facial nerve.
C. Injection into masseter.

Answer: A.

364. If an odontogenic infection involves the pterygomandibular space, the most obvious clinical sign will be:

A. trismus.
B. facial swelling.
C. swelling in the submandibular area.
D. rise in body temperature above 39°C (102ºF).

Answer: A.

365. Which nerve damage causes dilated pupilla?

A. Occulomotor nerve.
B. Vagus.

Answer: A.

366. Constricted pupil due to damage which nerve?

A. Abducens.
B. Oculomotor.
C. Cervical sympathetic.
D. Vagus.

Answer: C.

Sympathetic innervation leads to pupillary dilation. So if there is damage to sympathetic innervation, it cannot dilate leading to constriction.

Occulomotor nerve palsy: mydriasis (dialation). Damage to sympathetic chain: miosis (constriction) as it cannot counter act the constrictive effect of parasympathetic stimulation.

367. Most common cause of pale x-ray film is:

A. Under fixation.
B. Underdeveloping.
C. Old expired film.
D. Light leak.
E. None of the above.

Answer: B.

368. Old solution – unsafe dark room – radiograph will appear:

A. Blurred.
B. Fogged.
C. Dark.
D. Light.

Answer: B.

X-RAY FACILITY TIPS

Topic 1: Darkroom Fog

The effect of fog on an x-ray film is usually subtle, but it can degrade the image quality (detail and contrast) to such an extent that the examination may potentially cause a mis-diagnosis and/or must be repeated. Fogging may be due to many factors including:

* Using film kept past its expiration date. Unexposed film may become fogged by gradual chemical deterioration, which is temperature dependent and therefore may be slowed by storing film in a refrigerator.
* Film exposed to stray radiation during storage.
* Film exposed to excessive heat or humidity during storage.
* Film exposed to certain chemicals during storage.
* Light leaks from the film packet.
* Indicator lights that are not red on processors, other electronic equipment, luminous dials on clocks, film processor controls, glow in the dark stickers, clock radios, glow in the dark flashlights, etc.
* Light leaks into the darkroom. The smallest light leak can fog film and haze images. Most often, you'll find leaks around dark room doors, through false ceilings of perforated tile, around light fixtures, fans, doors not all of one piece, plumbing fixtures going through a wall, and corners where two walls meet.
* Poor darkroom lighting conditions. Safelight filters and housing with holes and cracks and improper choice of filters with the film being used.

369. Exposure of radiograph to stray radiation or accidental exposure outside dark room lead to:

A. dark film.
B. light film.
C. fogged film, striated film.

Answer: C.

370. Which of the following is true regarding hepatitis B infection?

A. All types of hepatitis B antigens have similar infectivity.
B. HBe antigen is having higher transmission rates than HBs.
C. HBs antigen has higher transmission rate than HBe.
D. Risk is highest in HBc positive individuals.

Answer: B. (Odell, 148)

- The mean time from exposure to detection of HBsAg is 30 days.
- The persistence of HBsAg for >6 months defines carrier status. This follows 5-10% of infections:
  - Among those who are HBsAg-positive, those in whom HBeAg is also detected in the serum, are the most infectious.
  - Those who are HBsAg-positive and HBeAg-negative (usually anti-HBe-positive) are infectious but generally of lower infectivity.

- The presence of HBeAg implies high infectivity. HBeAg is usually present for 1½-3 months after the acute illness.
- Antibodies to hepatitis B core antigen (HBcAg) - ie anti-HBc - imply past infection.
- Antibodies to HBsAg - ie anti-HBs - alone imply vaccination.
- Dane particles are HBV virions. Anti-Dane particles are antibodies formed against them.
- DNAP is DNA polymerase, which is present during viral replication.
- HBV/HDV infection has a different natural history and different treatment to HBV mono-infection.
- Patients with acute infection have raised levels of IgM to HBcAg (anti-HBc).
- Patients with chronic hepatitis B are positive HBsAg for at least six months or positive HBsAg and negative IgM to HBcAg.

371. What's untrue about root sectioning?

A. facilitates extraction procedure.
B. preserves the bone.
C. tooth should be removed intact.

Answer: C.

372. Occlusal acrylic splints are used for diagnosis and treatment of craniomandibular dysfunctions because it:

A. corrects malocclusions.
B. protects loss of teeth surface.
C. helps in muscle relaxation.
D. posterior positioning of the mandible.

Answer: C.

373. All of the below are features of TMJ dysfunction, except:

A. Pain.
B. Crepitus.
C. myofacial pain.
D. jaw deviation.
E. facial paralysis.

Answer: E.

374. What is the incorrect about MPD (Myofascial Pain Disorder)?

A. Dull and throbbing pain.
B. Follows muscles.
C. Unique to jaws.
D. Feeling of 'pressure'.

Answer: C.

MPD is not unique to jaws, TMD is unique to the jaw and it is a different pathology from MPD.

375. Which of the following is NOT a sign or symptom of the myofascial pain dysfunction syndrome?

A. Pain.
B. Muscle tenderness.
C. Limitation of jaw motion.
D. "Clicking" or "popping" noise in the joints.
E. Radiographic changes of the joint.

Answer: E.

376. Stage 3 internal derangement what is NOT true?

A. The patient cannot open mouth.
B. Noisy TMJ.
C. Painful.
D. It may resolve spontaneously.

Answer: D. (Appendix IV)

377. A 45 year old patient attends the dental clinic complaining of a clicking jaw. Examination reveals a reproducible click of the right TMJ when opening wide. Upon asking the patient to open wide, close with incisors edge-to-edge and then open and close to this position, the click is absent. From the options below, which one is the most likely diagnosis?

A. Myofascial pain.
B. Disc displacement with reduction.
C. Disc displacement without reduction.
D. TMJ osteoarthritis.
E. Arthralgia.

Answer: B.

Disk displacement without reduction occurs when the ligaments are stretched more and the disk slips too far out of position so that it can no longer “click” back into place. It then acts like a door-jam and blocks the normal movement of the joint. As the mouth opening is limited it is also called “locked jaw” even though typically a person can still open to two-finger widths. It usually causes no sound, but maximum opening between the tips of the upper and lower incisors is reduced from the normal 45 to 50 mm to ≤ 30 mm. Pain and a change in the patient's perception of their bite generally result. It usually manifests acutely in a patient with a chronically clicking joint; about 8 to 9% of the time, the patient wakes up unable to open the jaw fully.

Disk derangement with reduction often causes a clicking or popping sound when the mouth is opened. Pain may be present, particularly when chewing hard foods. Patients are often embarrassed because they think others can hear noise when they chew. Indeed, although the sound seems louder to the patient, others can sometimes hear it.

378. Patient with TMJ pain, limited mandibular movement and pain morning for 30 minutes which works and progress during day, limited joint space RG formation of Osteo.....pain divert head, clinically pain in the auricular area:

A. Osteoarthritis.
B. Myofascial syndrome.
C. Rheumatoid arthritis.

D. TMD.

Answer: D.

The patient with stress-related MPDS usually complains of constant, dull pain that may or may not be exacerbated by mastication or mandibular movement and relieved by jaw rest. Quite often, this pain is worse in the morning, if related to nighttime parafunctional clenching or bruxism. The patient with intraarticular TMJ pain due to arthritis has the pain relieved by jaw rest and may be pain free except when moving the mandible or masticating solid food. Unfortunately, intraarticular TMJ disease often involves the masticatory muscles secondarily so that both types of pain (intra- and extraarticular) are experienced simultaneously by the patient.

379. An old patient has pain under his full upper and lower dentures. The pain increases when he wears them during the day and stops immediately after removing the dentures. His doctor thinks it is due to mental nerve compression by lower denture and refers to you for the second opinion.

I. What investigations will you perform other than checking denture borders?
   A. occlusal prematurities.
   B. soft tissues under denture.
   C. assess vertical dimension.
   D. retention of the denture.
   E. palpation of muscles.

Answer: C.

II. What is the likely cause of pain?
   A. Increased vertical dimension.
   B. Overextension of borders of the denture.

Answer: A.

III. What is the clinical symptoms of mental nerve compression by the denture borders?
   A. Lower lip numbness.
   B. Pain.

Answer: A

IV. Tests to investigate nerve sensation. What is INCORRECT?
   A. two-point discrimination.
   B. sharp test.
   C. Blunt test.
   D. pressure test.
   E. thermal test.

Answer: D.

380. What is TRUE in regard to the preparation of occlusal rests:

A. Use an inverted cone bur.

B. Use a flat fissure bur.
C. Parallel to occlusal plane.
D. At right angle to the long axis of tooth.

Answer: None of the above.

381. What is true regarding to the preparation of occlusal rests in lingually tilted tooth?

A. Use inverted cone bur.
B. Use straight fissure bur.
C. Prepare parallel to occlusal plain.
D. At right angle to the long axis of tooth.

Answer: None of the above

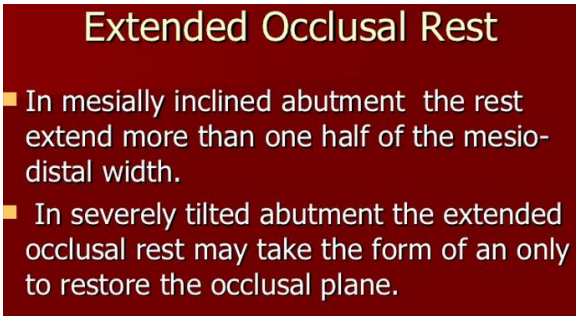

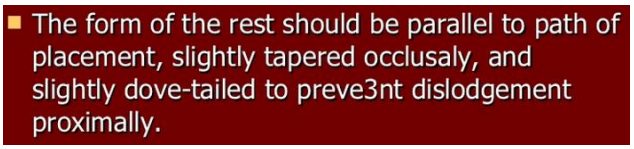

382. The auxiliary occlusal rest on teeth for partial denture should be placed:

A. Away from edentulous space.
B. Adjacent to edentulous space.
C. Near fulcrum line.
D. Away from fulcrum line.

Answer: D.

383. What is TRUE?

A. Boiling point of acrylic acid > boiling point of water.
B. Boiling point of acrylic acid is similar to that of water.
C. Boiling point of acrylic acid < boiling point of water.

Answer: A.

384. How will cover lower premolar when making a metallic porcelain crown?

A. cover the occlusal and buccal surfaces by porcelain.
B. cover just buccal surface by porcelain.

Answer: A.
According to Shillingberg , It is standard to cover both buccal and occlusal surface with porcelain in mandibular first premolar (second premolar and molars optionally)

385. For a porcelain fused to metal restoration, the metal surface:

A. requires some degree of mechanical retention.
B. should not be heat treated.
C. requires a well polished surface.
D. must develop an oxide for chemical bonding.

Answer: D.

386. Tripod marking in surveyor is used to:

A. Remount the cast on d articulator.
B. Re orient the cast on surveyor.
C.
D.

Answer: B.

387. Maximum support in distal extension RPD gained through:

A. indirect retainers.
B. Proper tissue support by denture base.

C. occlusal rests.
D. Clasps.
E. use stress breakers

Answer: B.

388. Patient had new resin-bonded bridge, it fell off 3 months after cementation but occlusion and design are not a problem. What is the correct management for this problem?

A. Just do pumice enamel and re etch metal and cement.
B. Slightly reduce lingual enamel and retch and bond metal.
C. Remake metal create resin tags.
D. Remake the bridge.

Answer: A.

389. In the exam there was a question about the advantage of "Kroll" RPI Clasp:

A. best esthetics.
B. minimal tissue contact.
C. better retention.
D. minimizes the need for indirect retention.

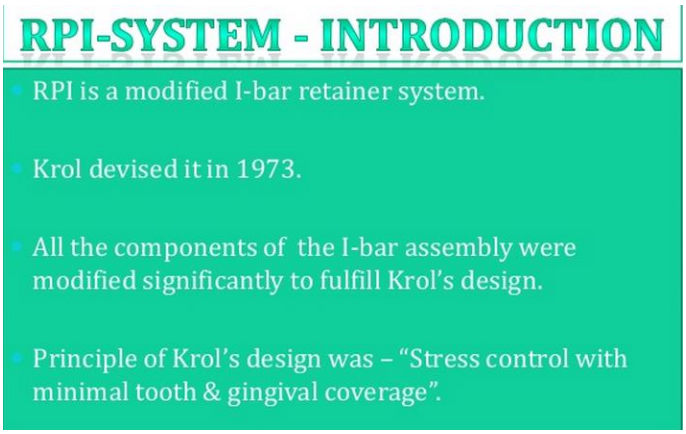

Answer: B (Power Point Presentation in ADC selected)

There are a couple of specific theories which include the clasp design:

- **RPI**: mesial rest, distolingual guide plate, I-bar
  - The RPI design was made for clasping a bilateral free end extension. These clasps are unique because they have to take into account extra torque force due to being tissue borne (and not tooth borne) at the posterior.
  - Described by Kratochvil in 1963 and modified by Krol in 1973
    - Kratochvil designed the abutment tooth with a long rest (from the mesial marginal ridge to the distal pit), long guide plane, and a regular I-bar clasp.
    - Krol modified this design with a short occlusal rest, short guide plane (touching only from occlusal to middle third), and a mesial-shifted I-bar. The theory behind Krol's decision was to allow for movement of the partial denture without placing too much torque on the abutment tooth.
- **RPA**: mesial rest, distolingual guide plate, Akers' clasp-style retentive arm
- **RPC**: mesial rest, distolingual guide plate, other type of cast circumferential clasp
  - So named in response to the **RPI Philosophy** introduced by Kratochvil and Kroll.

390. Advantages of RPI system:

A. best esthetics.
B. minimal tissue contact.
C. better retention.
D. minimizes the need for indirect retention.

Answer: A.

Advantages of RPI:

- Better aesthetic for the minimal tissue contact.

- it exerts least forces on the abutment as on chewing, the I-bar arm & the proximal plate opens then closes after the force is removed

391. Implant not favorable in the 14 15 region for a 45 year old patient because of:

A. Maxillary sinus expansion.
B. Poor bone quality.
C. Inadequate space for two adjacent implants.
D. Need bone augmentation.

Answer: A.

392. Post crown fracture. Patient has been treated with post crown 5 years back on maxillary right central incisor. Now it has become loose.

I. What investigation will help?
A. Vitality.
B. Probing.
C. Percussion.
D. OPG.

Answer: B.

A periapical radiograph can detect a fracture line only in 35.7% cases. The reasons for this may be,

- Superimpositions of root canals on fracture line
- X-ray beam not parallel to the plane of fracture
- Fracture line present in the fused root superimposed by radiopaque anatomic structures
- Location of fracture line precludes the use radiograph.

II. What could be the cause that has least favorable prognosis?
A. Vertical root fracture.
B. Internal resorption.

Answer: A.

III. If this tooth is extracted, what is best method of restoration which is long lasting?
A. Implant.
B. Fixed bridge.
C. Cantilever bridge.

Answer: A.

393. Concerning maxillary and mandibular posterior implants,

A. 95% survival rate for mandibular implants and a 65 – 85% survival rate for maxillary implants were reported.
B. Bone quality and favorable loading are important factors for success of implant - supported restorations.
   A. Minimum thickness of 1 mm of surrounding bone is required for optimal osseointegration.
   B. Stress to the implant is primarily affected by implant position.
   C. All of the above.

Answer: E.

394. Muscles required to close the mouth till centric occlusion:

I. lateral pterygoid.
II. medial pterygoid.
III. Masseter.
IV. Temporalis.

A. 1 2 3.
B. 2 3 4.
C. 3 & 4.
D. All of the above.

Answer: B.

395. Circumferential clasp, what is incorrect?

A. Rigid 2/3 above survey line & flexible 1/3 below.
B. Flexible 2/3 above survey line & rigid 1/3 below.
C. Should always engage deepest undercut.
D. Cross section is circle.
E. Should engage a predetermined undercut.

Answer: A.

396. What is Ante's Law about?

A. The relation between the span of the bridge and the pontics.
B. The periodontal area of the abutment teeth.
C. The relation between the length of the root and the abutment.

Answer: B.

397. In cementing Maryland or Roche bridges, the effect is generally to:

A. Lighten the colour of the teeth by the opacity of the cement.
B. Darken the colour of the abutment by the presence of metal on the lingual.
C. Have no detrimental colour effect.
D. Darken the abutment teeth by incisal metal coverage

Answer: C.

If we plan to do Maryland Bridge we have to take in consideration all aspects affecting its success. And as the principal reason to make it is aesthetic so if any point affecting this we have to shift to the conventional bridge. Even the cement used for luting is resin based cement that does not affect on the color of adjacent teeth at all

398. Crown fits on the die, but on the tooth there is a discrepancy of about 0.3mm, what will you do?

A. Relieve cast from the inside.
B. Take a new impression and make new crown.
C. Burnish margins.
D. Use thick mix of cement.
E. Grind the interior of the crown.
F. Prepare the tooth further.

Answer: B.

Appendix I

MARGIN PLACEMENT AND BIOLOGIC WIDTH

A clinician is presented with three options for margin placement: 1. Supragingival, 2. Equigingival, and 3. Subgingival locations.

Supragingival margin

It has the least impact on the periodontium. This margin location has been applied in non-esthetic areas due to the marked contrast in color and opacity of traditional restorative materials against the tooth. With the advent of more translucent restorative materials, adhesive dentistry, and resin cements, the ability to place supragingival margins in esthetic areas is now a reality.

Advantages

1. Preparation of the tooth and finishing of the margin is easiest 2.Duplication of the margins with impressions that can be removed past the finish line without tearing or deformation is the easiest with supragingival margins. 3. Fit and finish of the restoration and removal of excess material is easiest 4. Verification of the marginal integrity of the restoration is easiest. 5. The supragingival margins are least irritating to the periodontal tissue.

Equigingival margin

The use of equigingival margins traditionally was not desirable because they were thought to favour more plaque accumulation than supragingival or subgingival margins, and therefore result in greater gingival inflammation. There was also the concern that any minor gingival recession would create an unsightly margin display. These concerns are not valid today, not only because the restoration margins can be esthetically blended with the tooth but also because restorations can be finished easily to provide a smooth, polished interface at the gingival margin. From a periodontal viewpoint, both supragingival and equigingival margins are well tolerated.

Subgingival margin

Restorative considerations will frequently dictate the placement of restoration margins beneath the gingival tissue crest because of caries or tooth deficiencies, and/or to mask the tooth/restoration interface. Invasion of biologic periodontal space for additional retention will cause iatrogenic periodontal disease with a premature loss of restoration. Restorative margin placement within the biologic width is detrimental to periodontal health and acts as a plaque retentive factor. When the restoration margin is placed too far below the gingival tissue crest, it will impinge on the gingival attachment apparatus and a constant inflammation is created and made worse by the patient's inability to clean this area. Body attempts to recreate room between the alveolar bone and the margin to allow space for tissue reattachment. This is more likely to occur in areas where the alveolar bone surrounding the tooth is very thin in width. Highly scalloped, thin gingiva is more prone to recession than a flat periodontium with thick fibrous tissue. The more common finding with deep margin placement is that bone level appears to remain unchanged; however, gingival inflammation develops and persists on the tooth restored. Investigators have correlated that sub gingival restorations demonstrated more quantitative and qualitative changes in the micro flora, increased plaque index, gingival index, recession, pocket depth and gingival fluid.

Appendix II

Horizontal root fractures occur primarily in the anterior portion of the mouth, especially in the maxilla; they are often caused by physical trauma to the face such as in car accidents or contact sports. The diagnosis of root fractures is determined by clinical and radiographic examination. It has long been accepted that the treatment for horizontal root fractured teeth involves repositioning and rigid splinting. Repositioning is thought to aid in pulp revascularization in the coronal aspect of the pulp; however, the effect of splinting in healing has been poorly explained experimentally. Other factors such as the space between the root fragments and the vitality of the periodontal ligament and pulp can also affect the treatment of a fracture, as well as the type of healing. Additional dental treatment of root fractures may also include endodontic therapy and restorative treatment if necessary.

The common types of healing include: healing with interposition of hard tissue, healing with interposition of bone and soft tissue between the fragments, healing with interposition of soft tissue, or no healing.

Evidence indicates that horizontal root fractures have a high rate of spontaneous healing. A patient's injury factors such as stage of root development, pulp sensibility, optimal repositioning and minimal dislocation, diastasis, mobility and periodontal injury are indicative of the prognosis for spontaneous healing. The efficacy of splinting remains to be seen. If spontaneous healing does not occur and symptoms worsen, healing may be improved by endodontic treatment.

Appendix III

Description for the answers:

I. In five year old, 1/3 have suffered a traumatic dental injury involving primary tooth, most often tooth luxation. Peak incidence of dental trauma in primary teeth is 2-3 years of age when motor coronation is developing and the child start moving. In 12 year old, 20-30% have suffered dental injuries and most typical is uncomplicated crown fracture. In permanent dentition peak incidence is 9-10 years where vigorous playing and sports activities become frequent. The most common injuries in permanent dentition are due to falls, followed by traffic injuries, act of violence and sports.

II. In lateral luxation, tooth appears displaced, with the apical or lateral part of the socket empty (if it was extrusion tooth should have been beyond the occlusal level of the adjacent tooth with apical part of socket empty. If it had it been intrusion, tooth appears dislocated in apical direction (infraocclusion) with partial disappearance of the space especially cervically with no empty space in lateral or apical region.

III&IV. Teeth with open apex (in my question 8 years of age in mcq 4) pulp canal obliteration is a relative frequent finding (~70%) while pulp necrosis is rare (~10%) and pulp survival is ~20%. In closed apex (as shown in radiograph and also expected for a 14 year old for centrals), likelihood of revascularization is minimal (~80% pulp necrosis) canal obliteration is minimal (~9%) and survival of pulp is ~11%.

V&VI. Irrespective of apex being open or closed, expected outcome of normal pdl is max ~80%. in open apex and 62% with closed apex. Surface resoption occurs in almost 34% cases for closed apex and 7 % for open, with minimal chances of inflammatory and replacement resorption. Surface resorption is very frequent and is usually located apically.

VII. Splinting: for lateral luxation, min 3-4 week non rigid, if no sign of marginal or periradicular breakdown, it can be removed otherwise should be maintained for another 3-4 weeks. For extrusive, non-rigid for 2-3 weeks and if no sign of hard tissue change remove it. For avulsion, semi-rigid splint for 1 week.

For intrusion, no splint, if ortho-extrusion is opted, it should be done within 3 weeks after injury.

VIII. Transient marginal breakdown: where there has been extensive damage to the bony parts of the socket, resorption of injured socket wall must take place prior to healing. This event occurs after

lateral luxation and intrusion; and can be seen radiographically seen as resorption of the lamina dura and clinically as granulation tissue in the gingival area. After 1 month, this process will resolve with later reformation of the socket bone.

Appendix IV

The most common TMJ arthropathy is the internal derangement, which is characterized by a progressive anterior disc displacement. It is often associated with a capsulitis, making pain a common feature. On physical exam, a popping is felt and heard, with associated pain. The most common derangement is anteromedial, and the degree of derangement generally correlates with symptoms. Myofascial pain is associated with pain over the temporomandibular joint without a palpable or audible click.

Types of internal derangement:

Type IA derangement is found with a popping over the joint without associated pain. It is seen in over 50% of normal subjects.

Type IB derangement is popping of the joint associated with pain. The popping is due to the noise the condyle makes as it moves under the anteriorly displaced disc. The pain is due to the stretching and subsequent inflammation of the retrodisc pad.

Type II derangement is similar to a type IB derangement, but a history of lock jaw can be elicited.

Type III derangement is a persistent lock, usually closed. Hence, there is usually no associated click or pop on physical exam.

Treatment:

Early treatment of the internal derangement is imperative, as progression of disease leads to a less favorable prognosis. Therapy for type I and II derangements is similar to that for myofascial disorders. NSAIDs and muscle relaxers (valium) are prescribed as is the instruction of a soft diet and jaw rest. Failure of these methods requires the addition of a splint to attempt the repositioning of the condyle. The purpose is to reposition the condyle into a more favorable position related to the disc. Clicking is usually not eliminated, but it may be reduced to a soft pop with reduced pain. For type III, arthroscopic surgery is perfomed.

Type of jaw lock:

There are two types of lock jaw. The closed lock is due to the inability of the condyle to slide under the anteriorly displaced disc. The open lock is due to the inability of the condyle to slide back over the disc into its normal position.